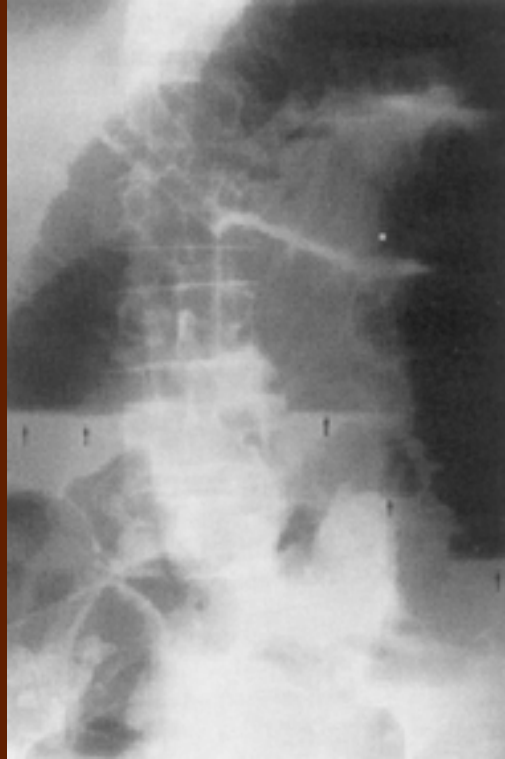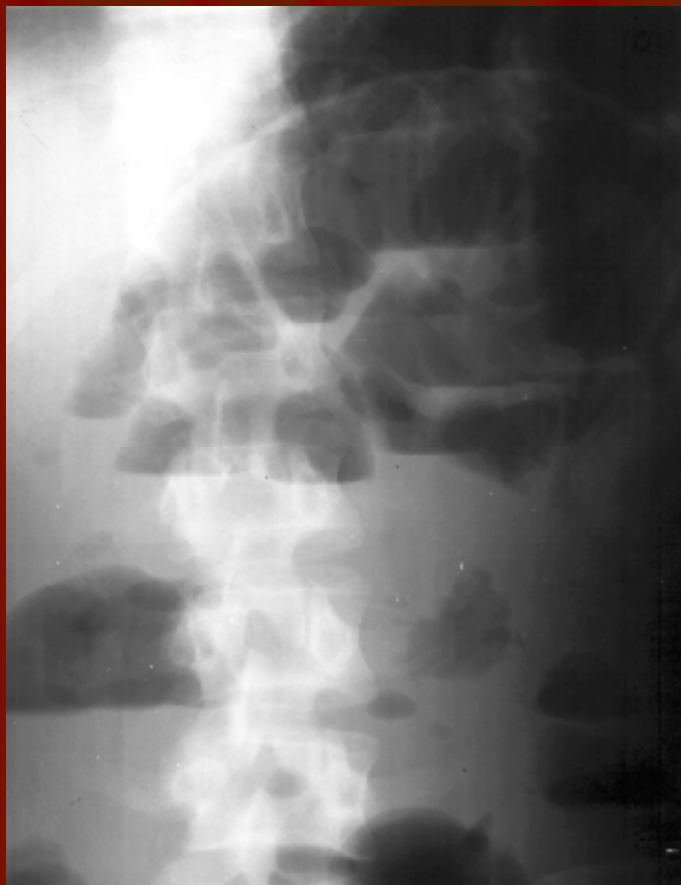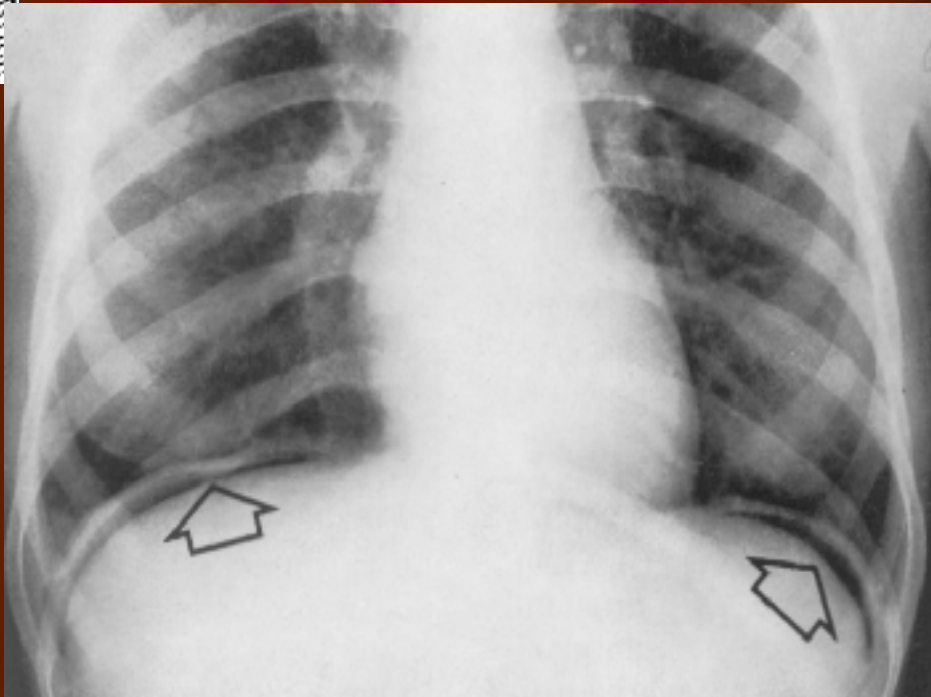


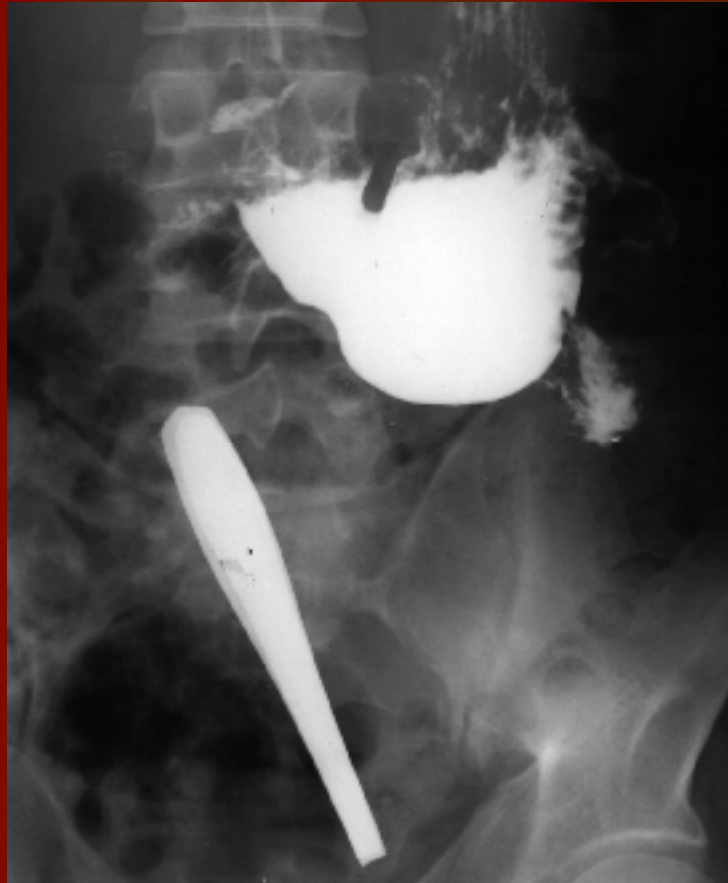Nivele hidro-aerice în tuburi de orga-ocluzie intestin subțire



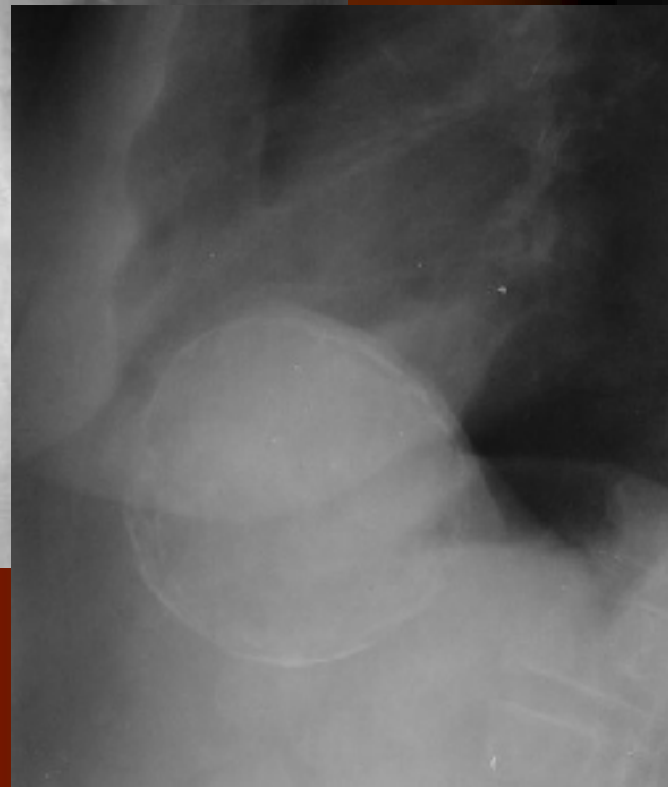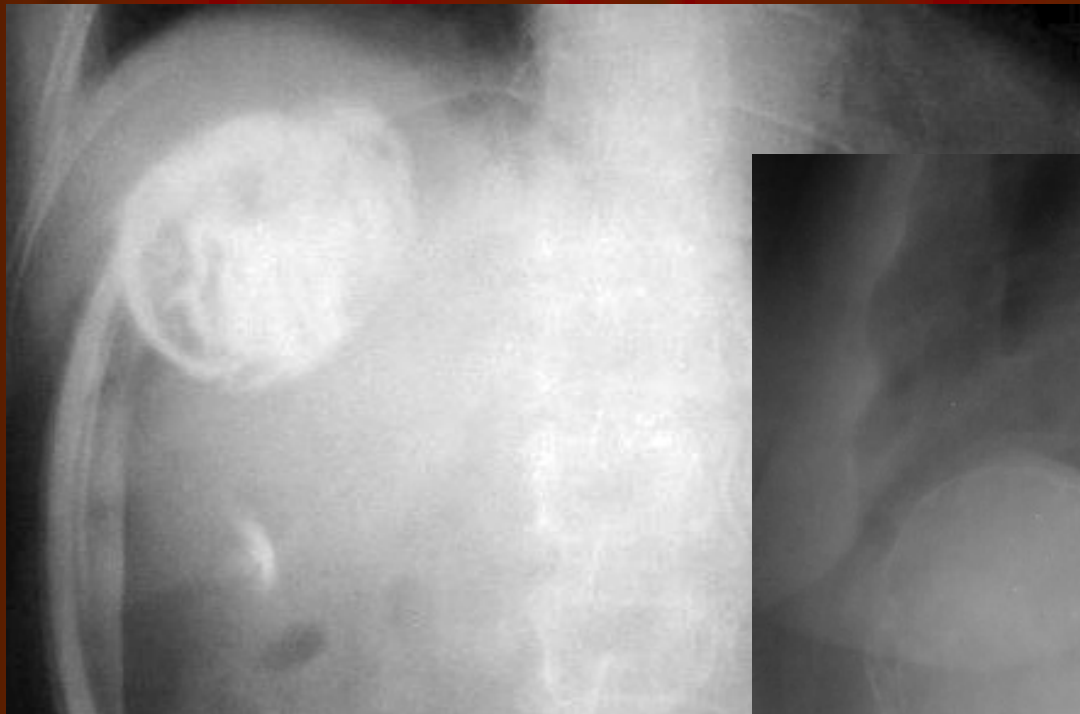
Nivele hidro aerice în cuib de rândunica – ocluzie colon



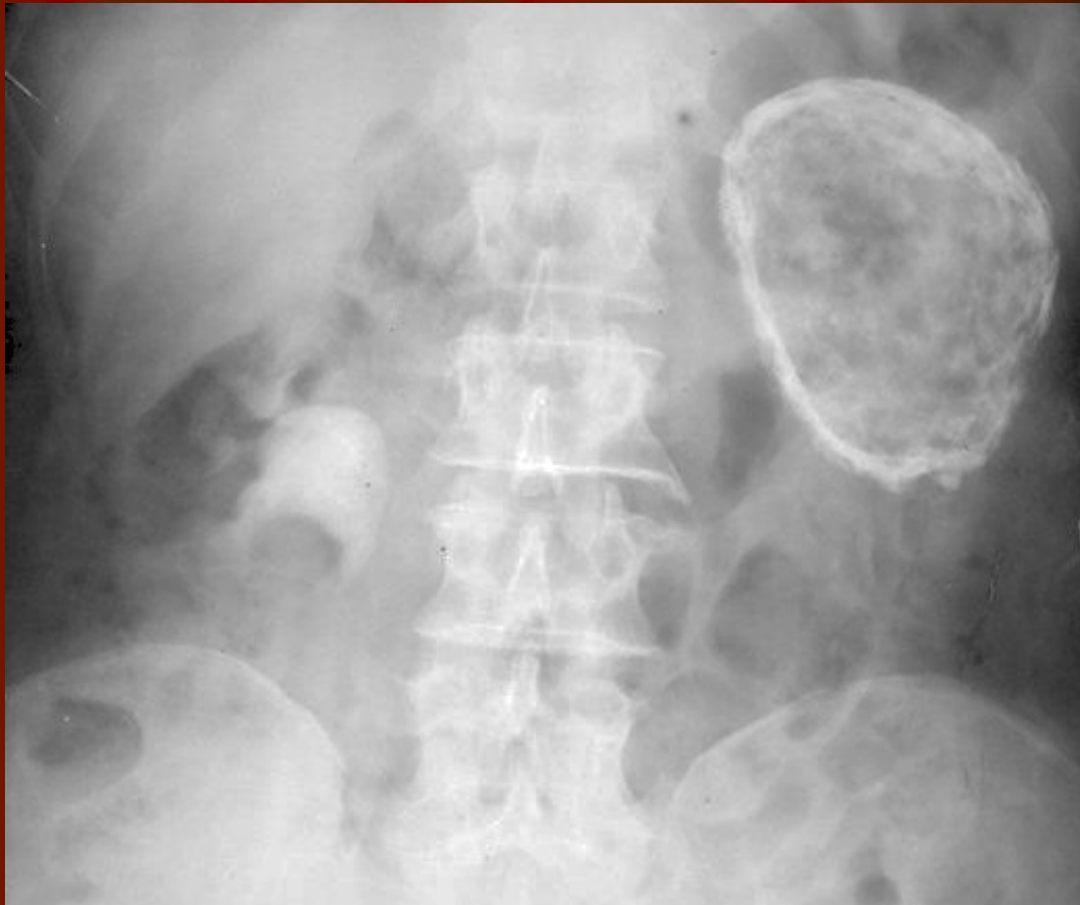Pneumoperitoneu



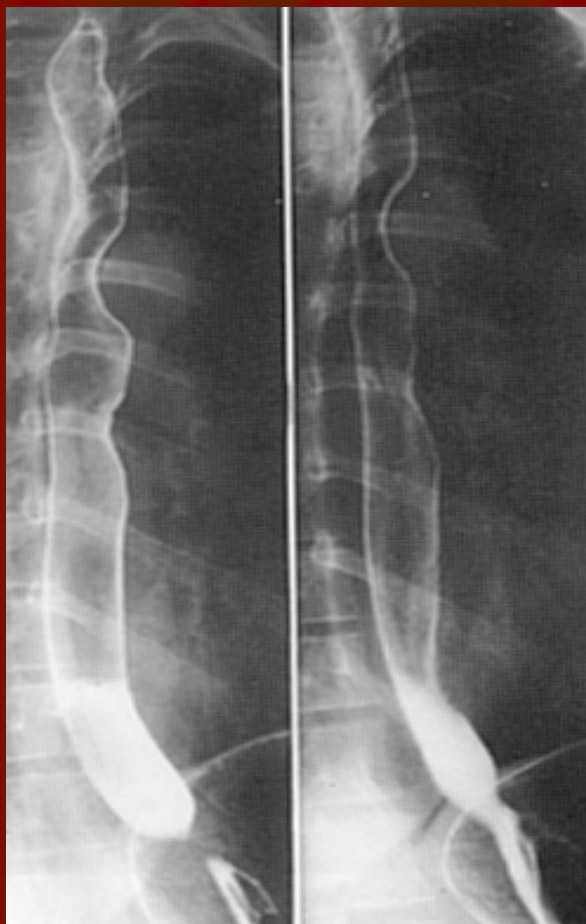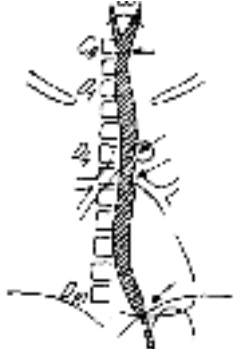
Corp străin metalic intraabdominal



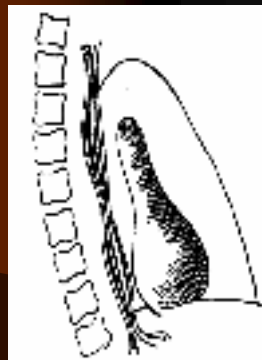
Chist hidatic calcificat in aria de proiectie a ficatului

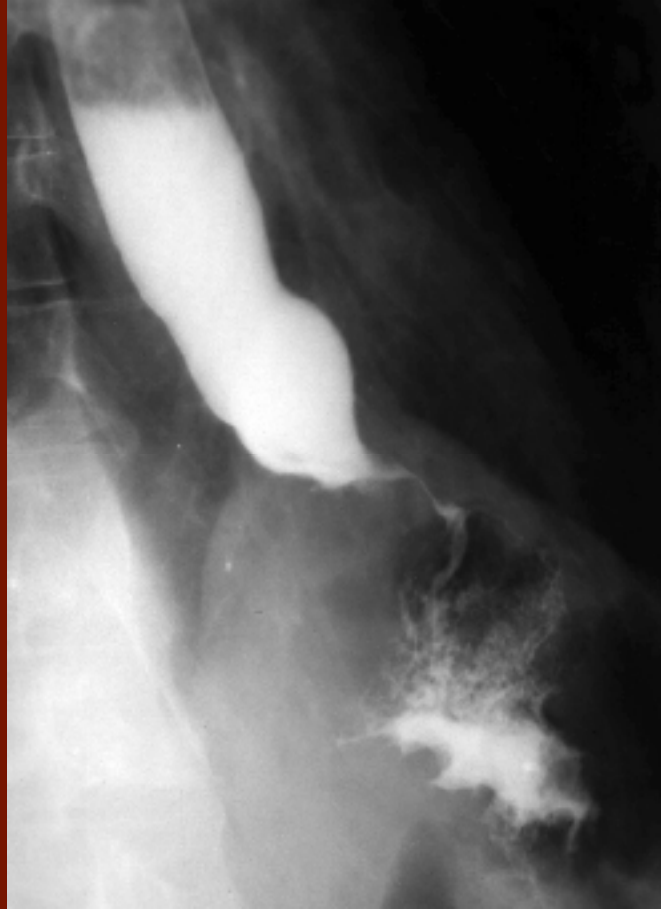


Chist hidatic calcificat in aria de proiectie a splinei

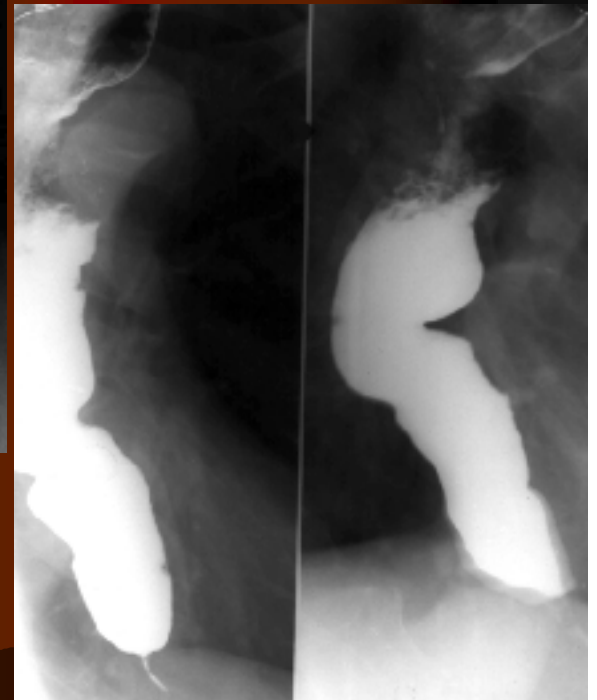
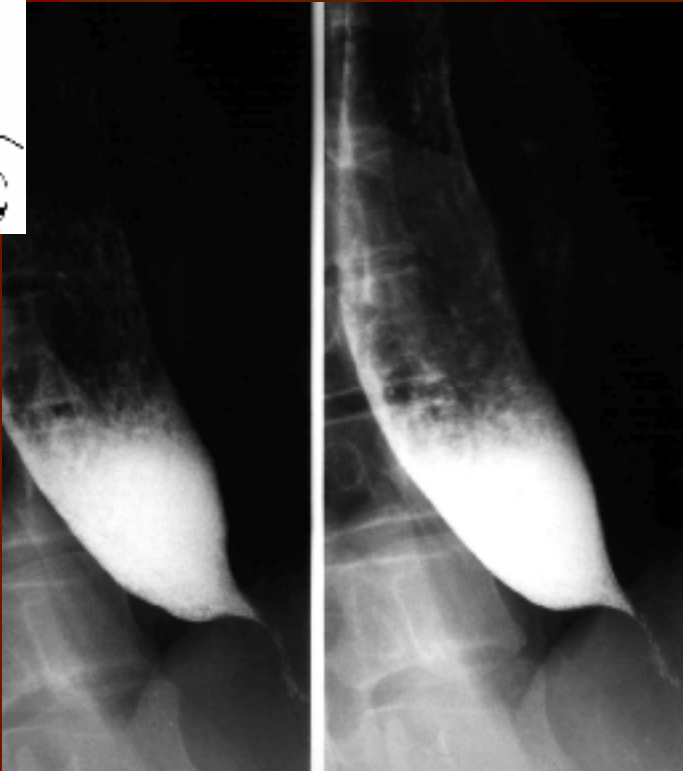
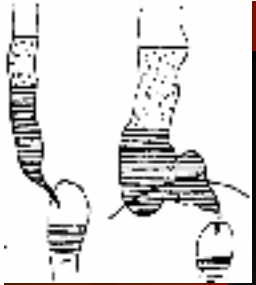


Examenul baritat esofagian normal

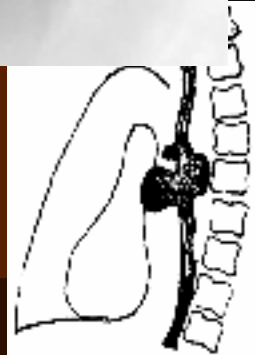
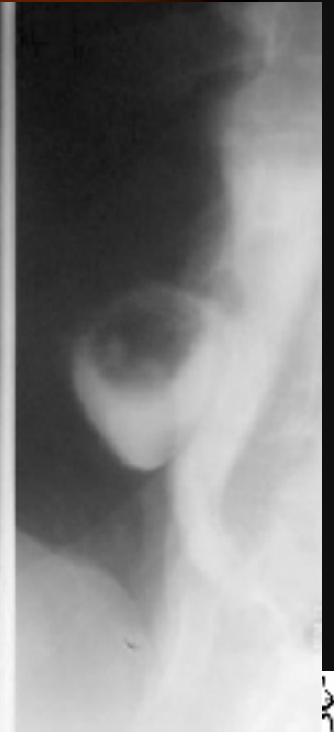
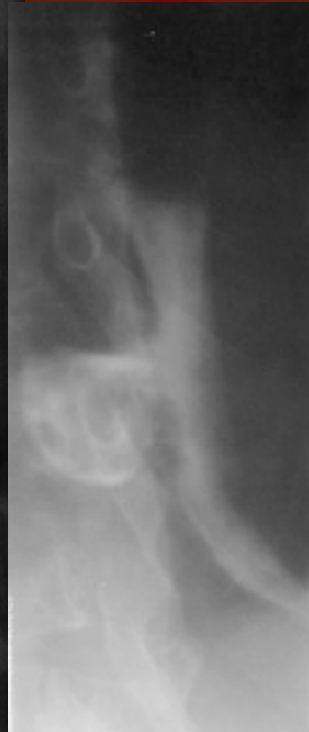
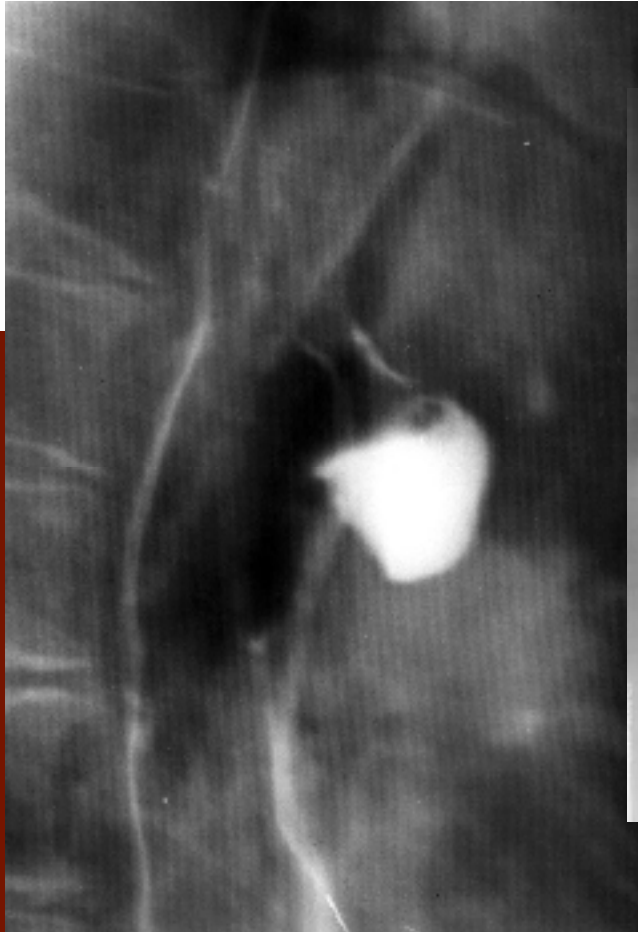
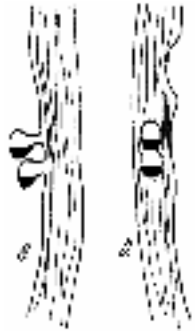
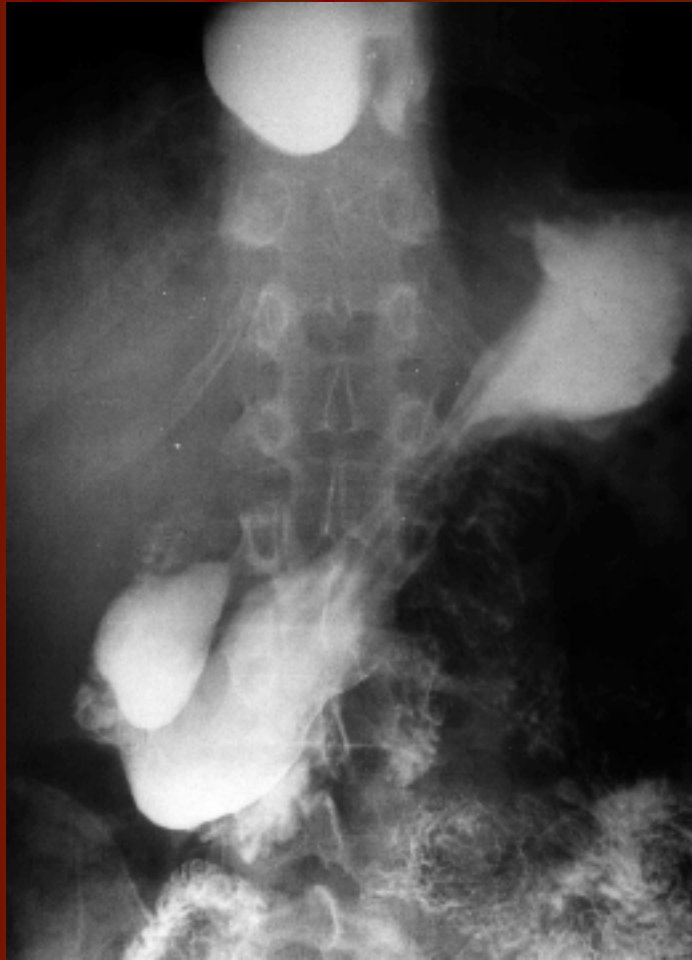Cardiospasmul



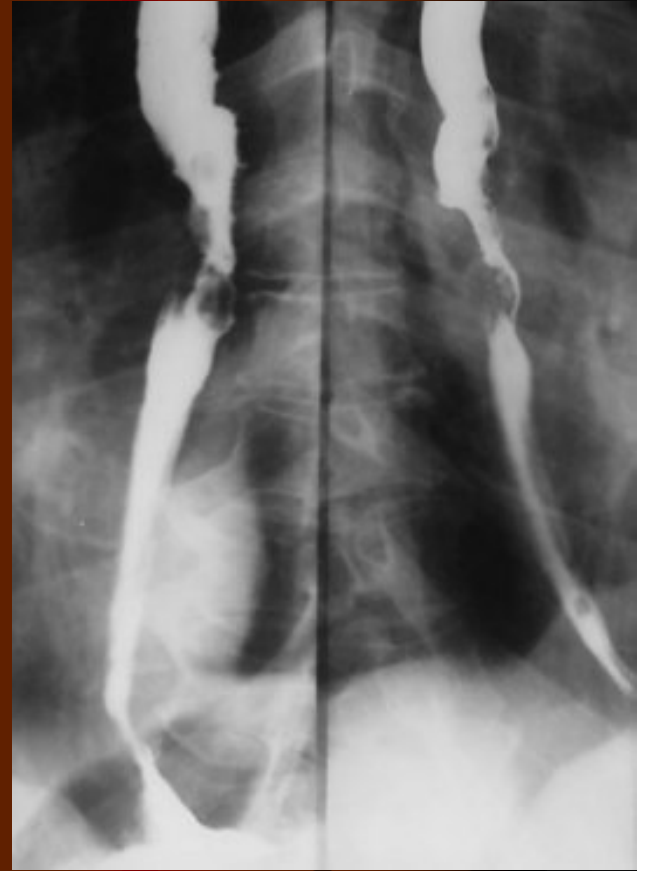
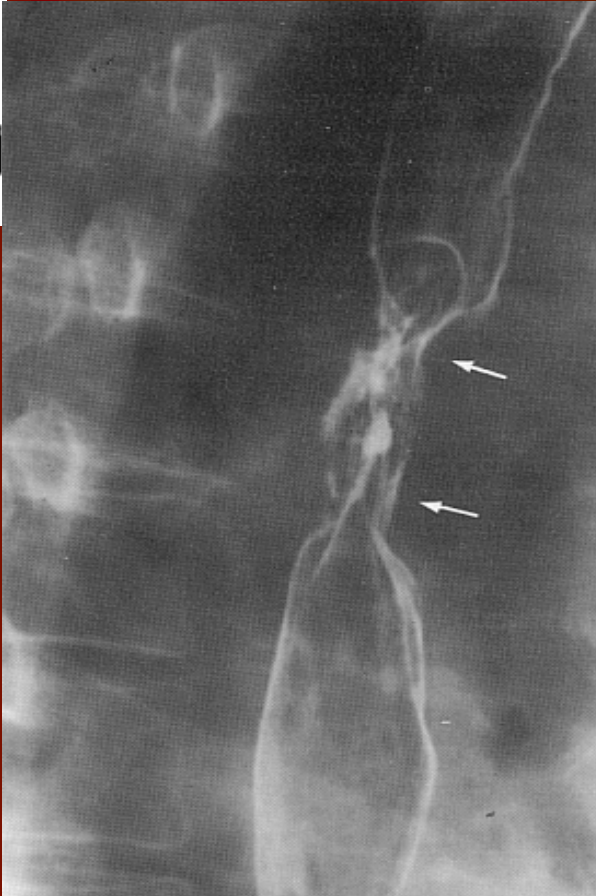
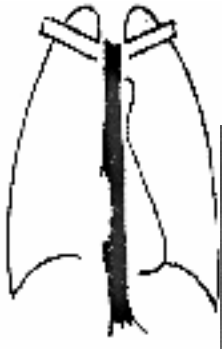
Achalazie



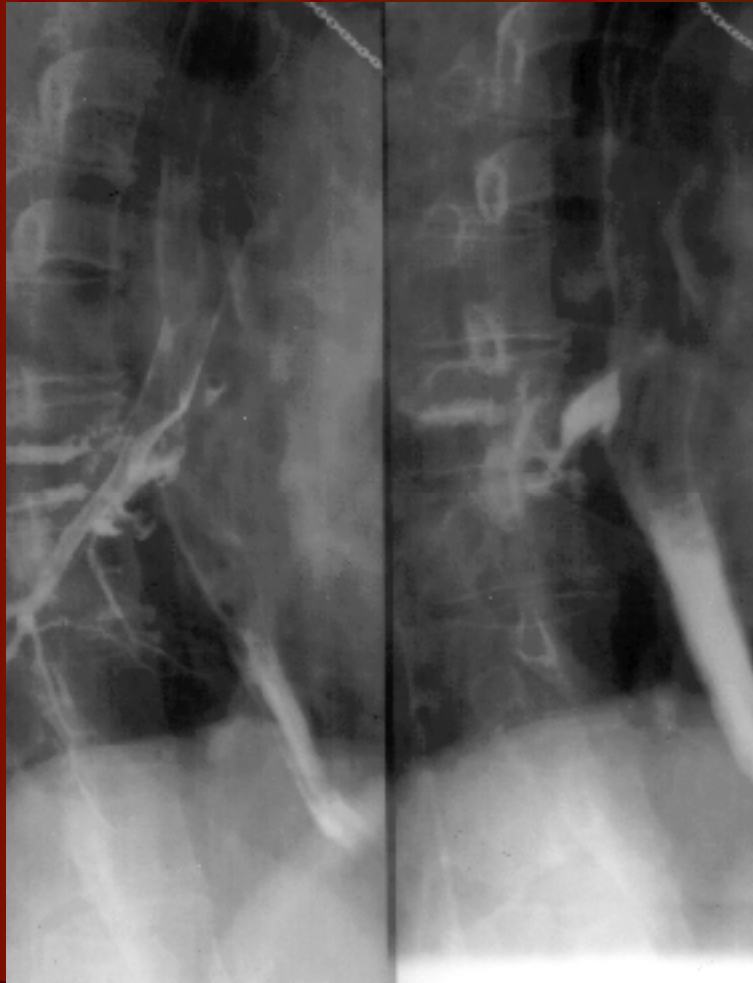Diverticoli esofagieni



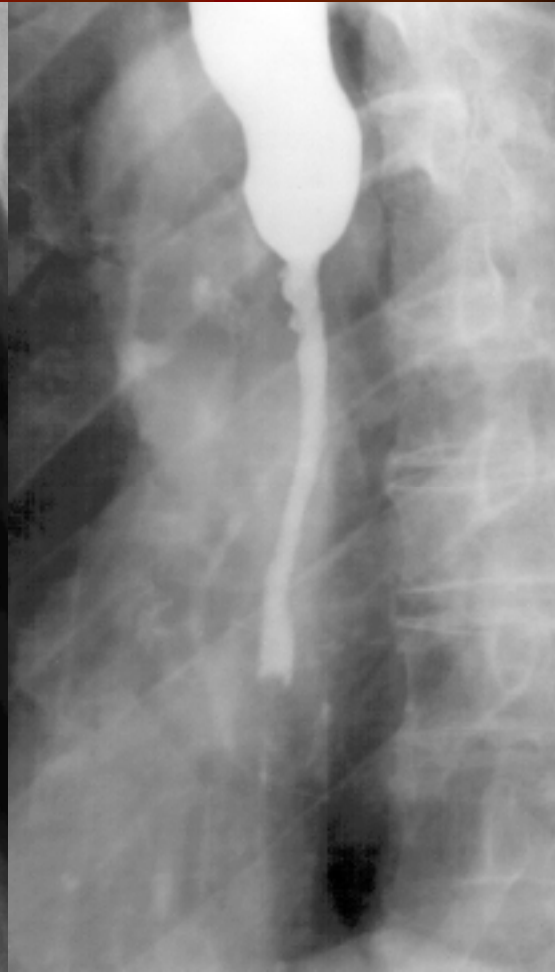
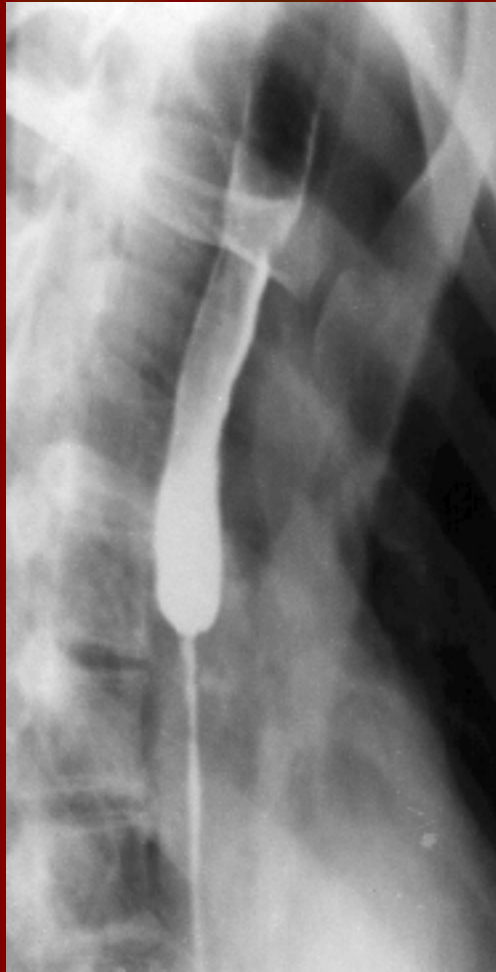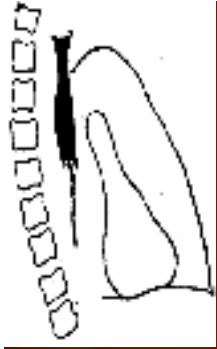
Diverticol epifrenic



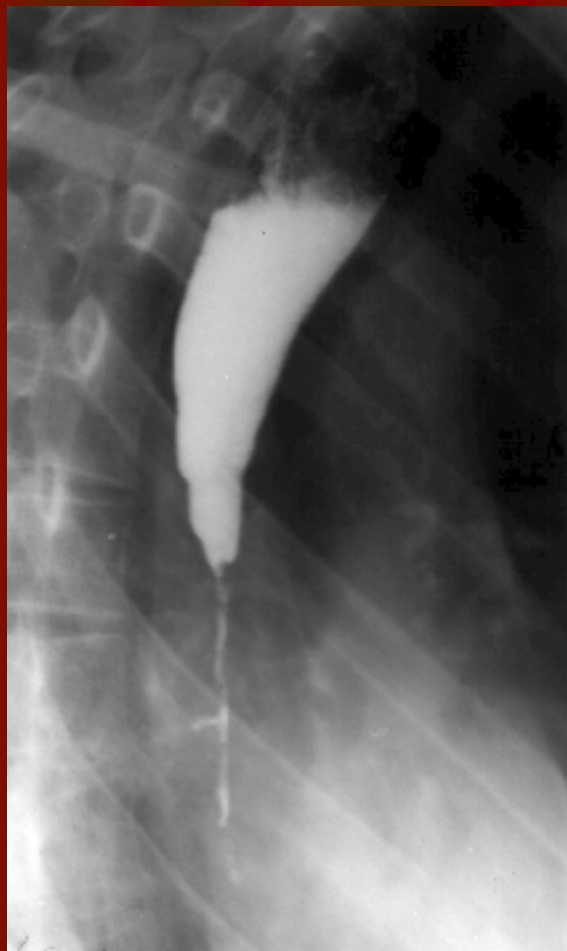Cancer vegetant esofagian



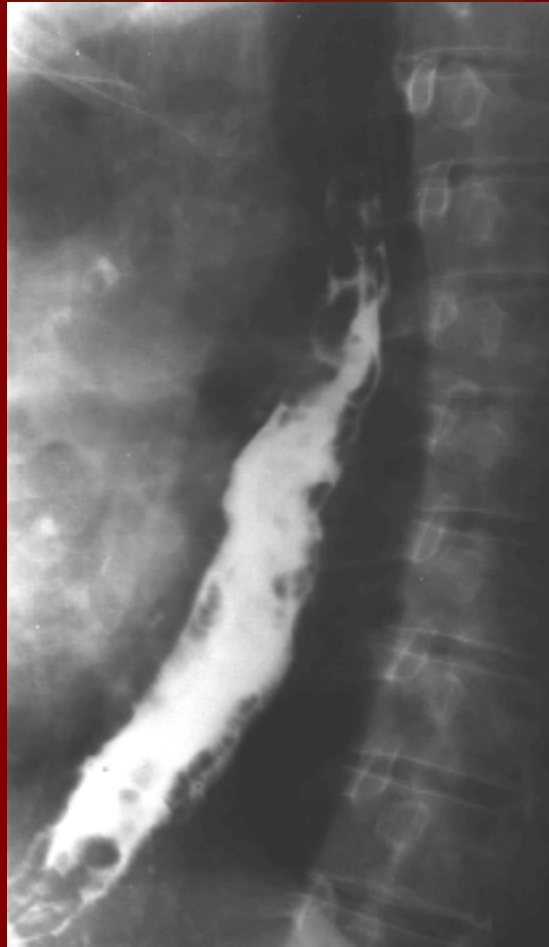
Fistula eso-bronșică



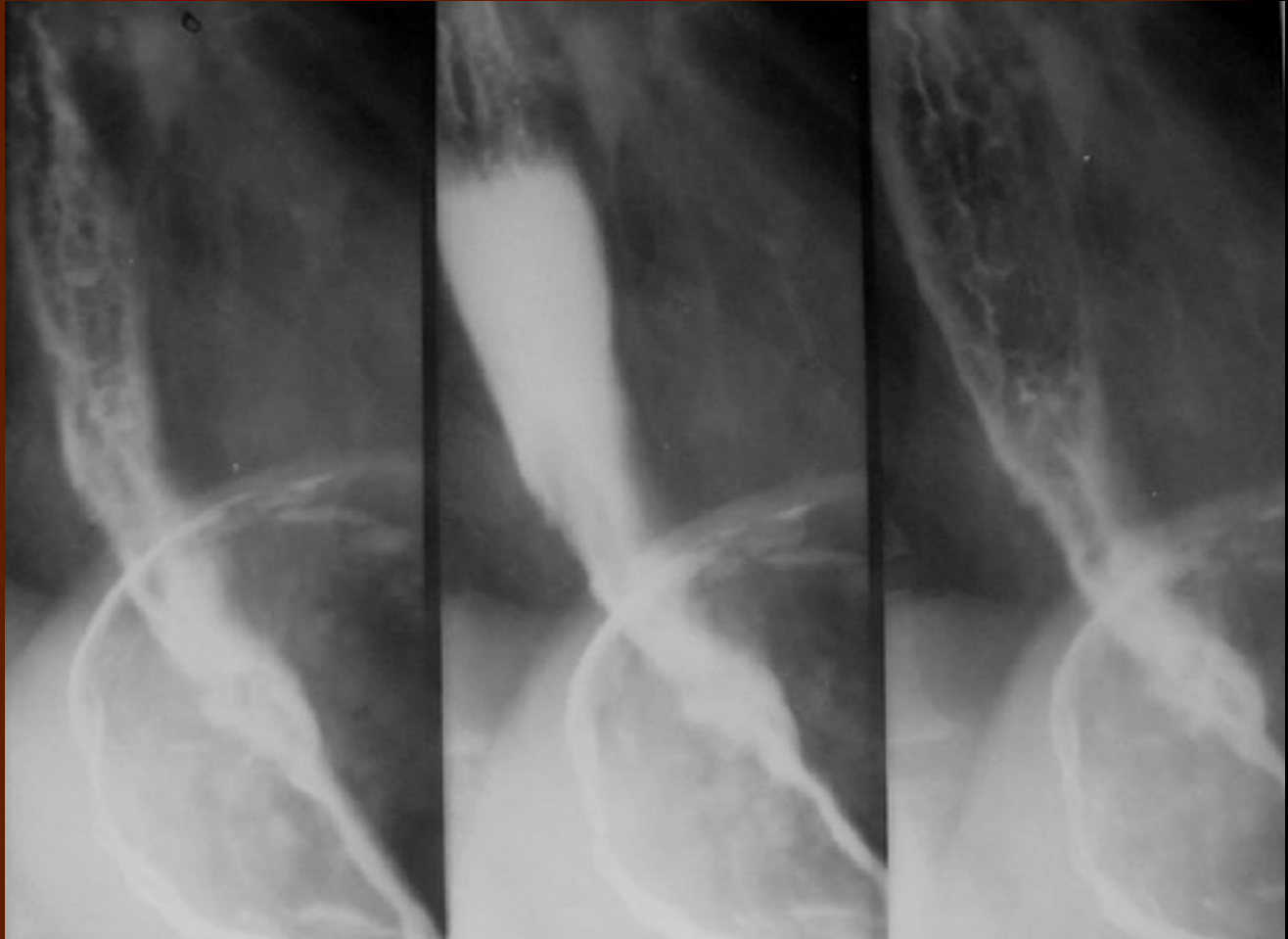
Neoplasm esofagian infiltrativ



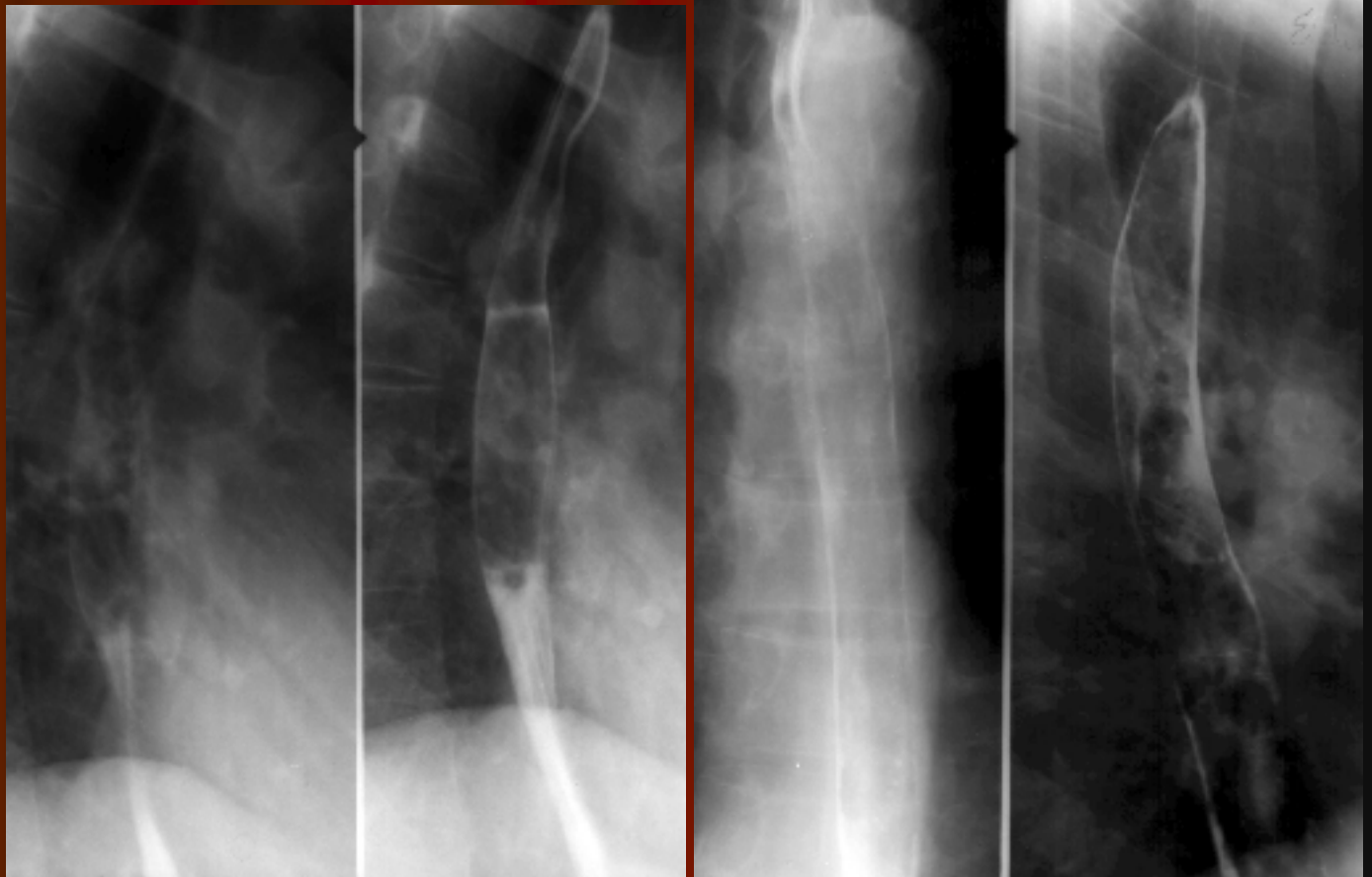
Stenoză esofagiană postcaustică



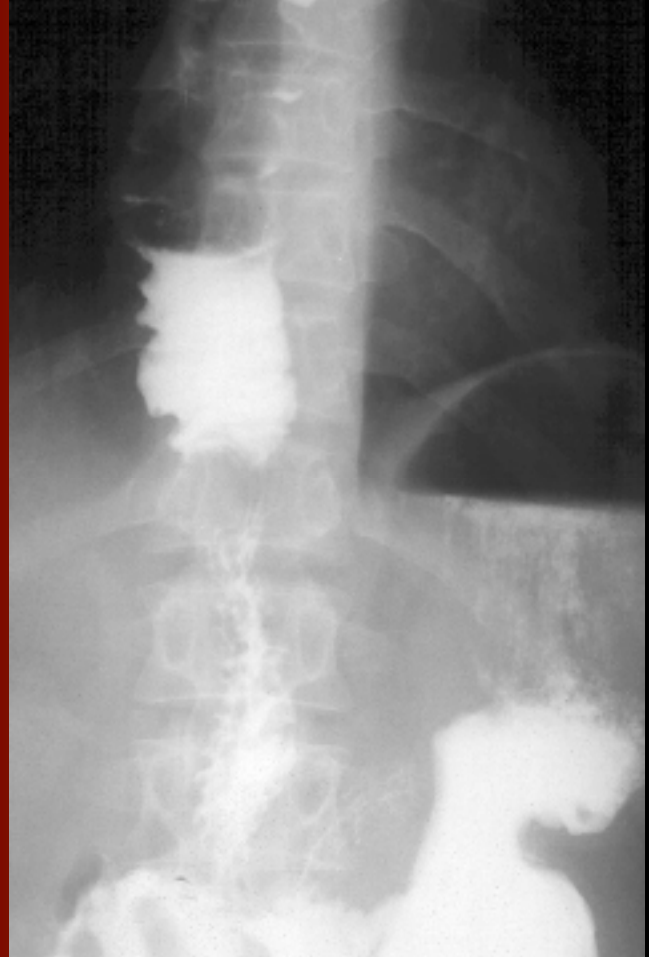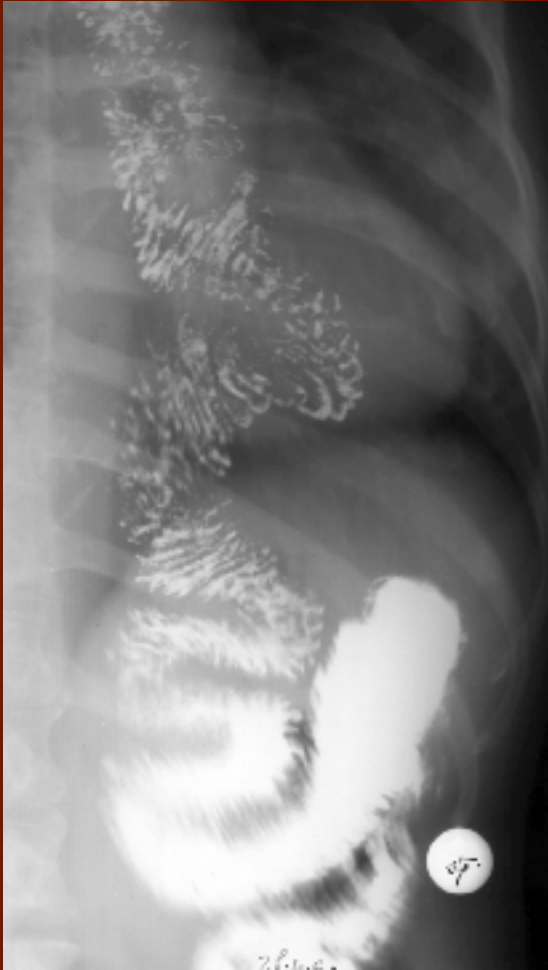
Varicele esofagiene



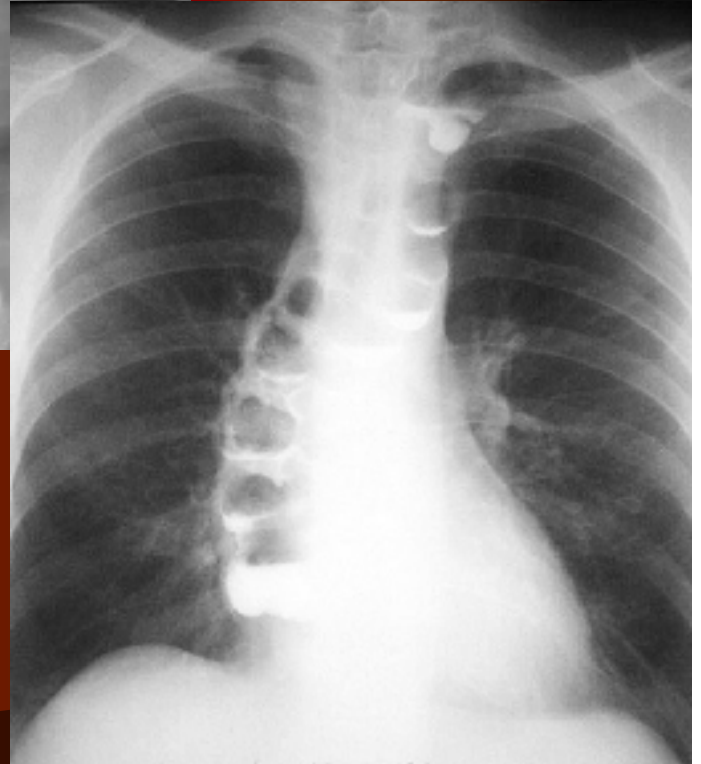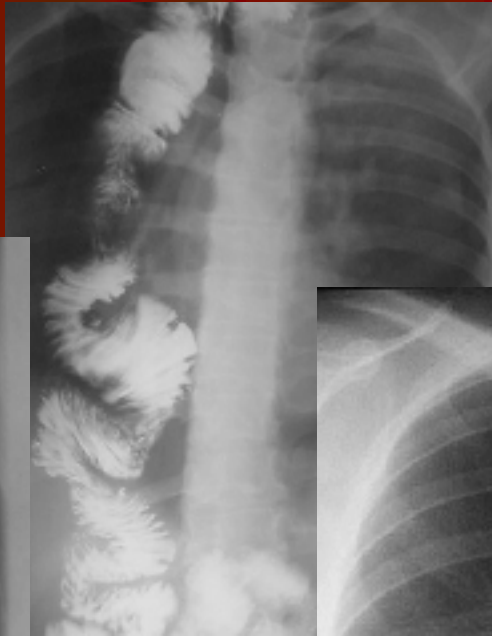
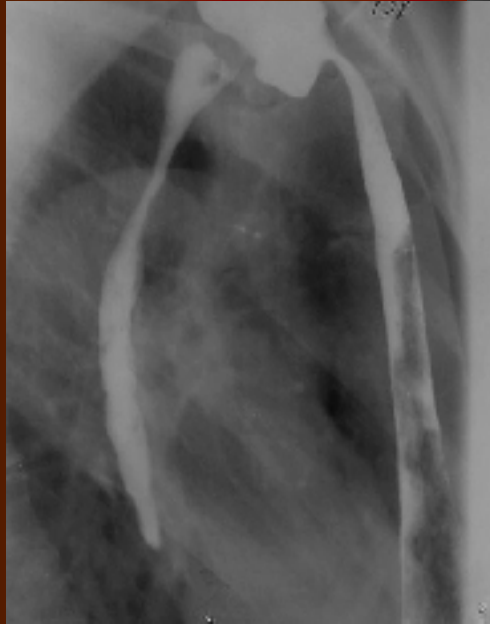Varice esofagiene



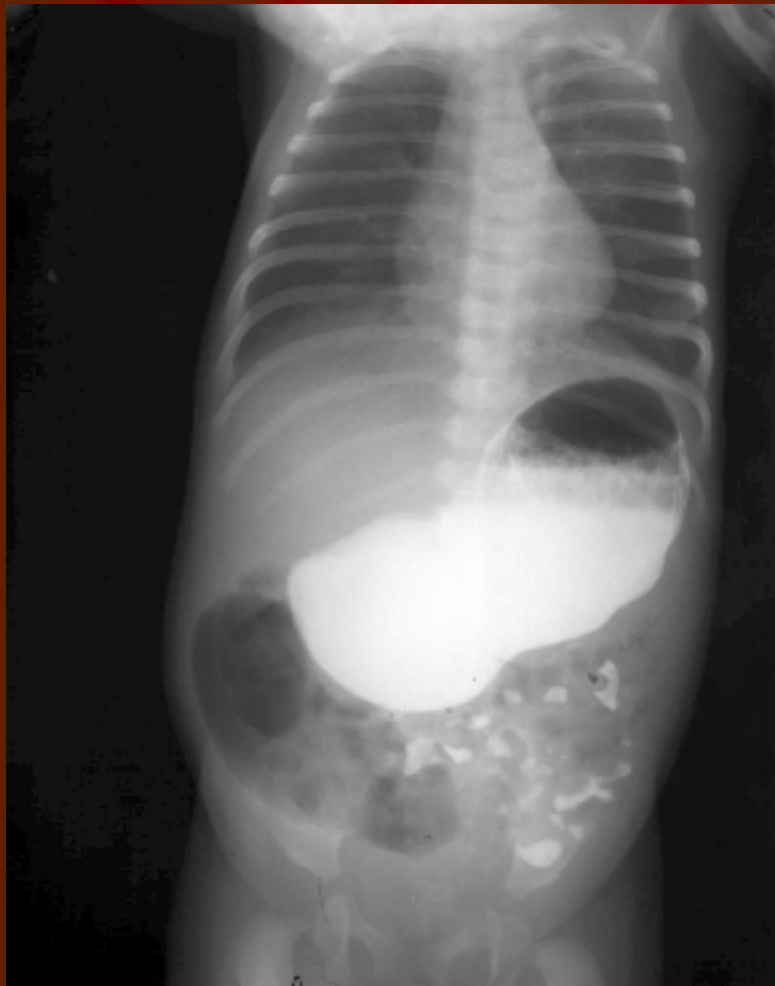
Sclerodermia esofagiană – esofag de sticla



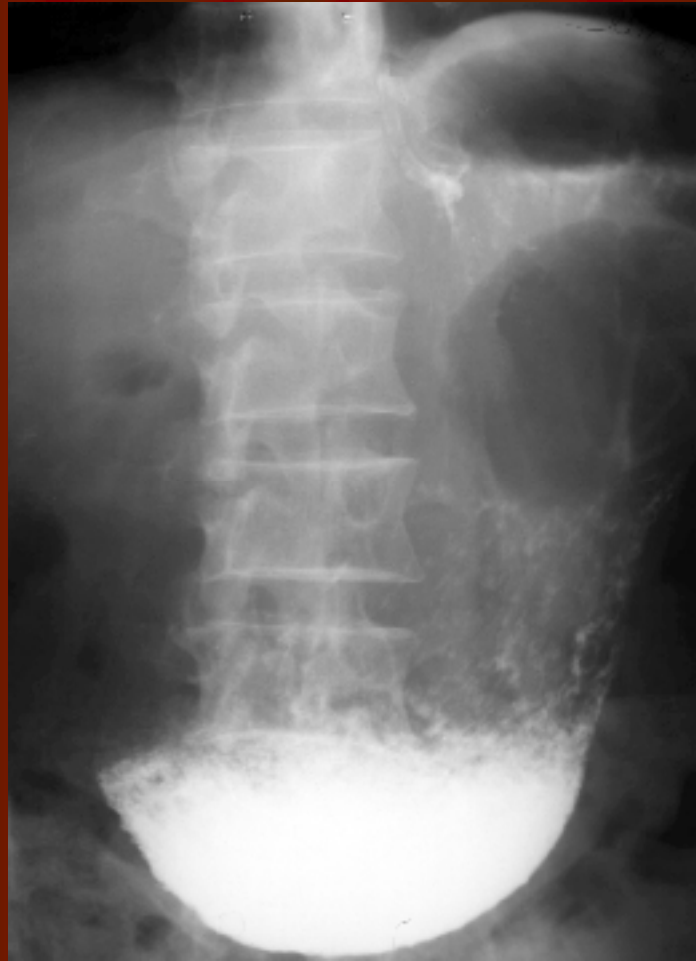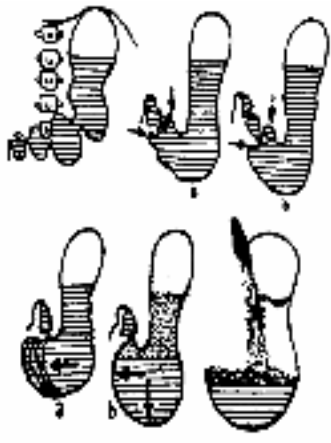
Esofagoplastii cu intestin subțire respectiv colon



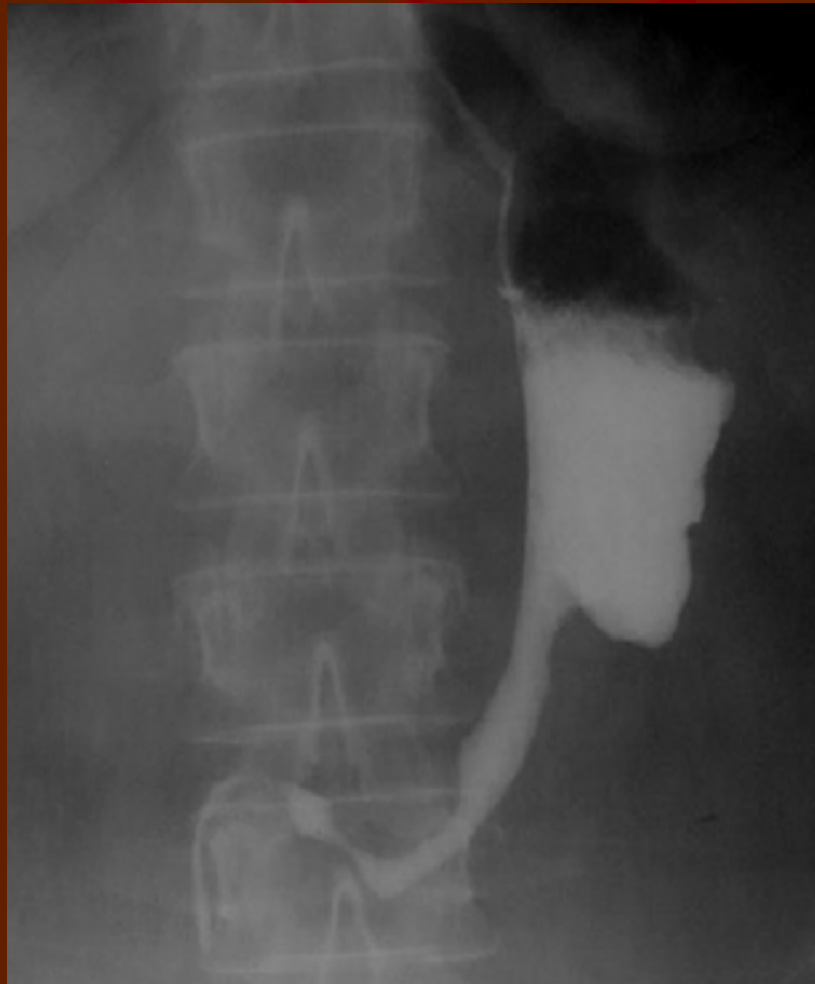Esofagoplastii



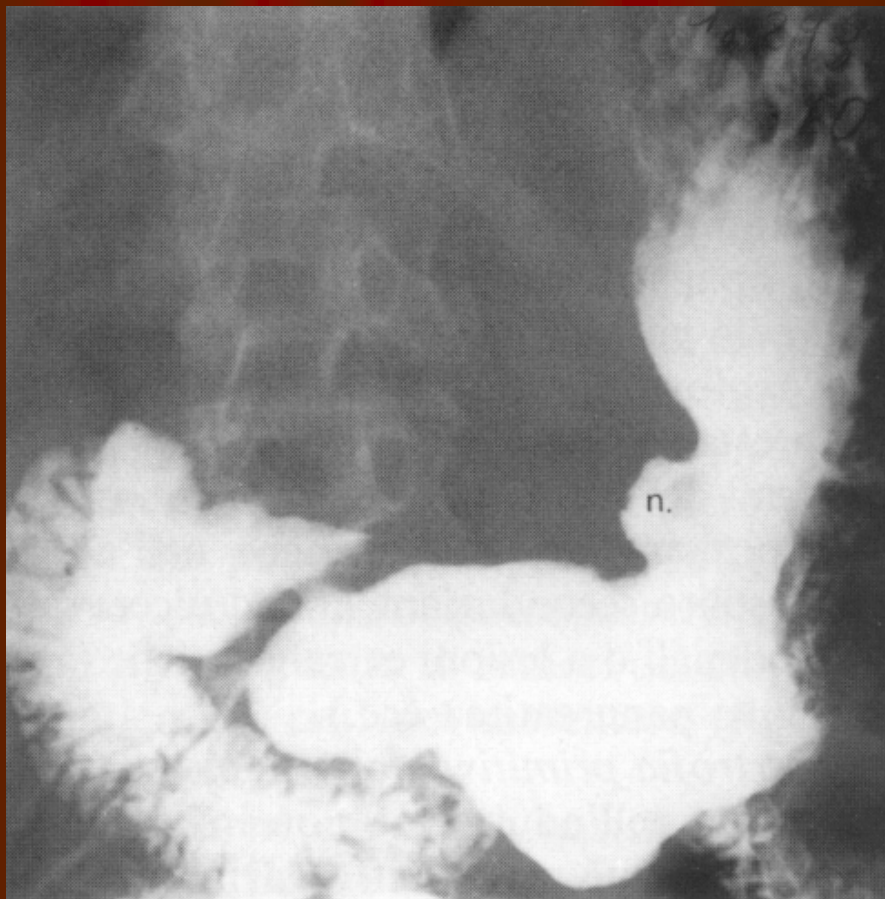
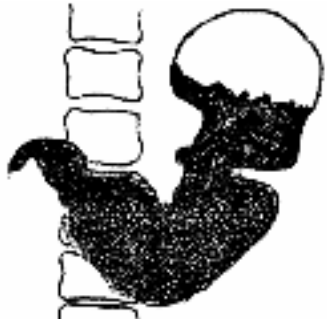Stenoza pilorică la nou-născut



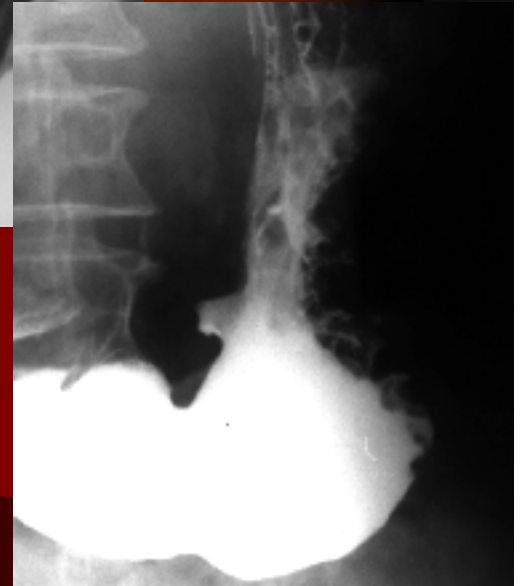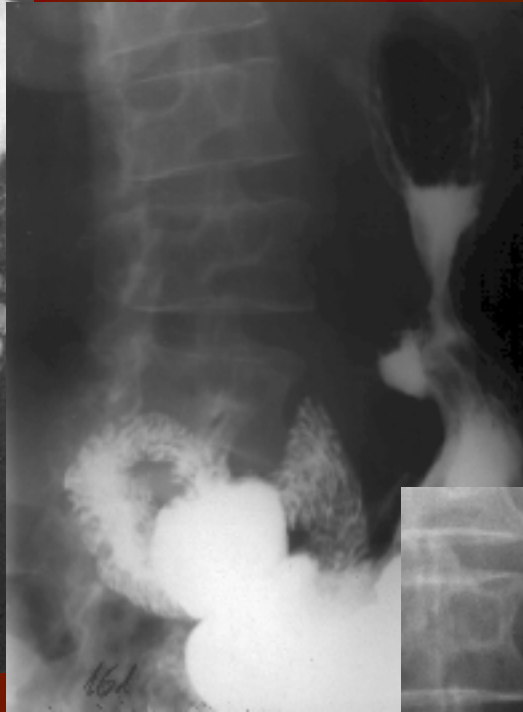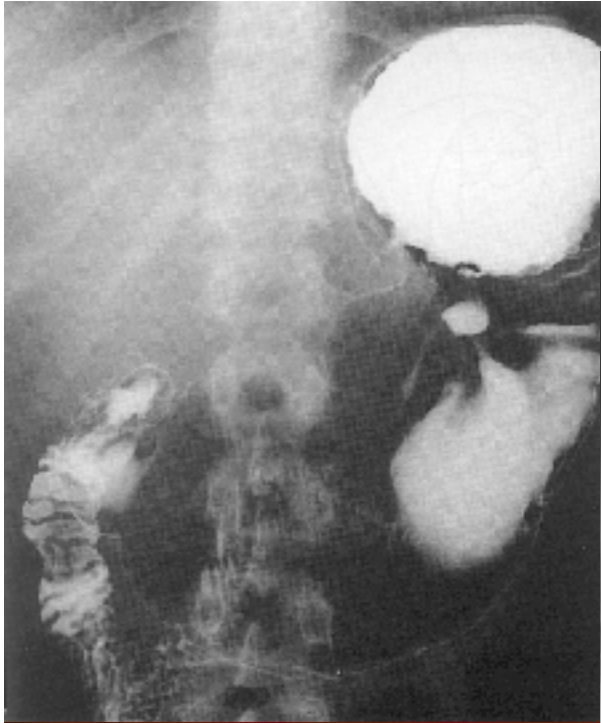
Stenoza pilorică la adult



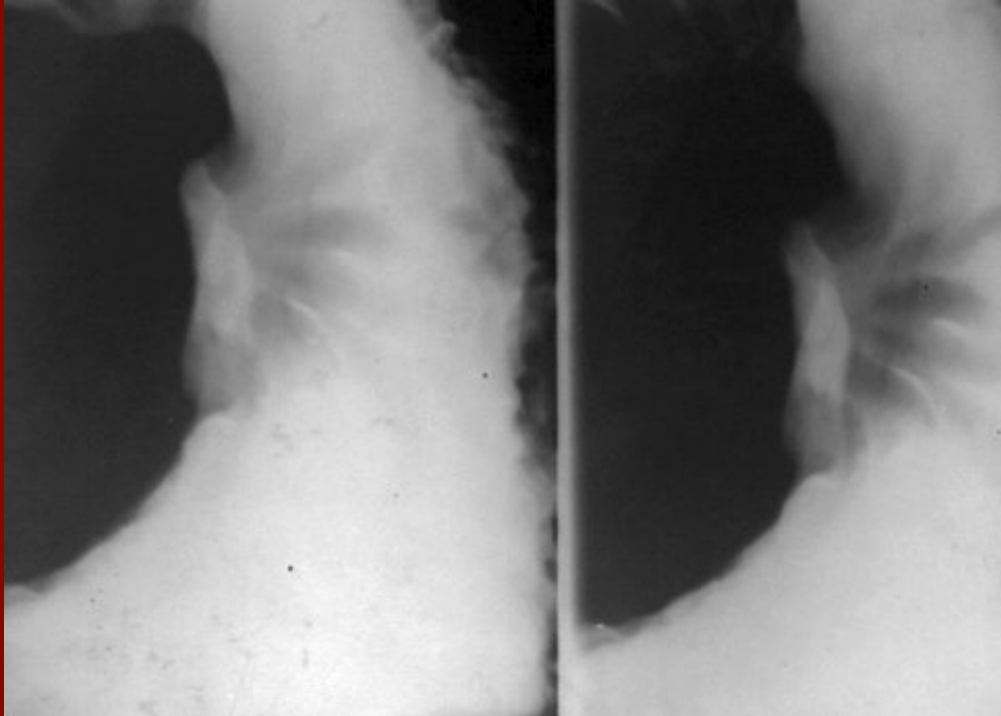
Stenoza gastrica post caustica



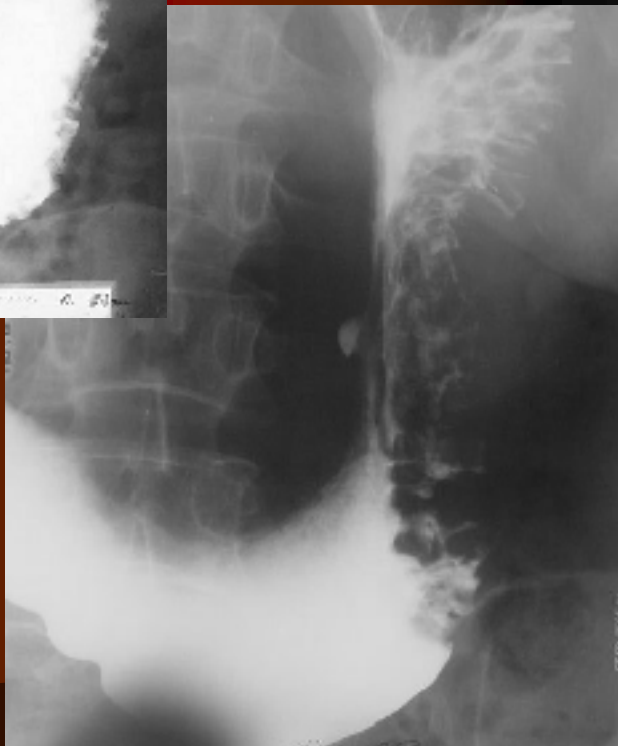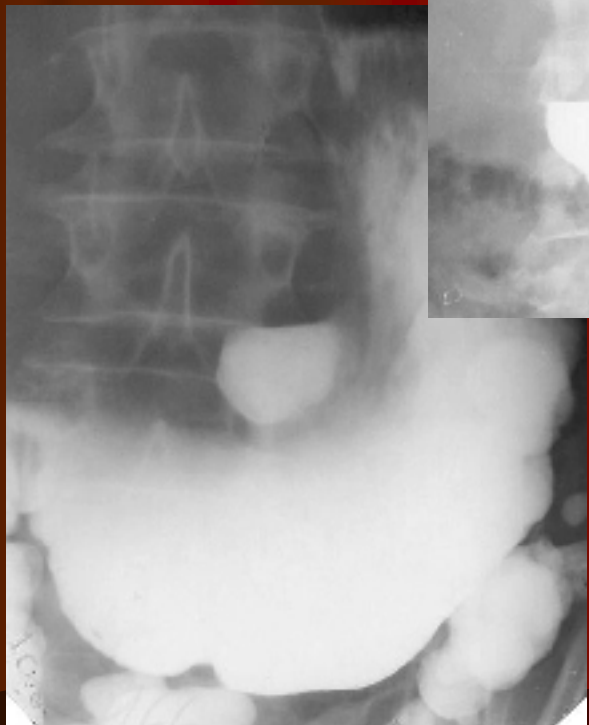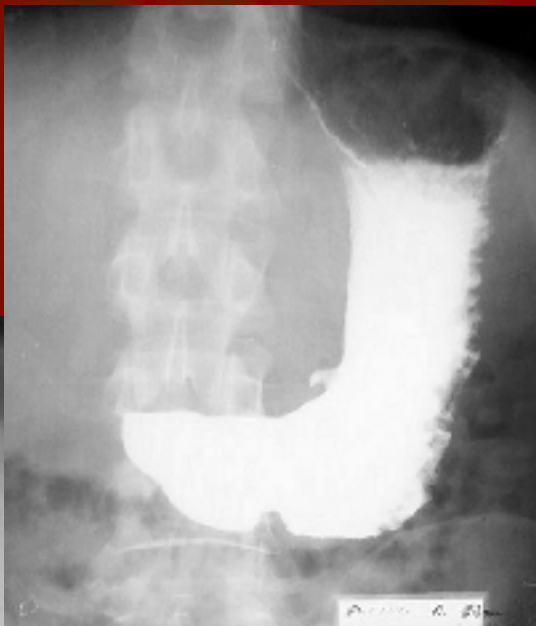Nișa benignă pe mica curbură gastrică

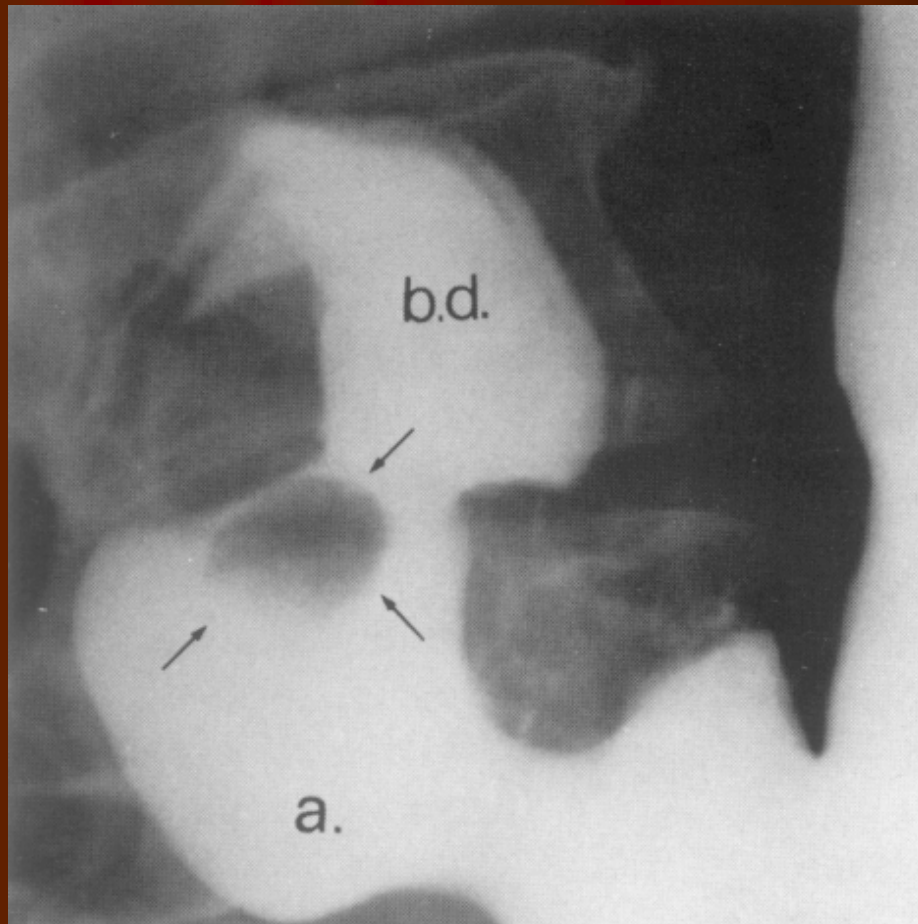


Ulcere benigne gastrice

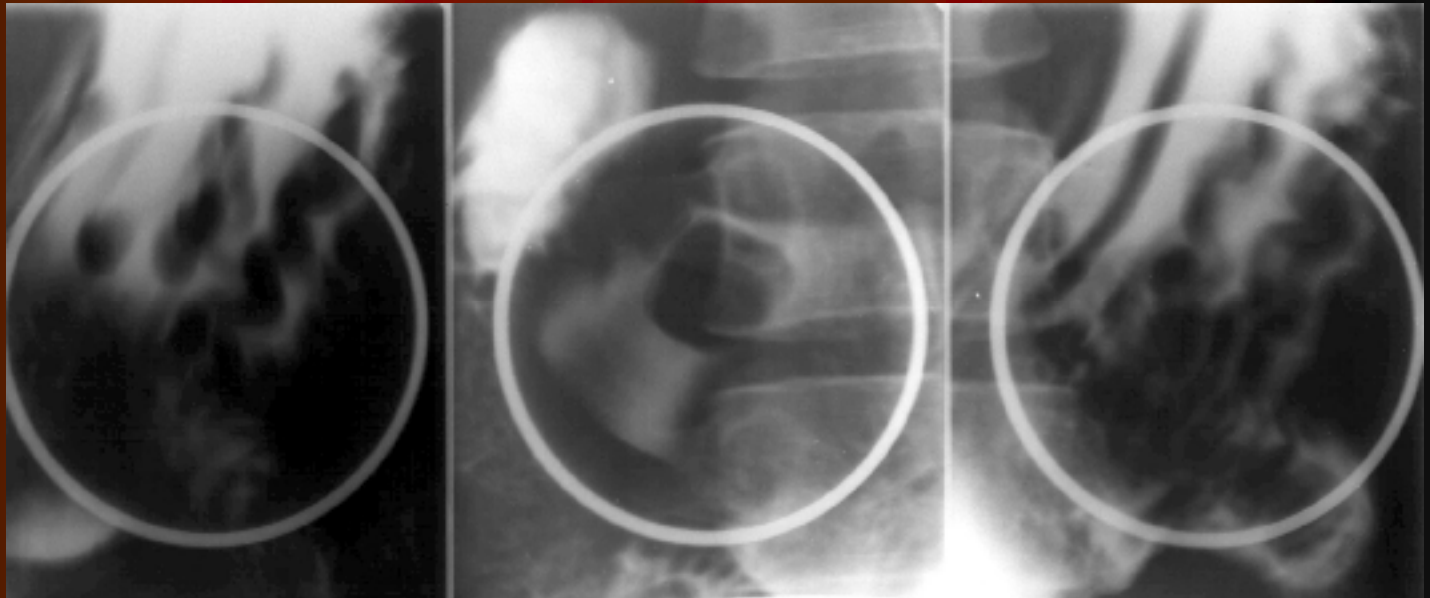


Nișa benignă pe mica curbură gastrică

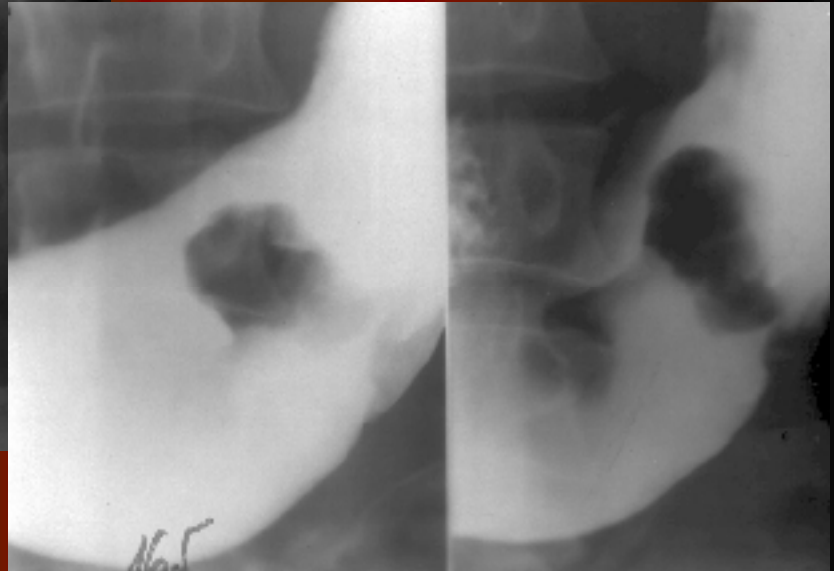
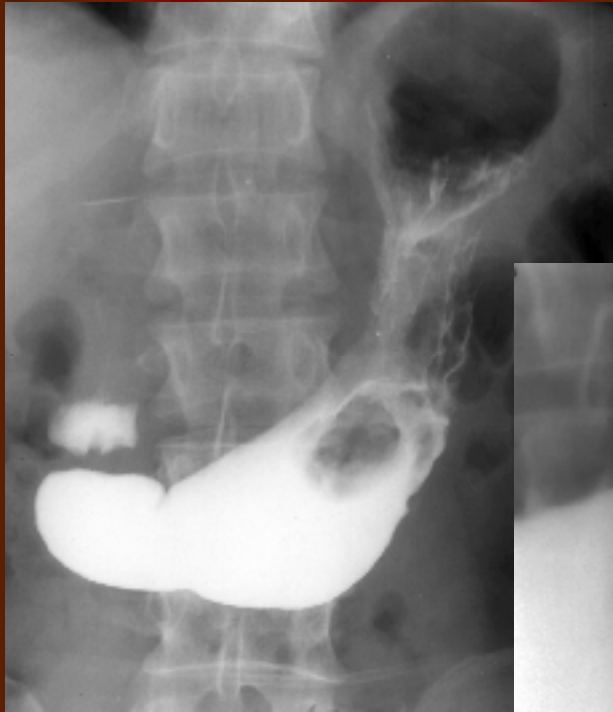



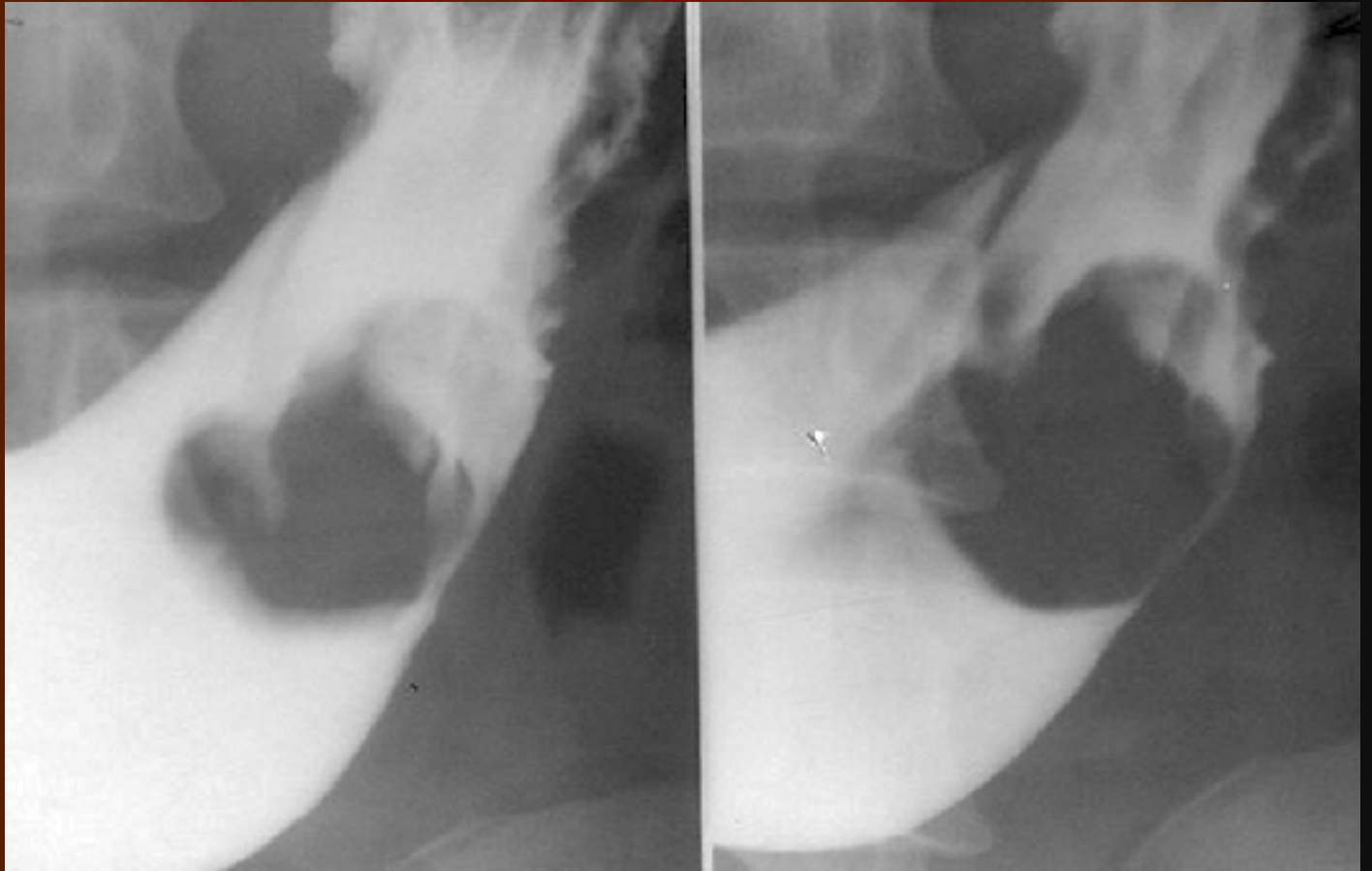
Polipoza gastrică



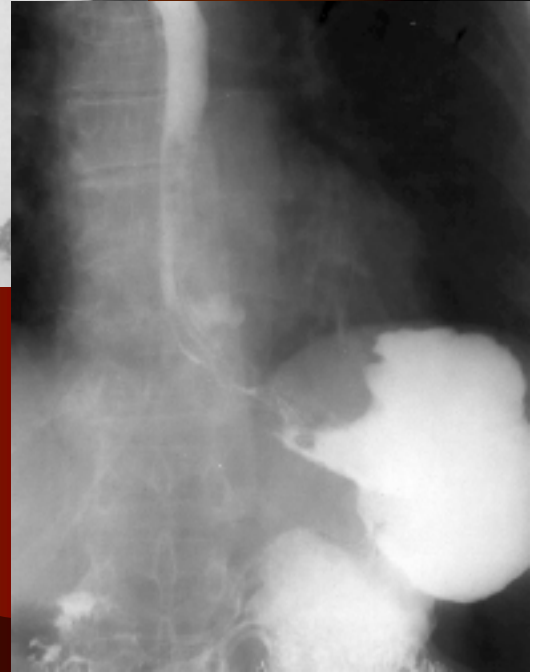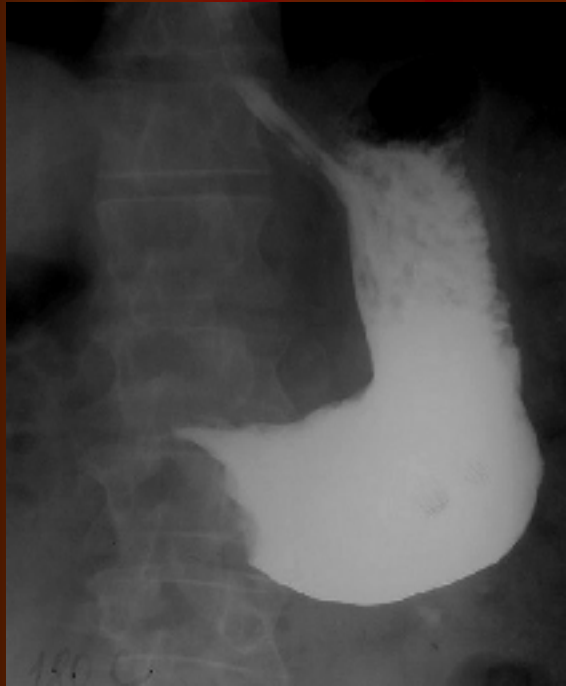
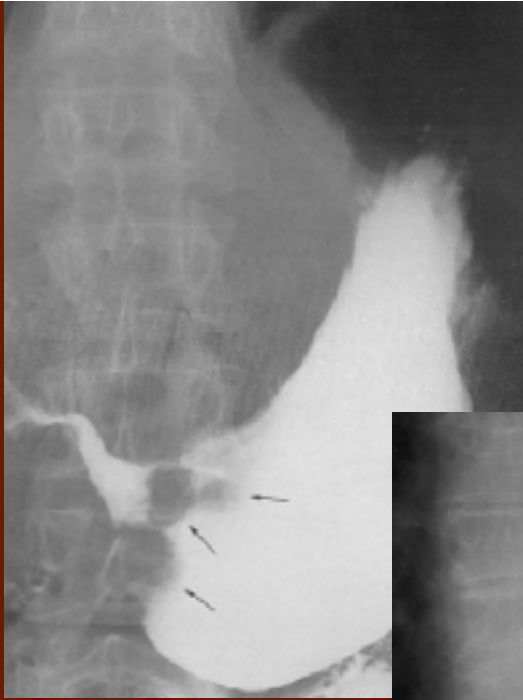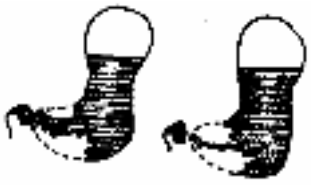
Multiple imagini lacunare-leziuni benigne



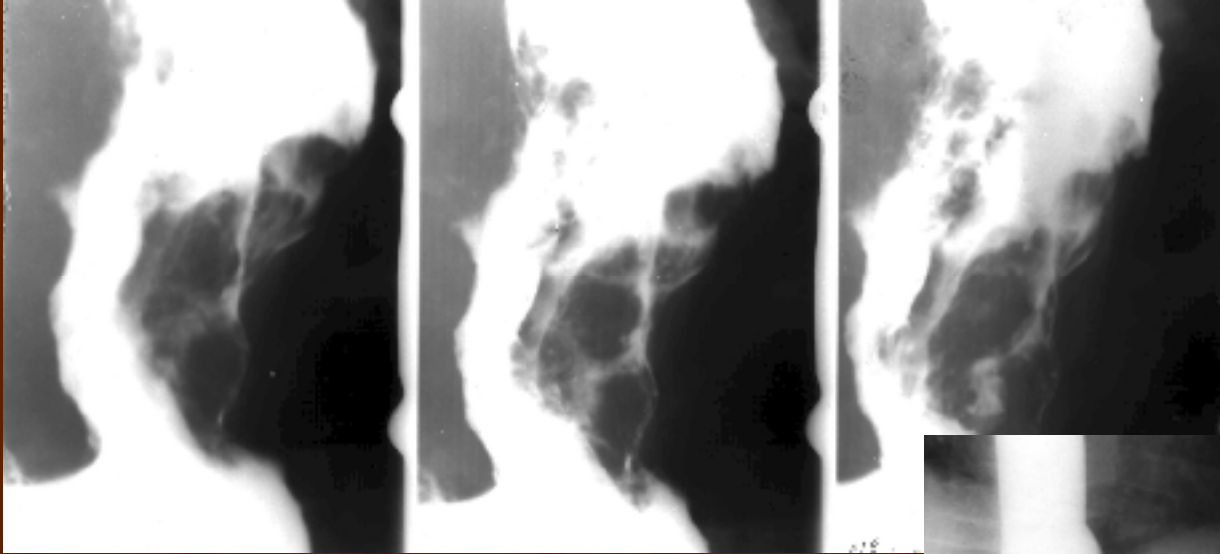
Imagini lacunare-leziuni benigne



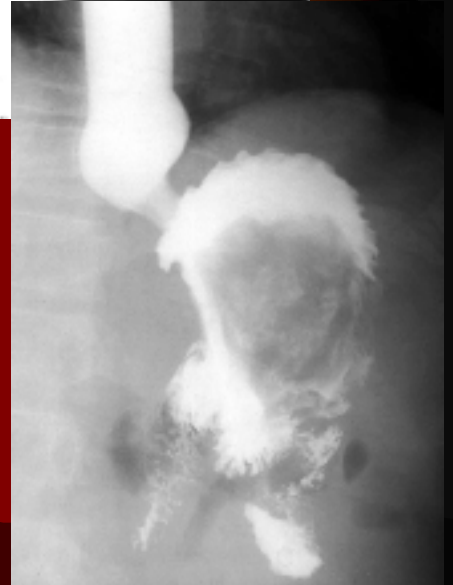
Polip gastric malignizat

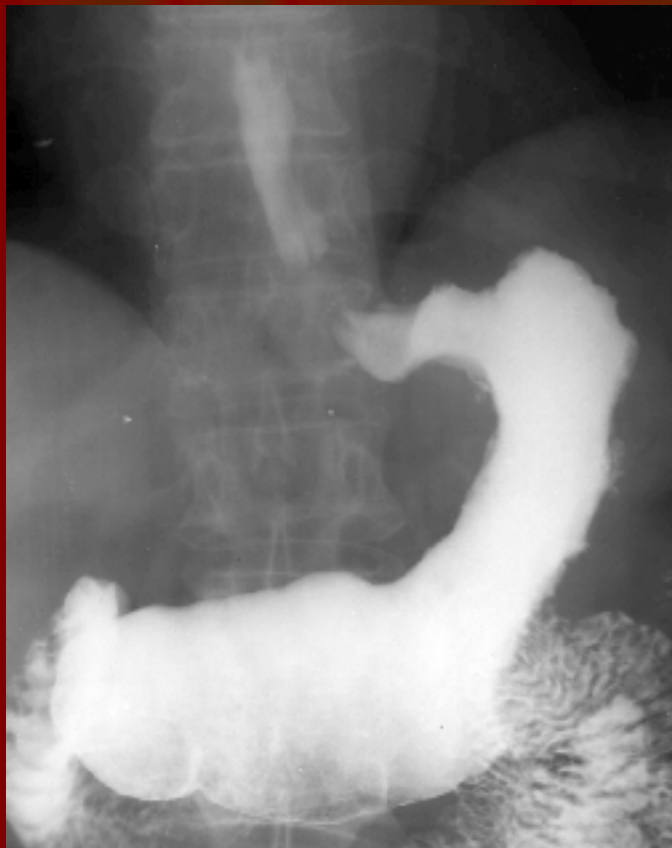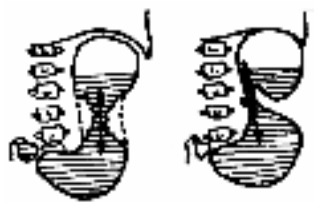


Cancer gastric vegetant - fornix, respectiv antral

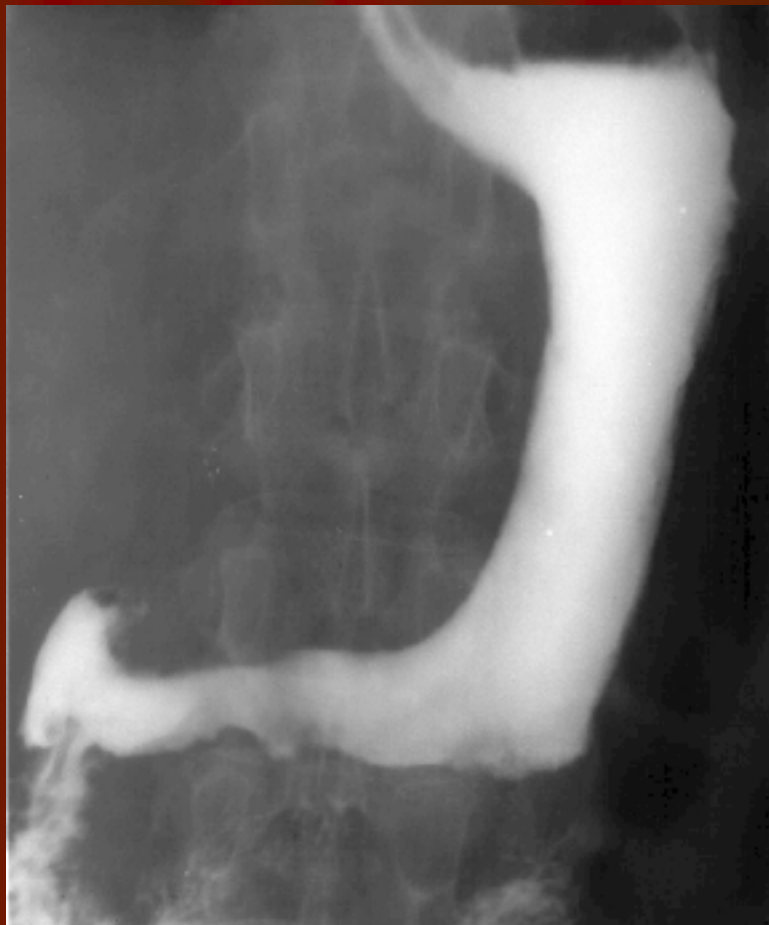

Cancer vegetant la nivelul corpului gastric

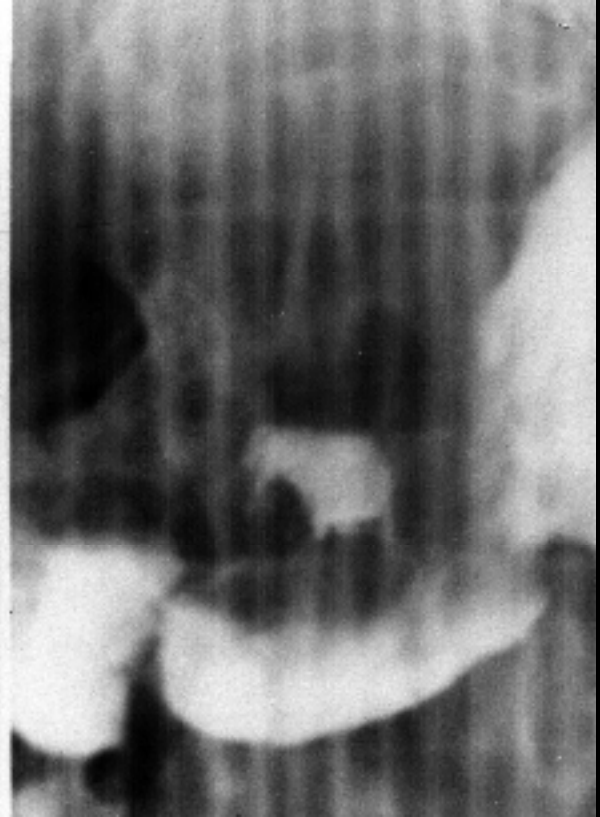
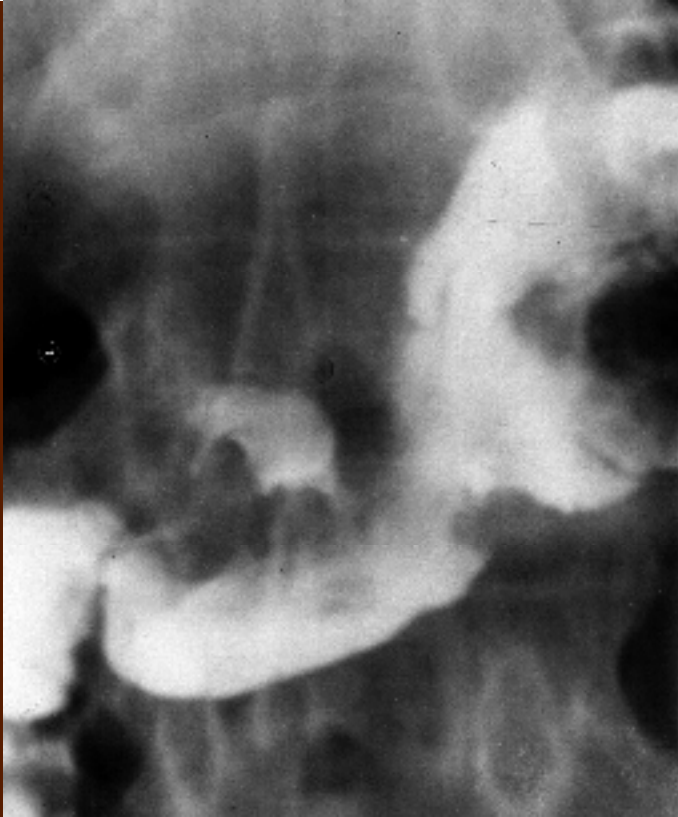
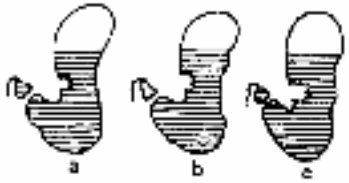




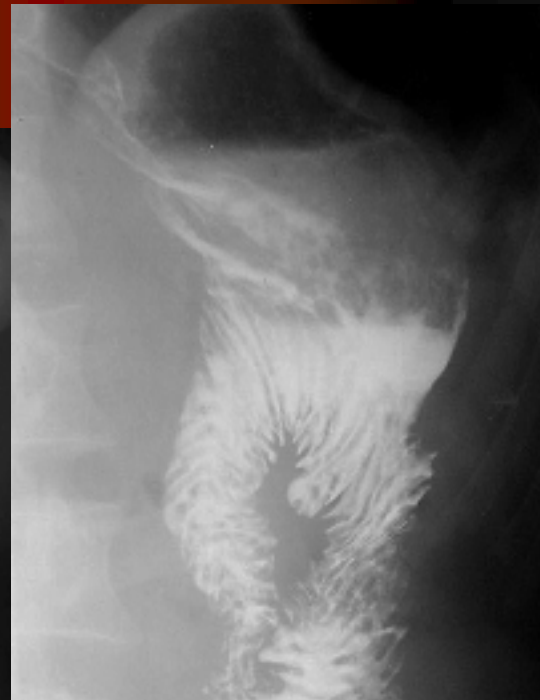
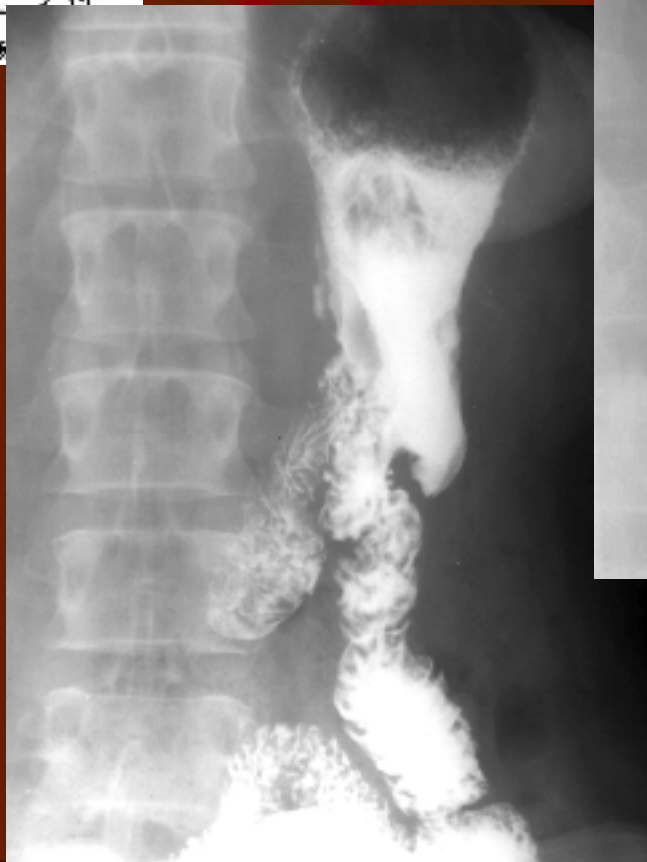Cancer infiltrativ gastric-corp gastric



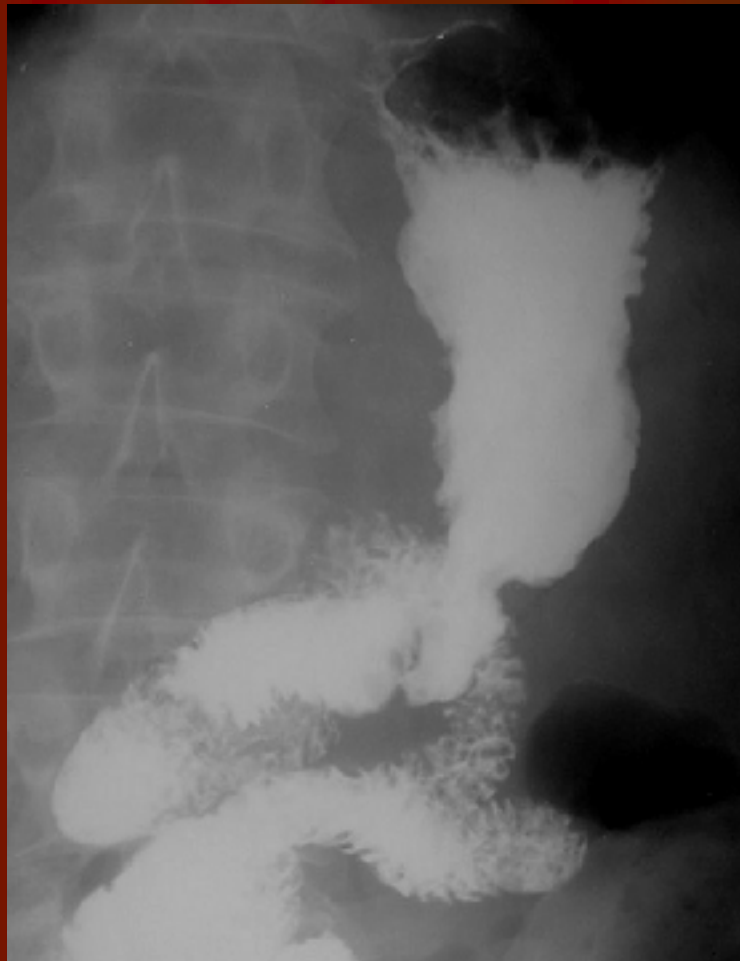
Cancer infiltrativ antral (aspect de linită plastică)



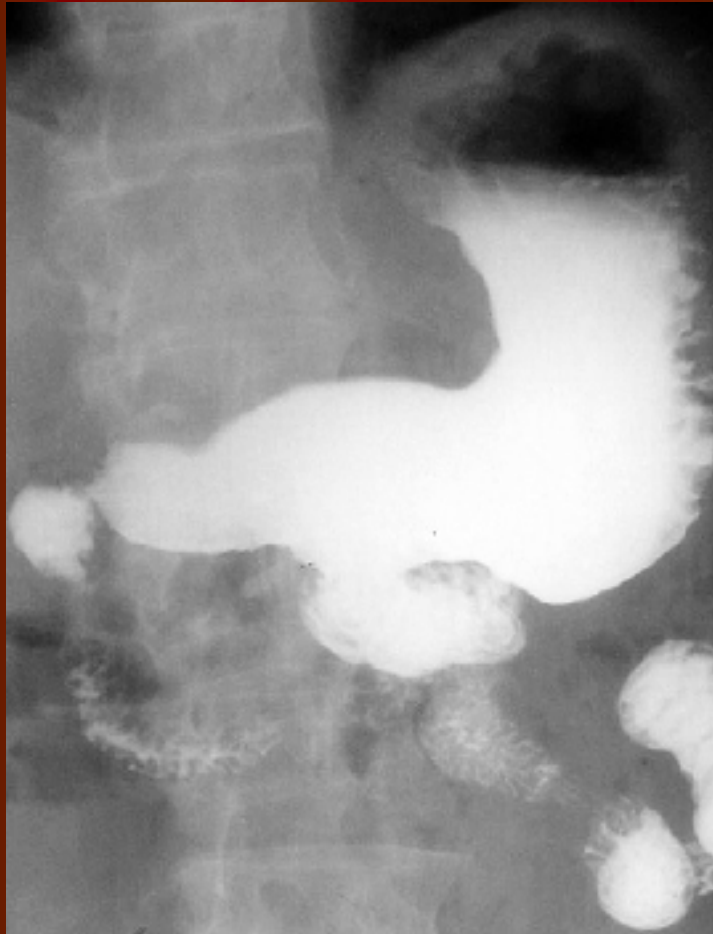Nișa malignă-nișa în lacună



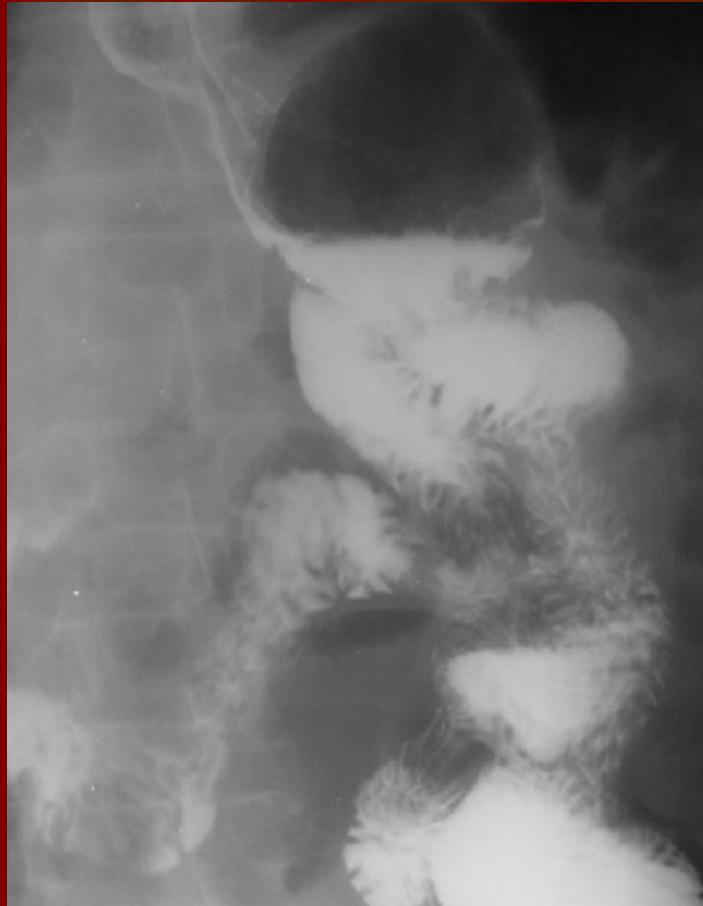Anastomoză gastro-intestinală termino-laterală



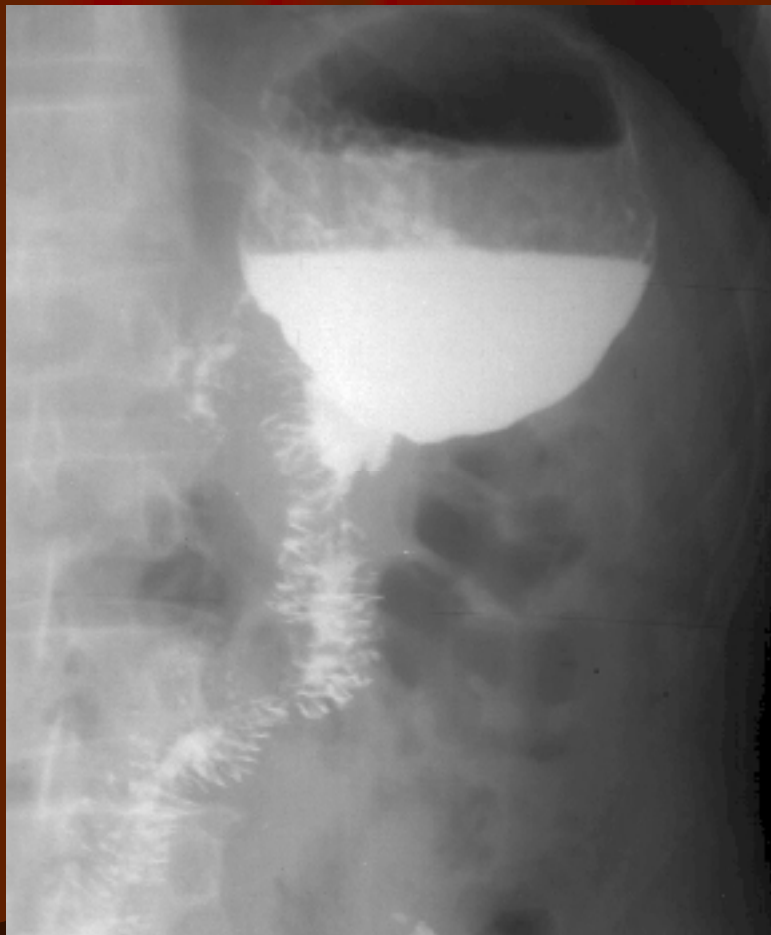Rezectie gastrică cu anastomoză termino-terminală

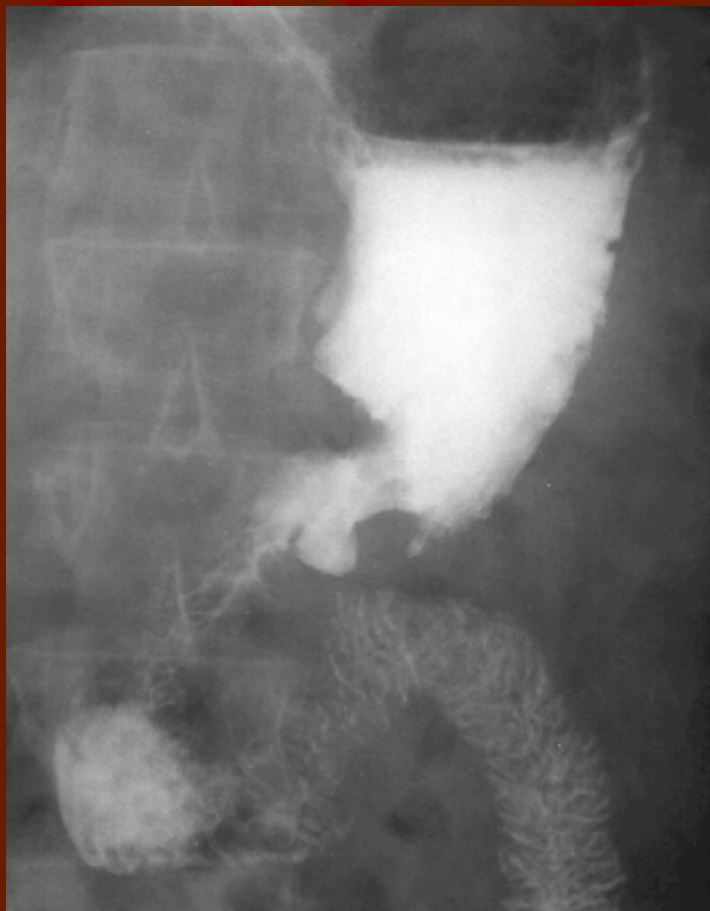

Gastro-entero-anastomoză retrocolică

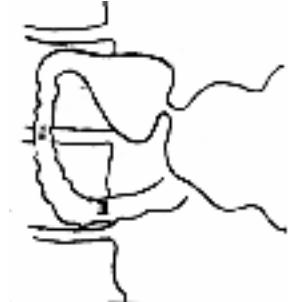


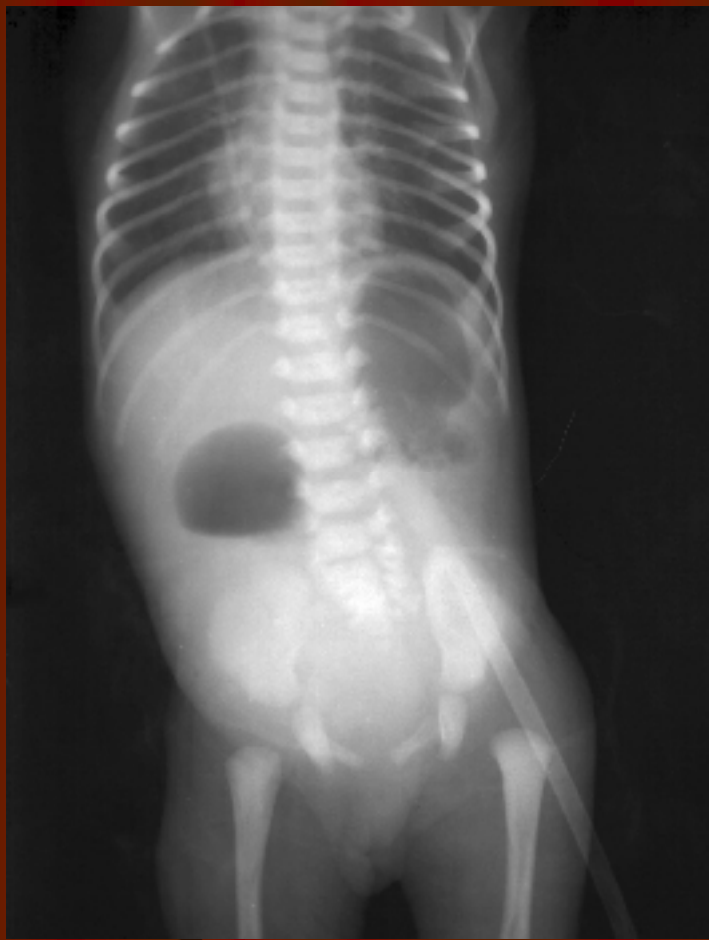Rezecție gastrică subtotală cu anastomoză T-L



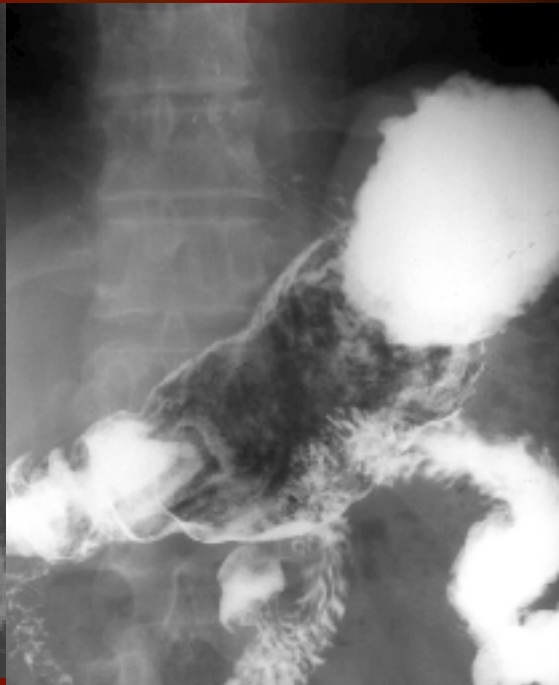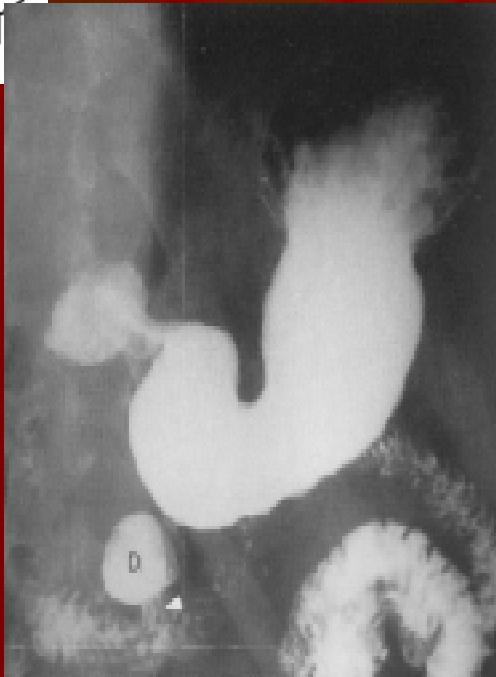


Cancerul bontului

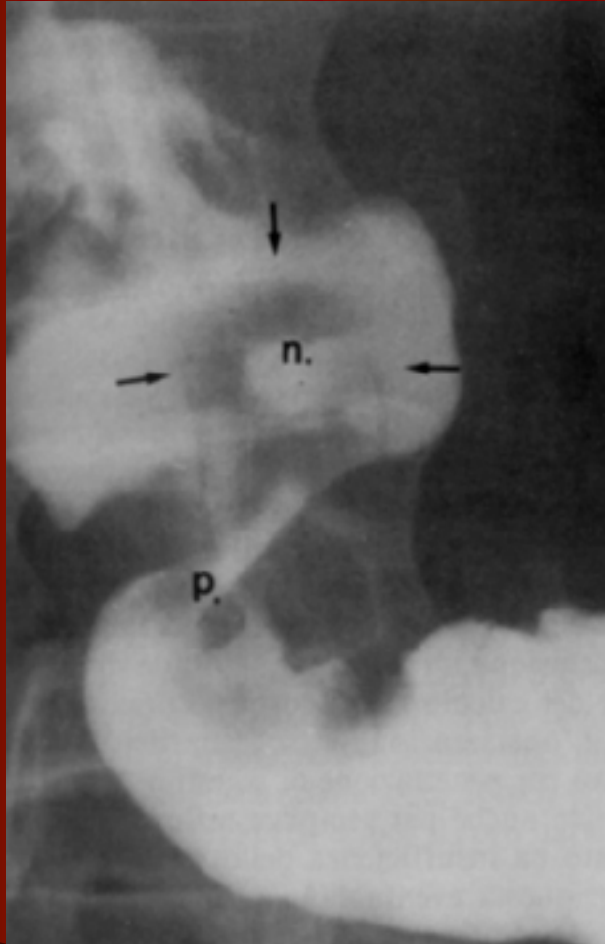




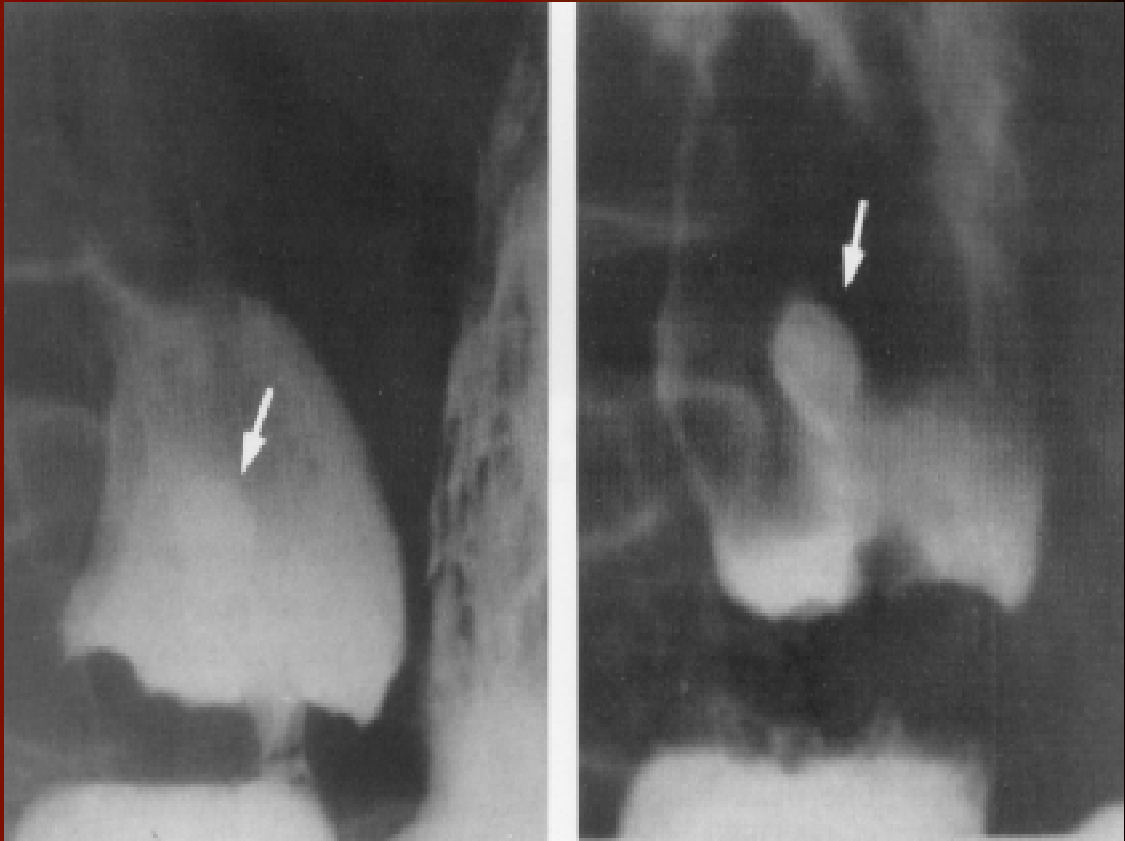Atrezia duodenală



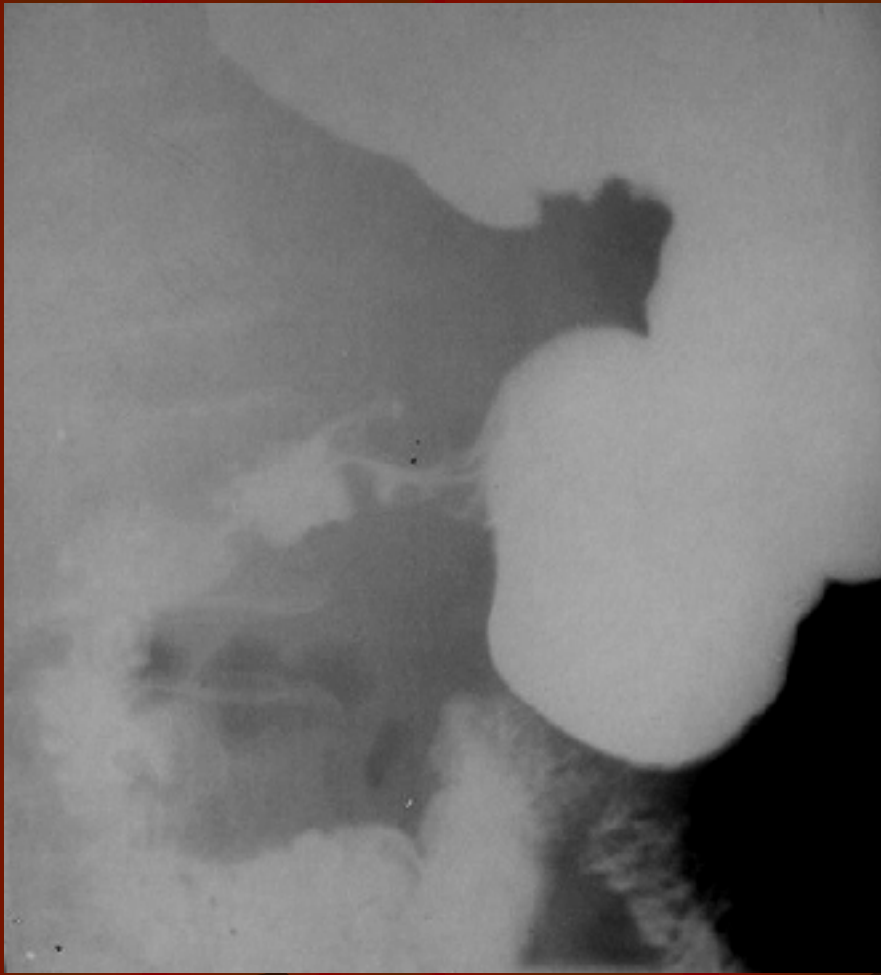
Diverticoli duodenali



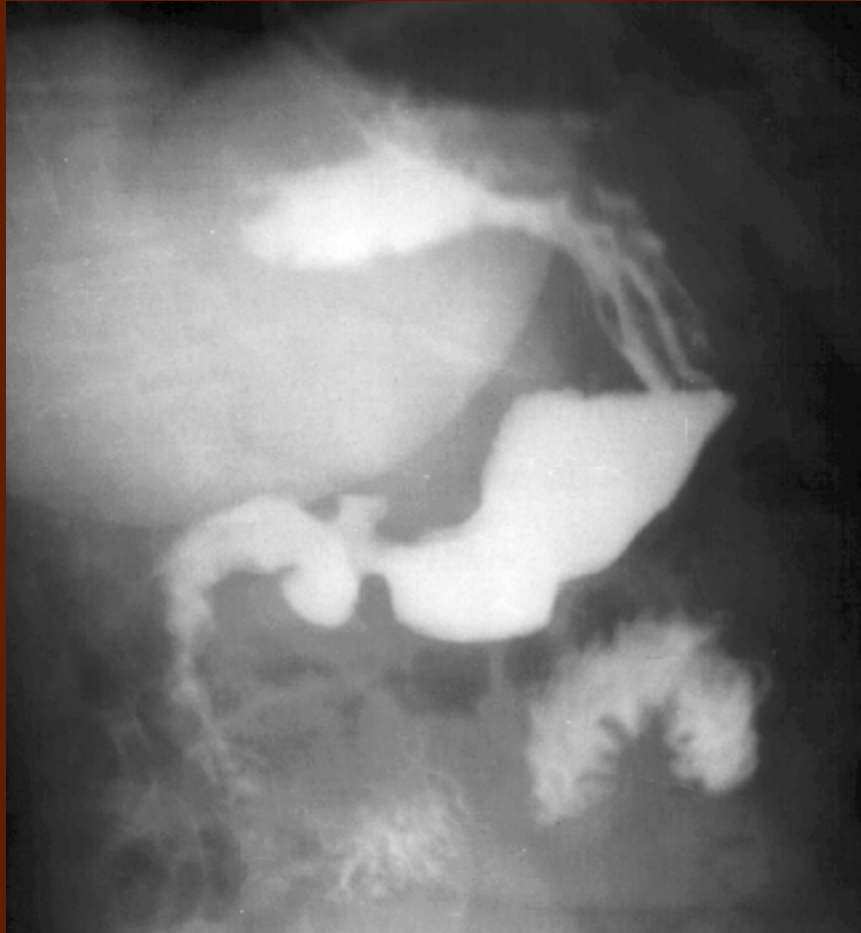Ulcer acut bulbar



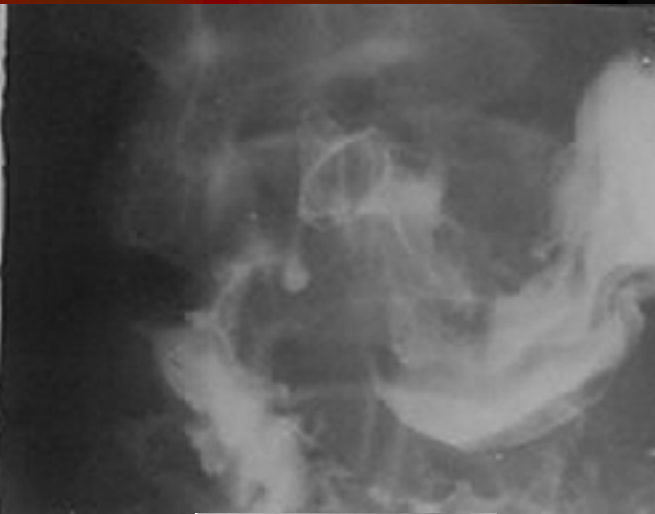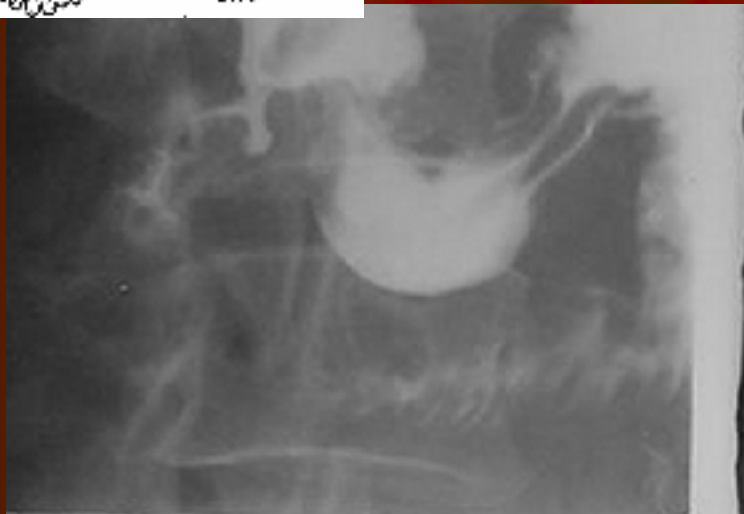Ulcer acut bulbar



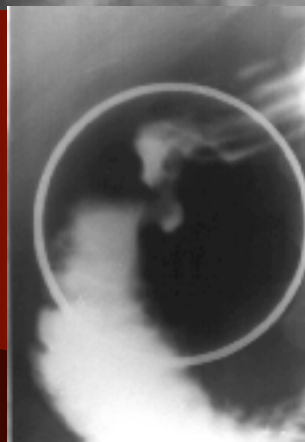
Ulcer piloric

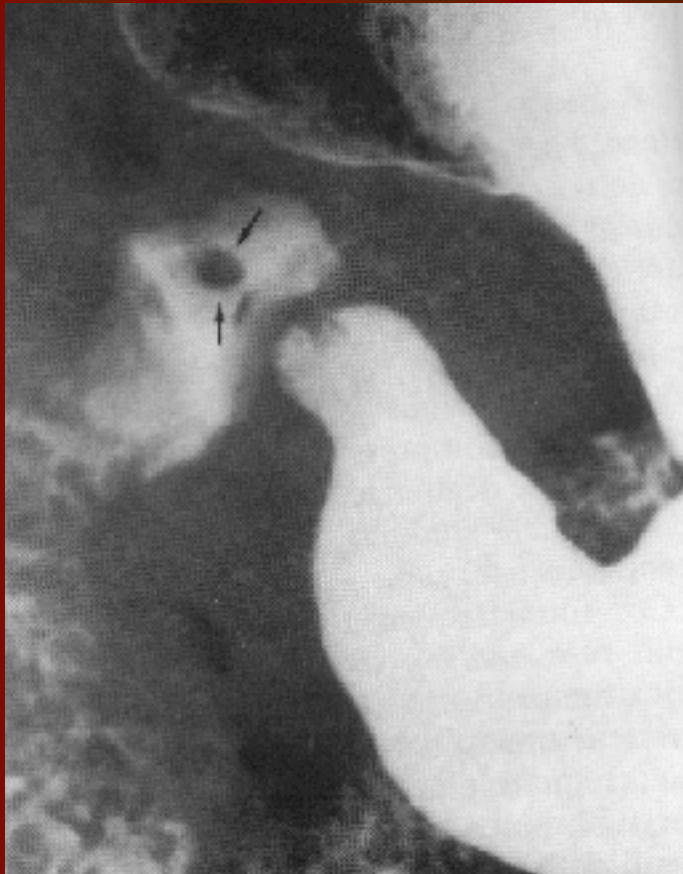


Ulcer bulbar cronic

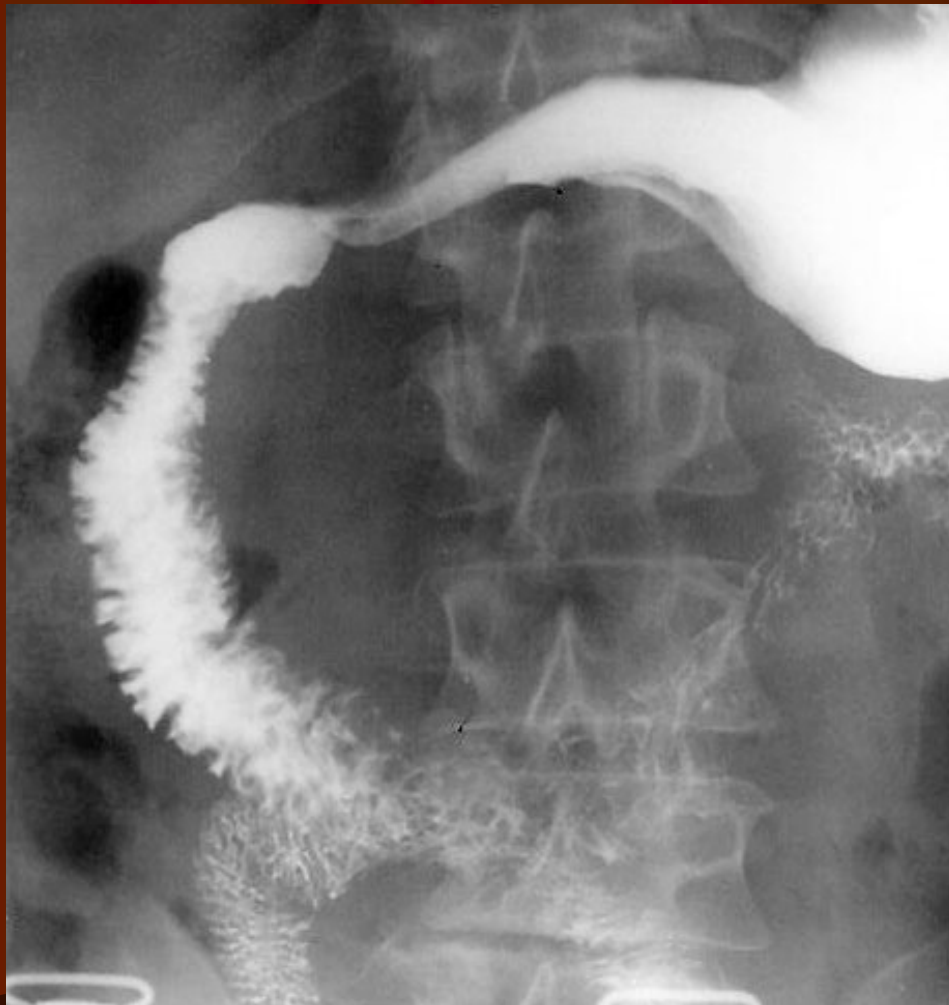

Ulcer postbulbar

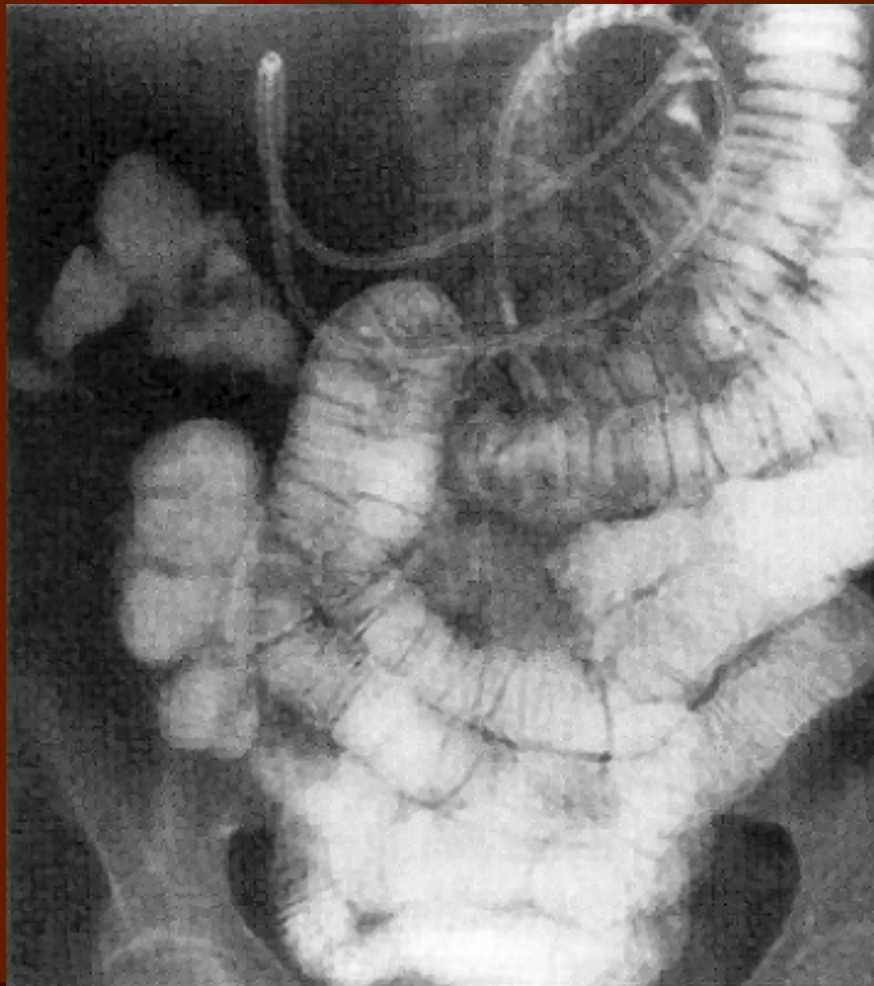




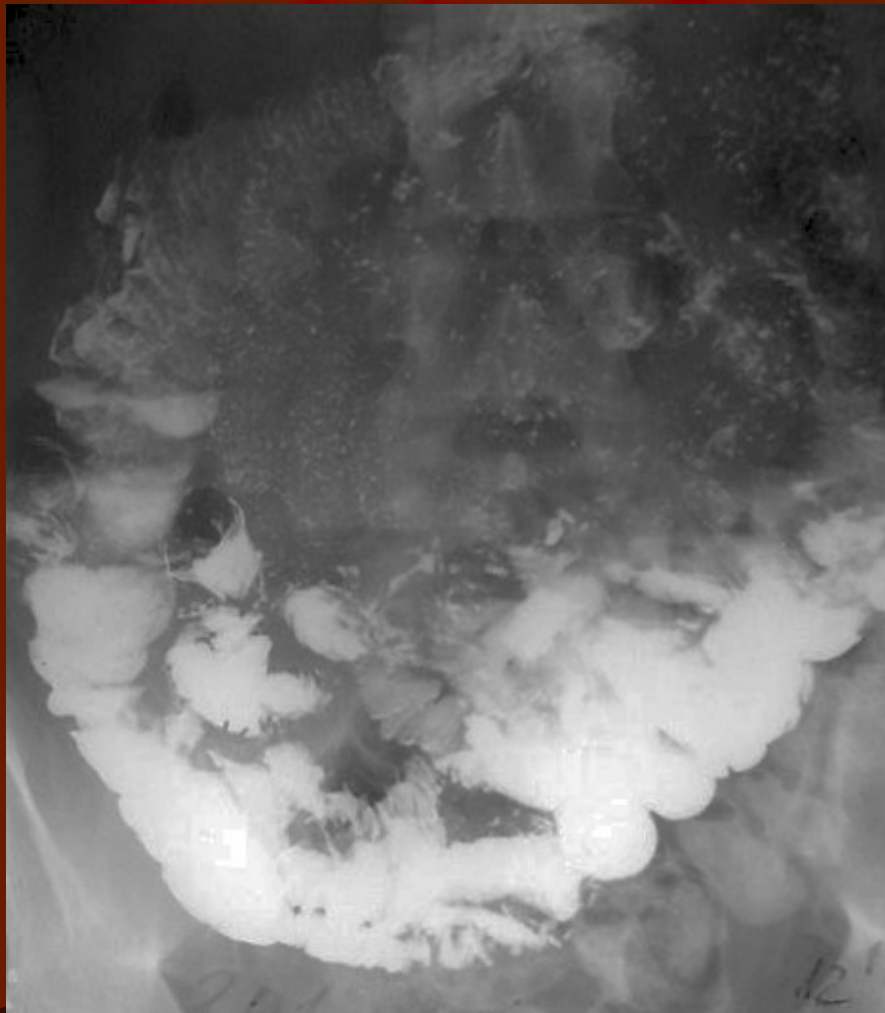
Polip duodenal



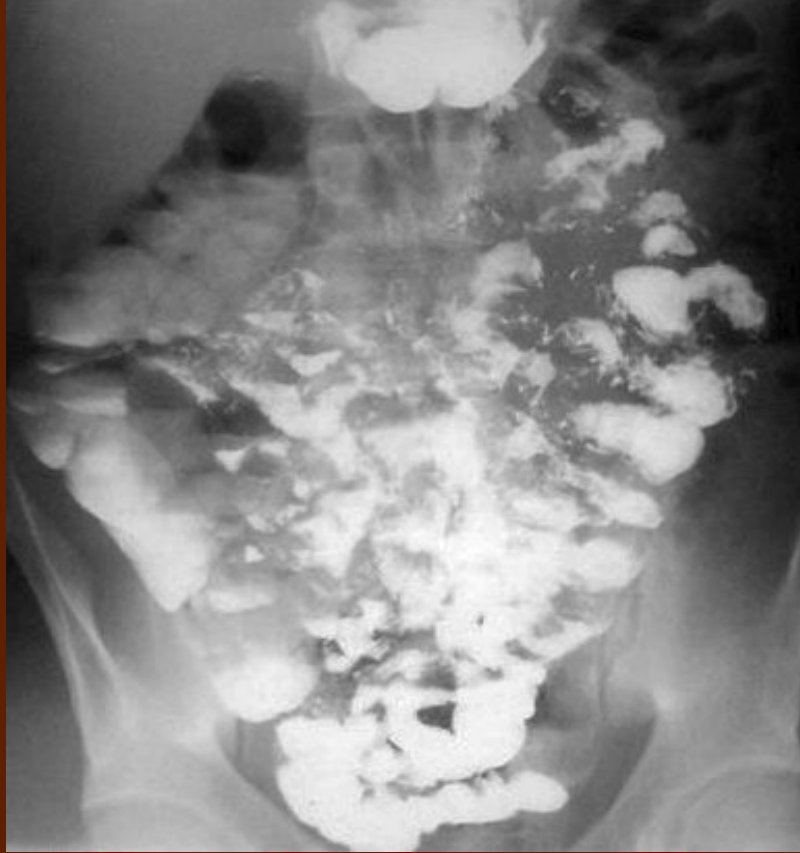
Lărgirea cadrului duodenal



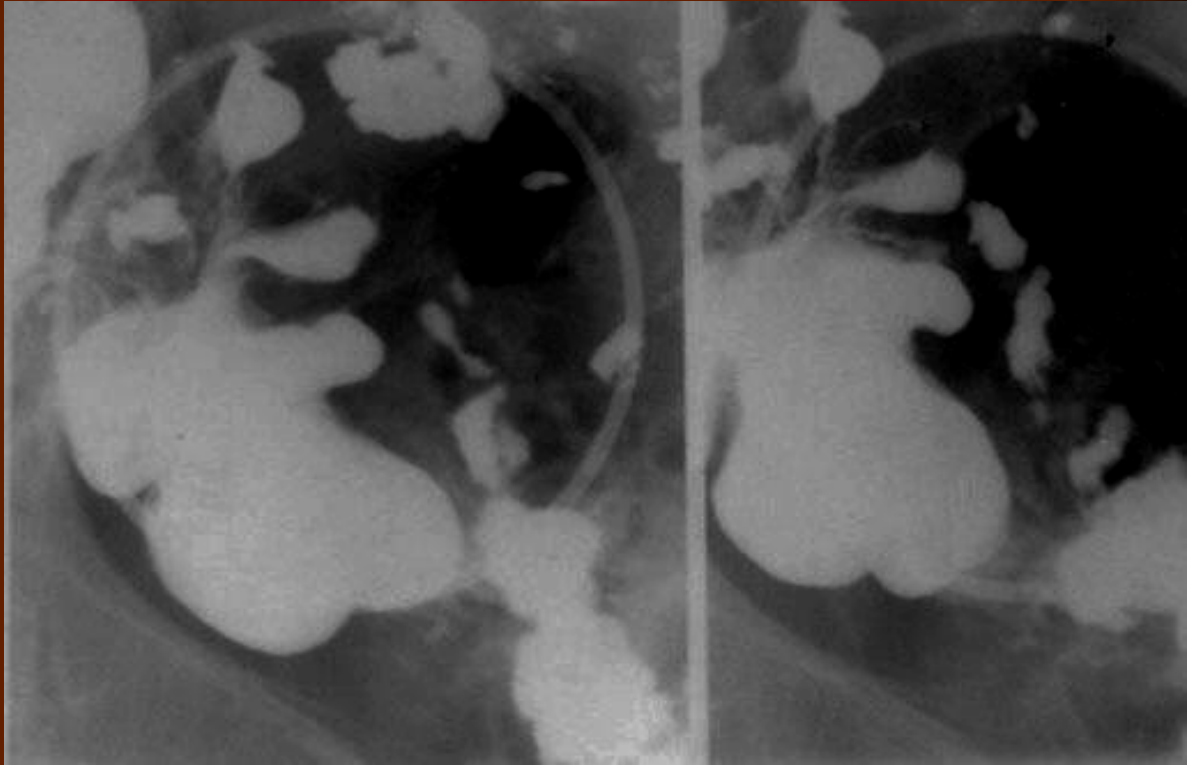
Enteroclisma



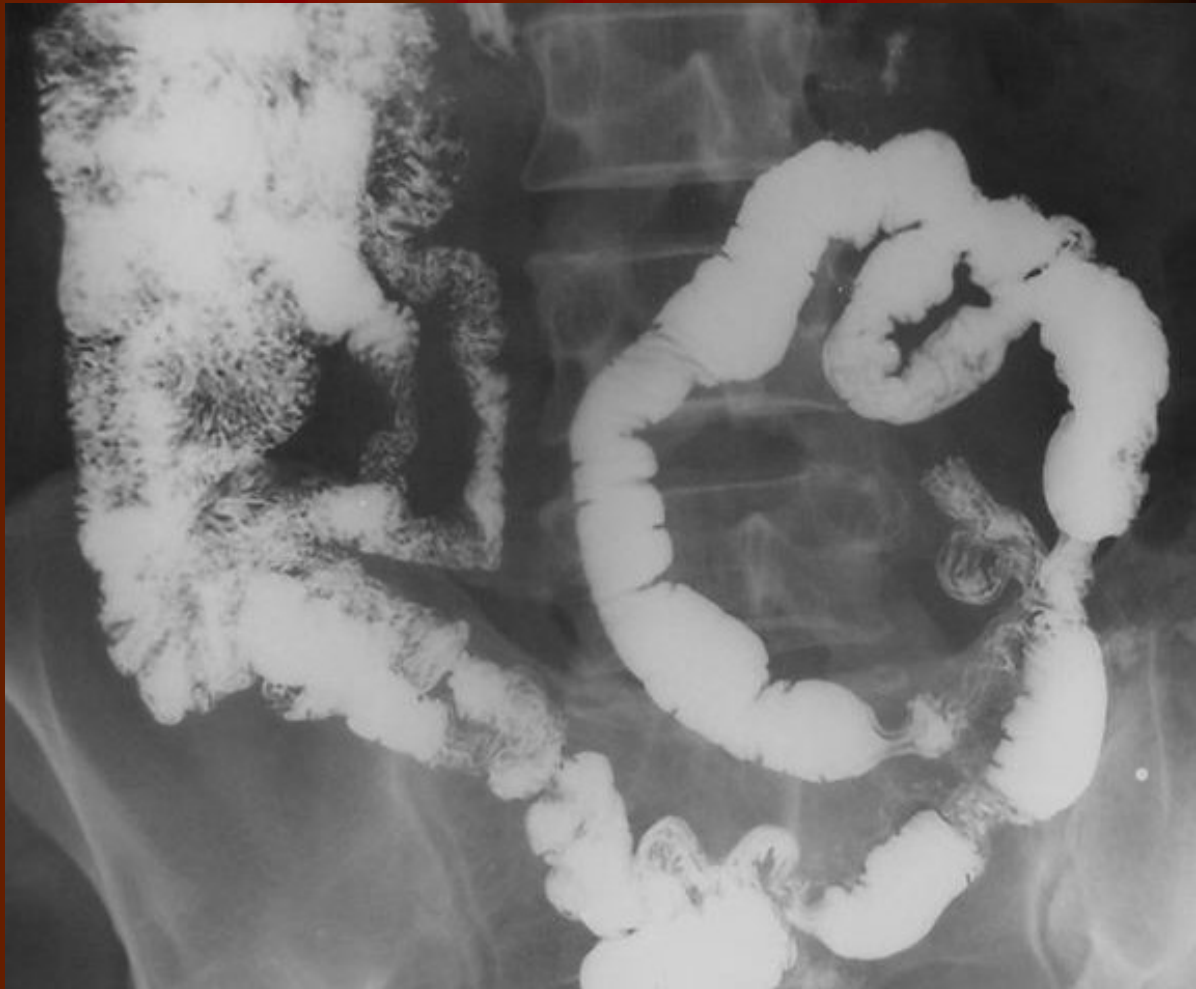Enterită



Enterită

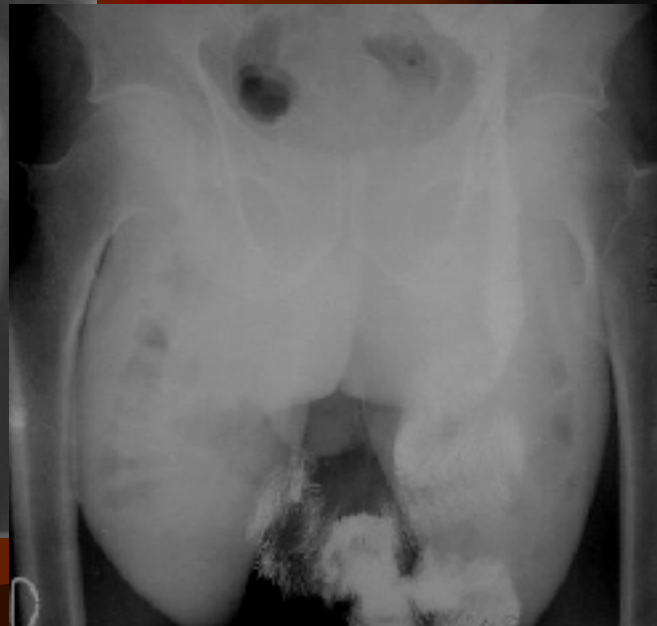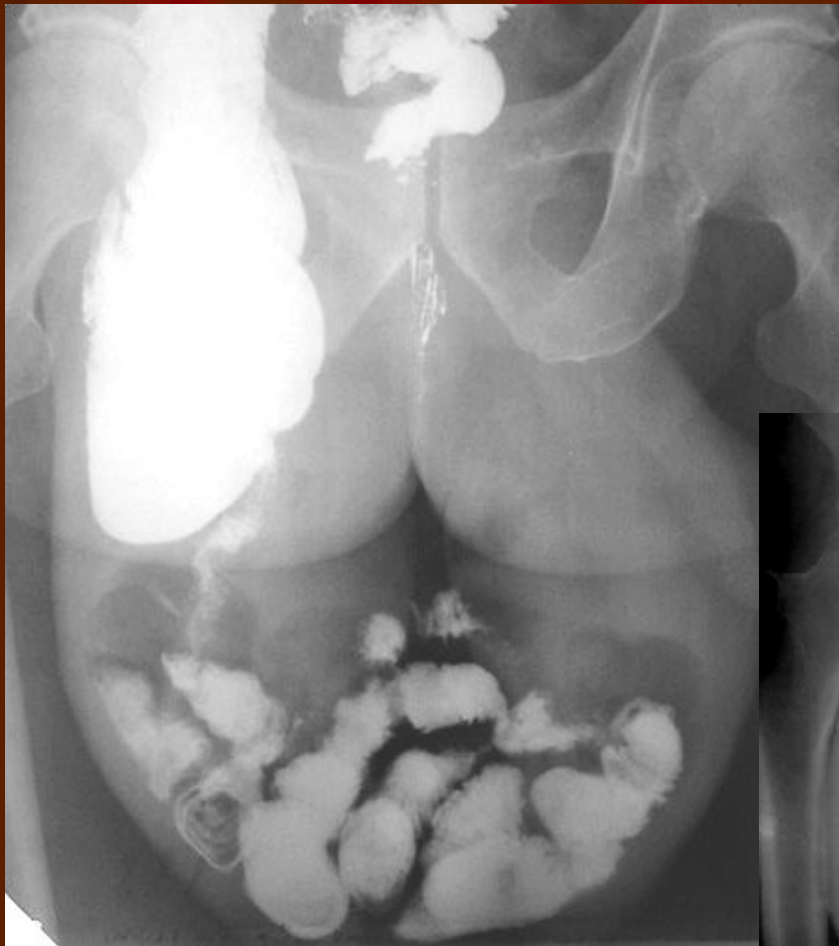


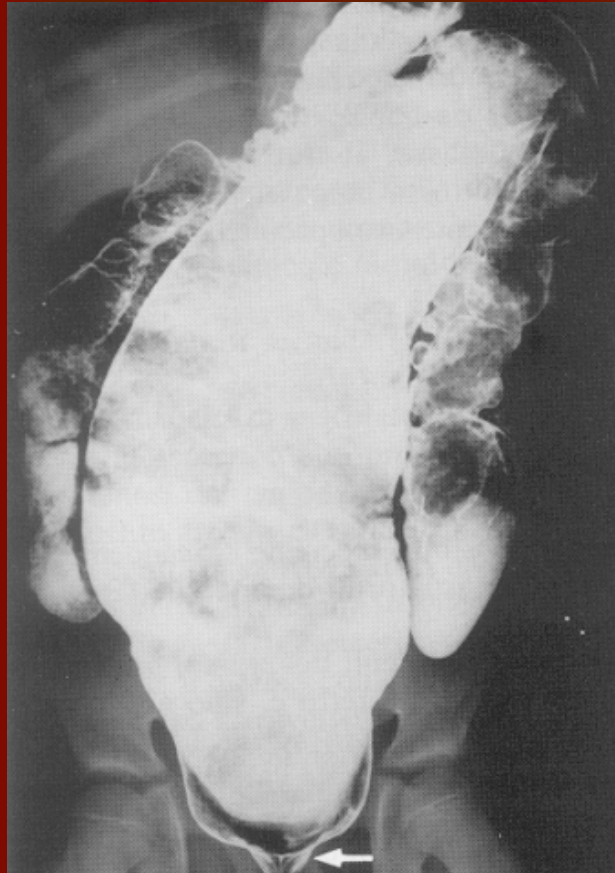Ileita terminala



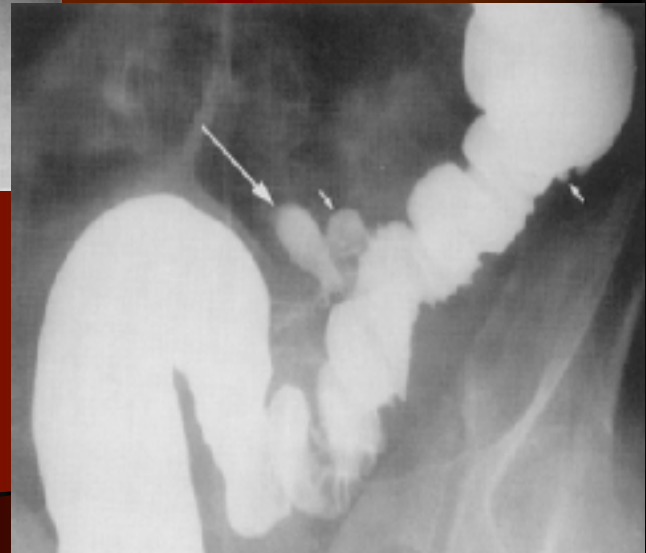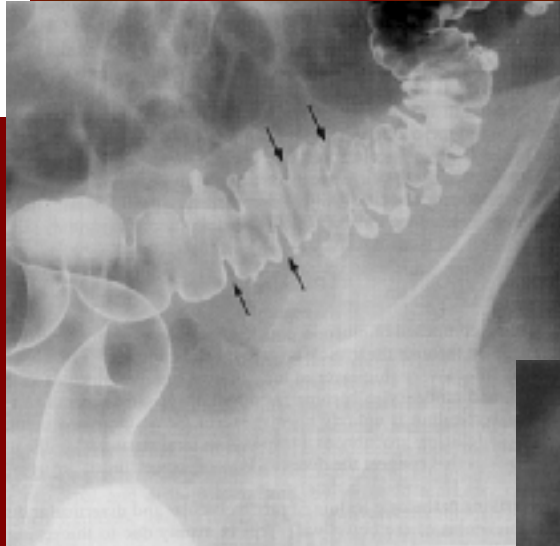Mezenter comun

Hernie inghino-scrotală

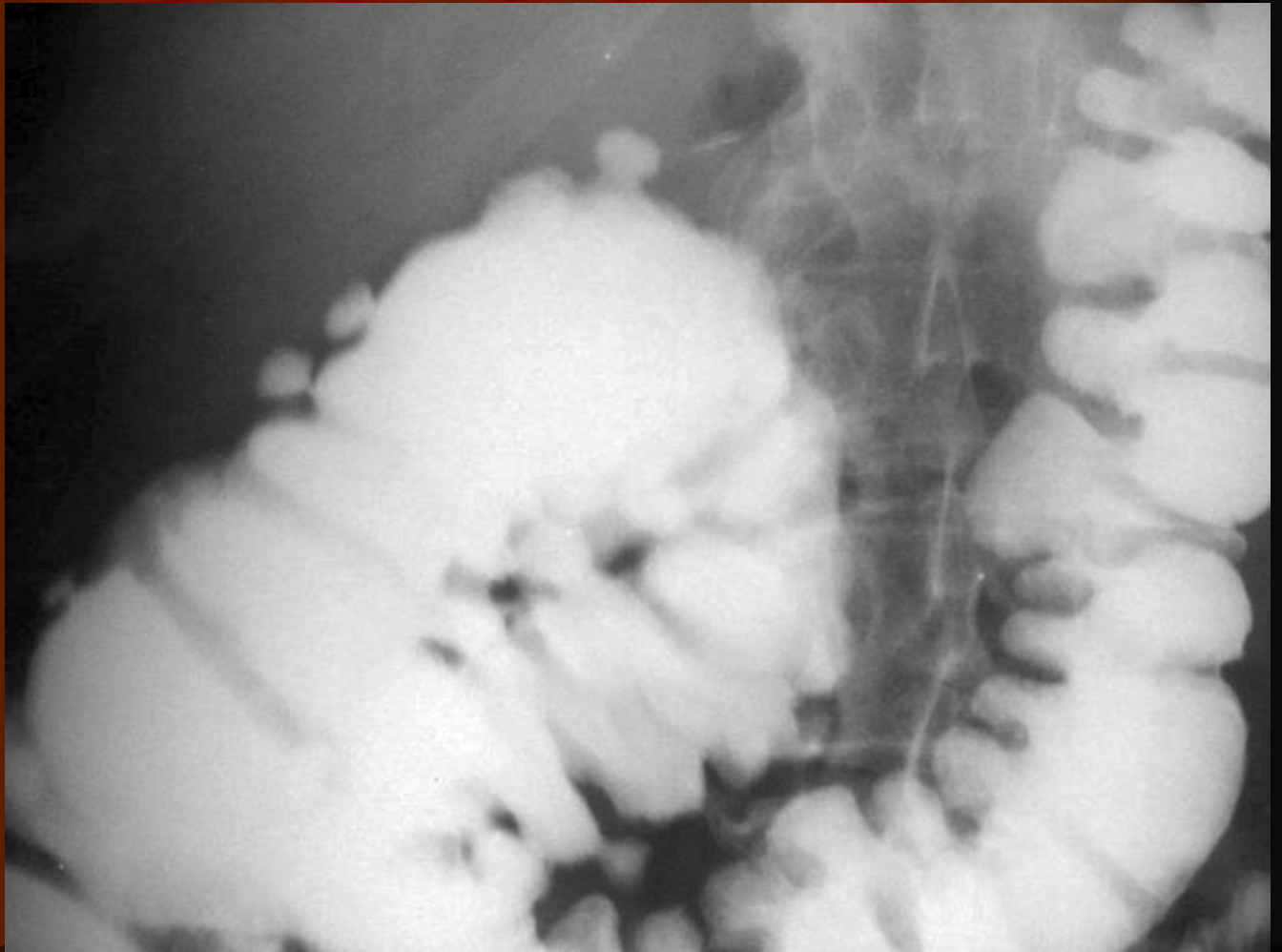



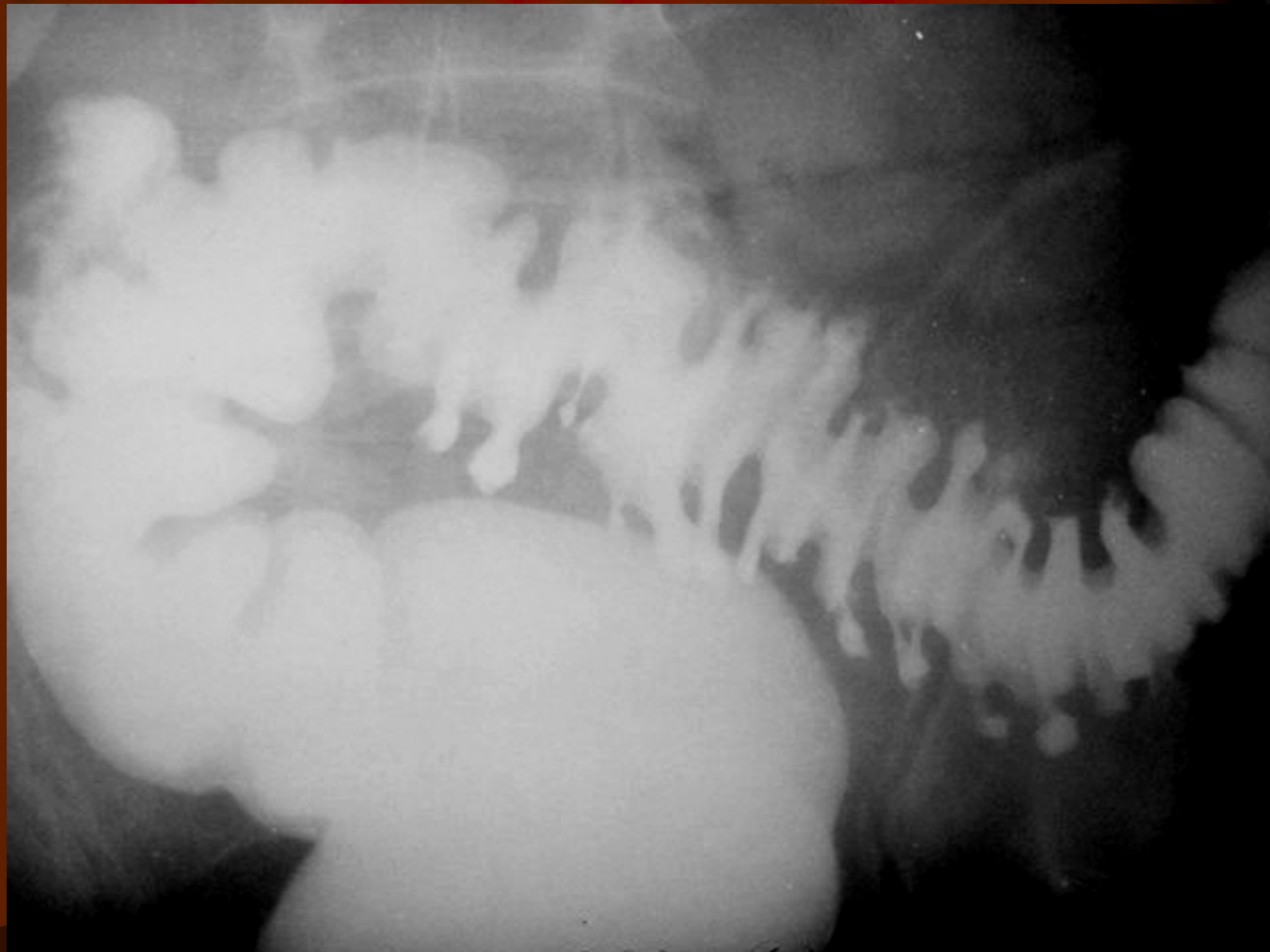
Megacolonul congenital



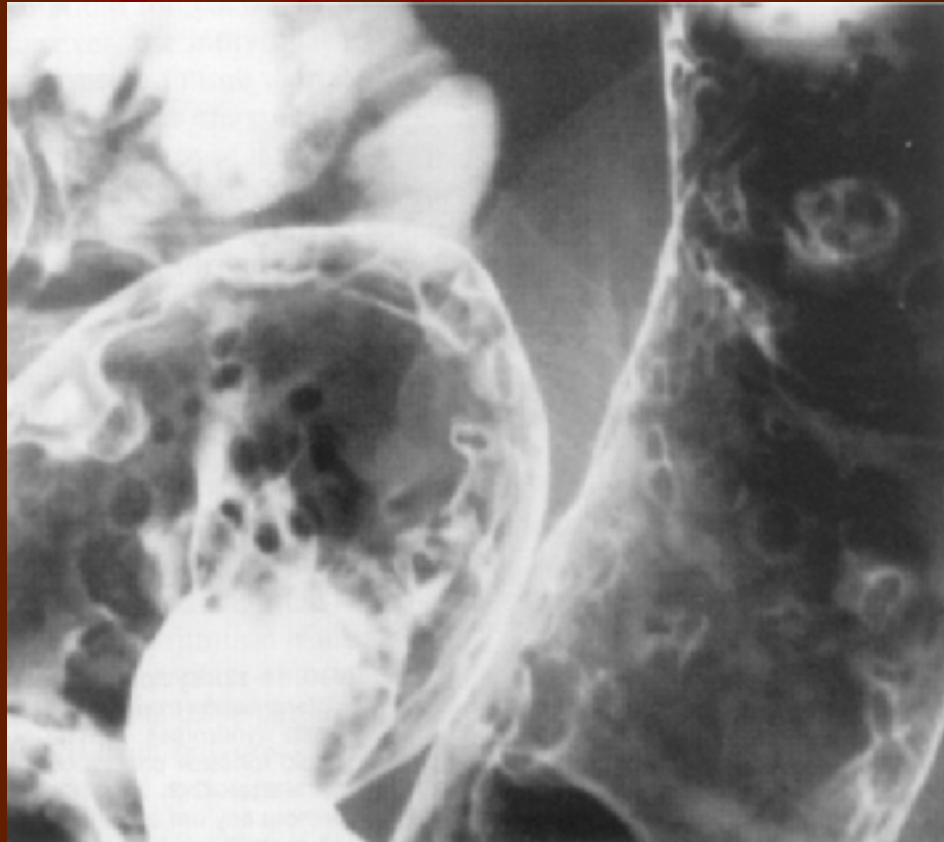Diverticolii colonului



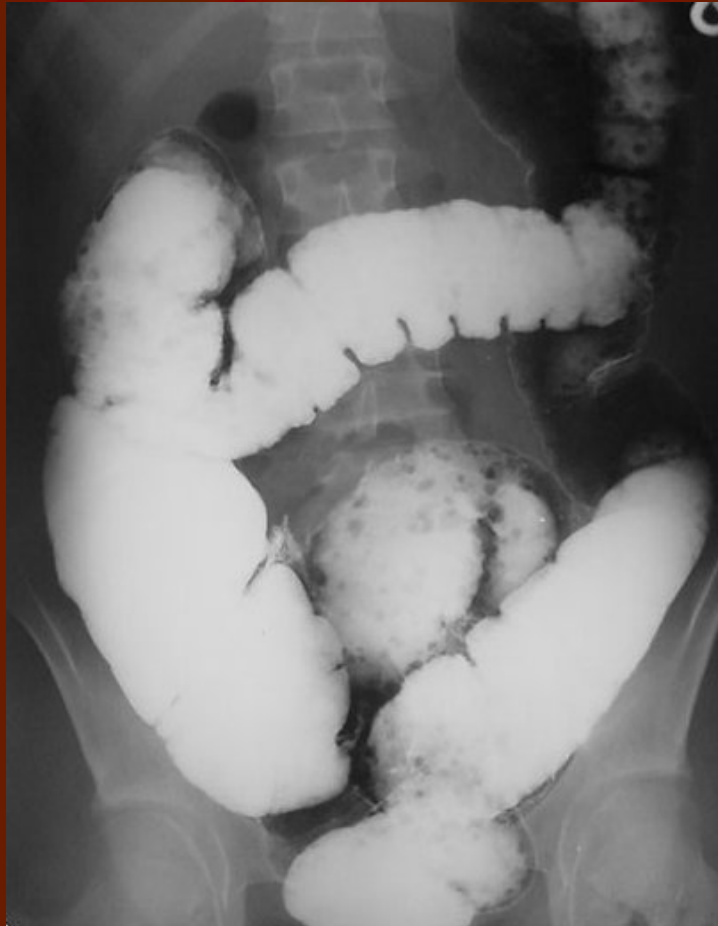
Diverticolii colonului



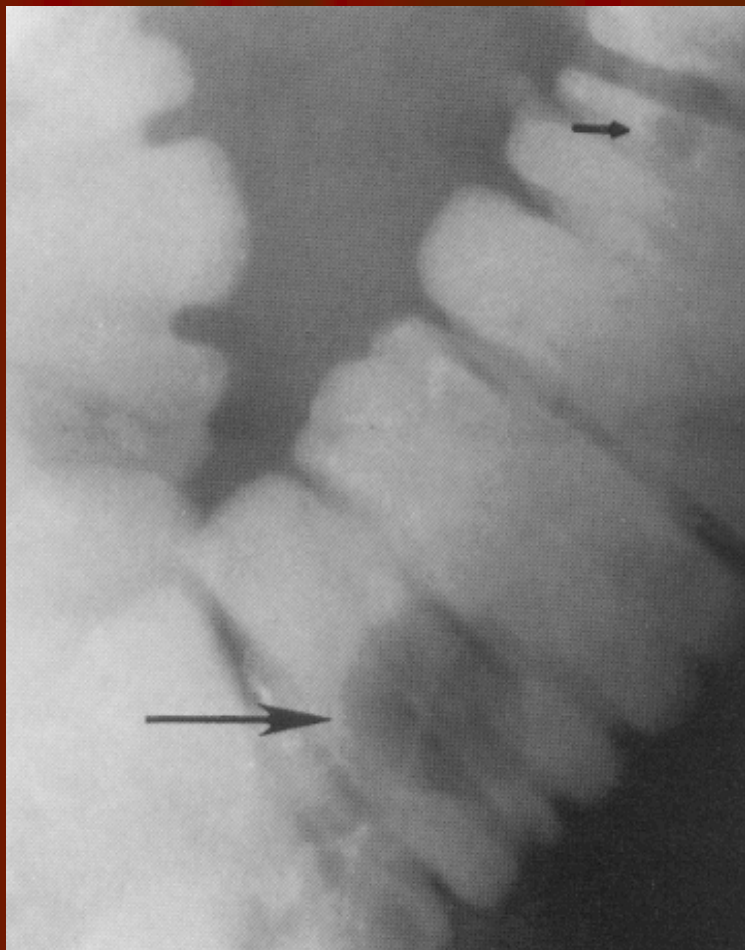

Diverticolii colonului



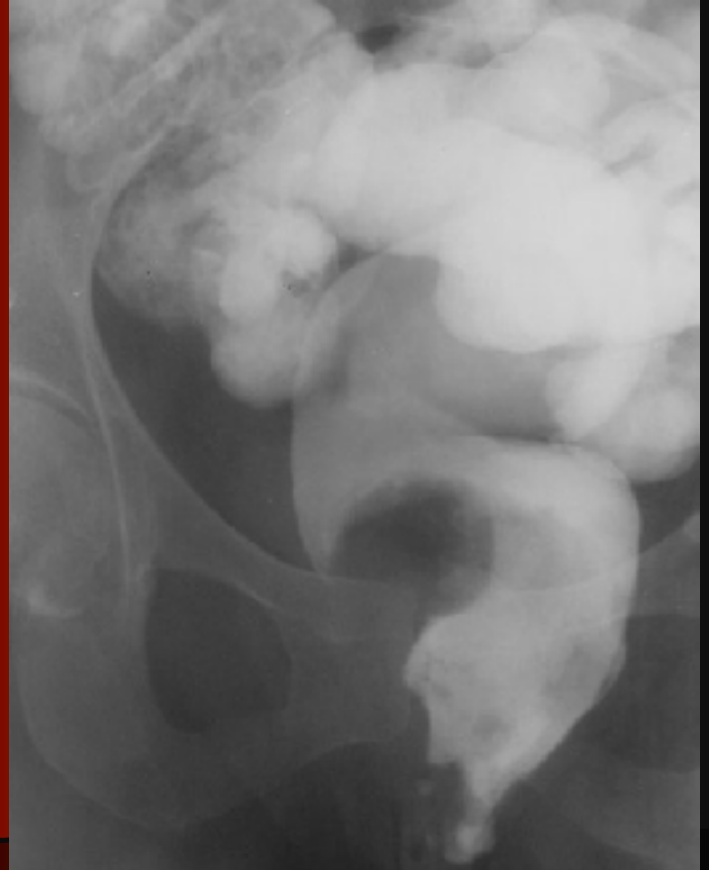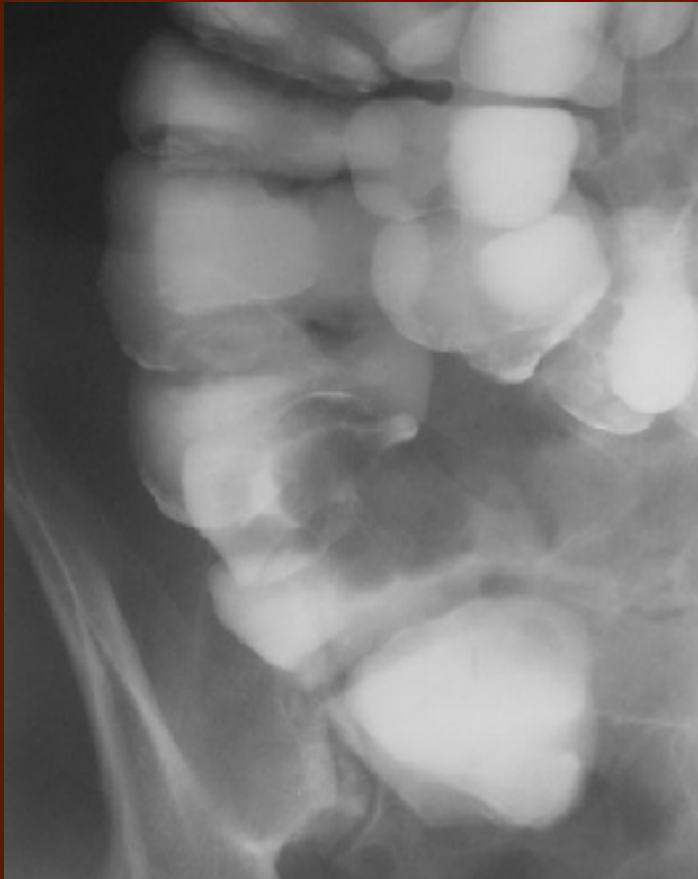
Polipoza colică



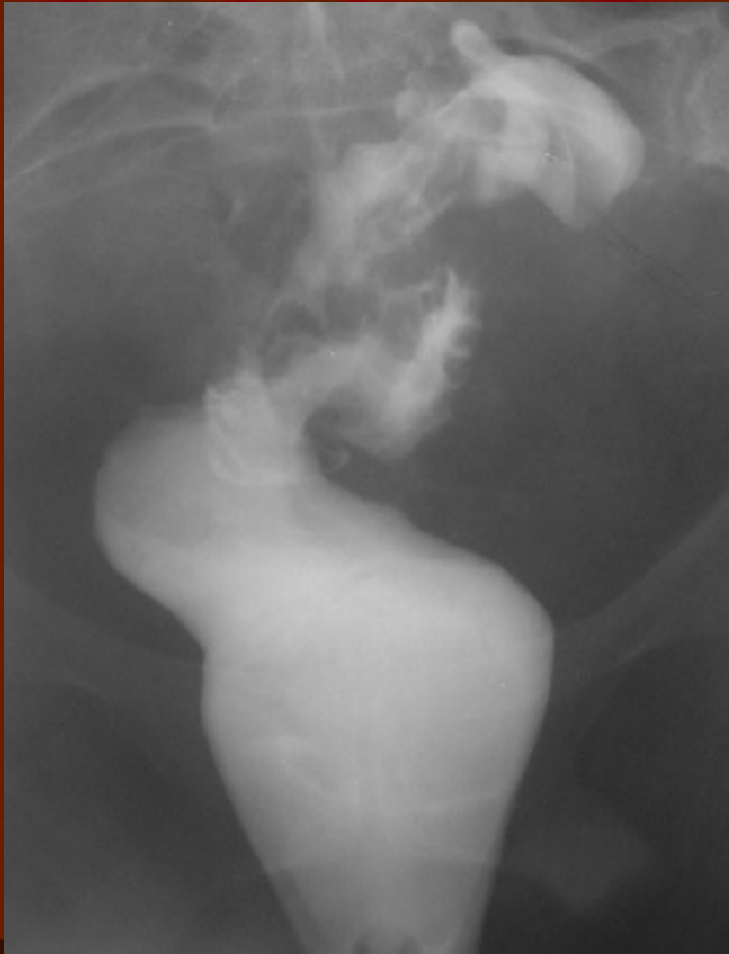Polipoza colică



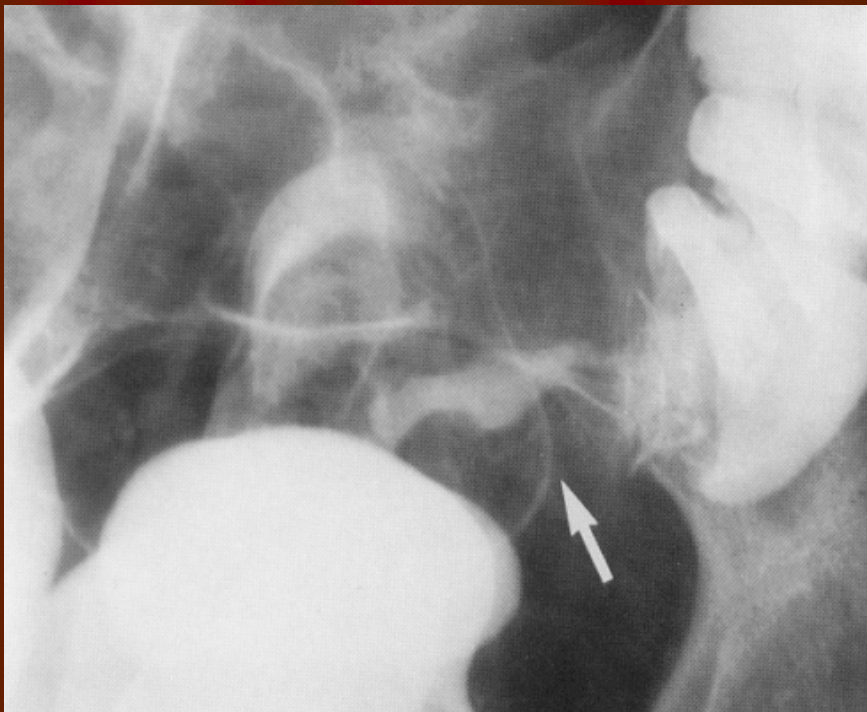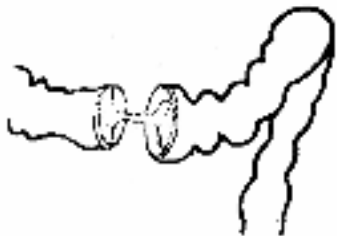
Cancer colic vegetant



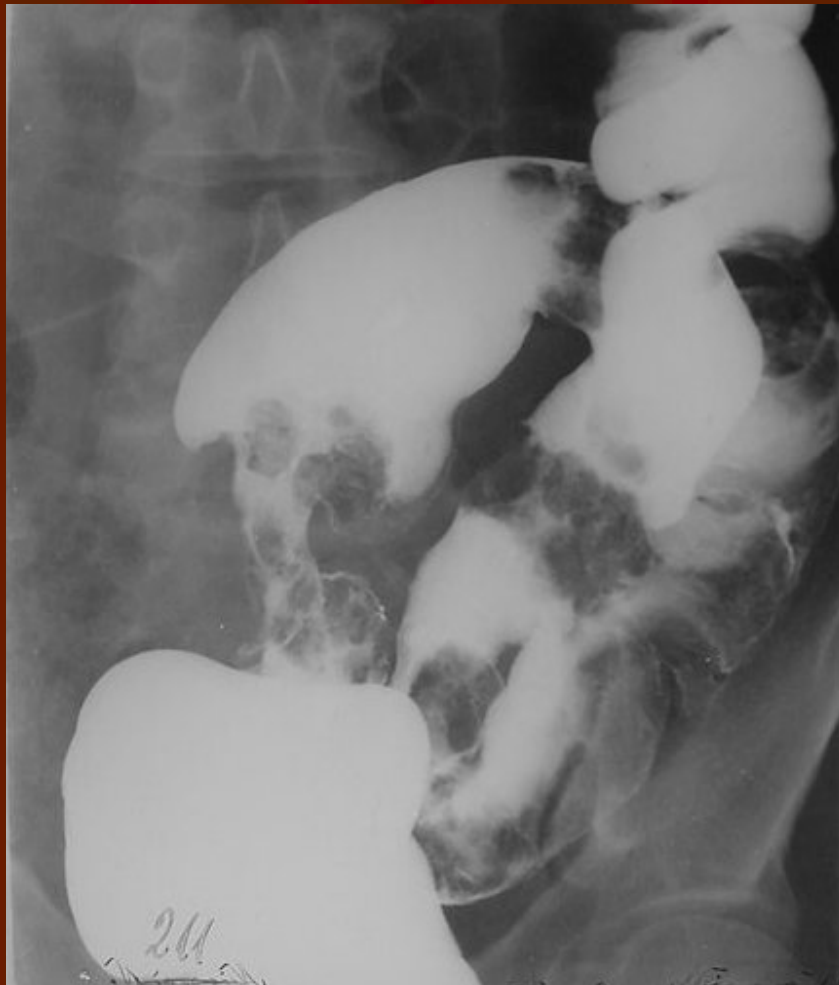
Cancer colic vegetant



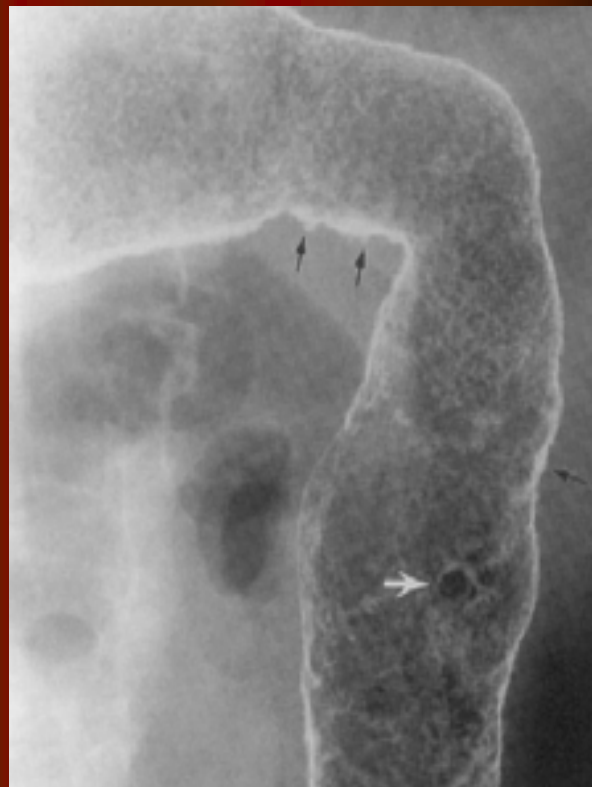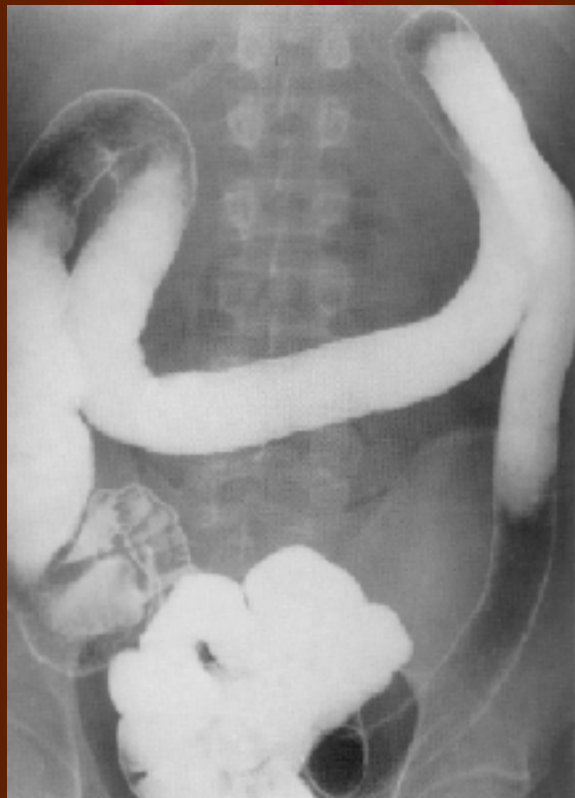Cancer colic ulcero-vegetant



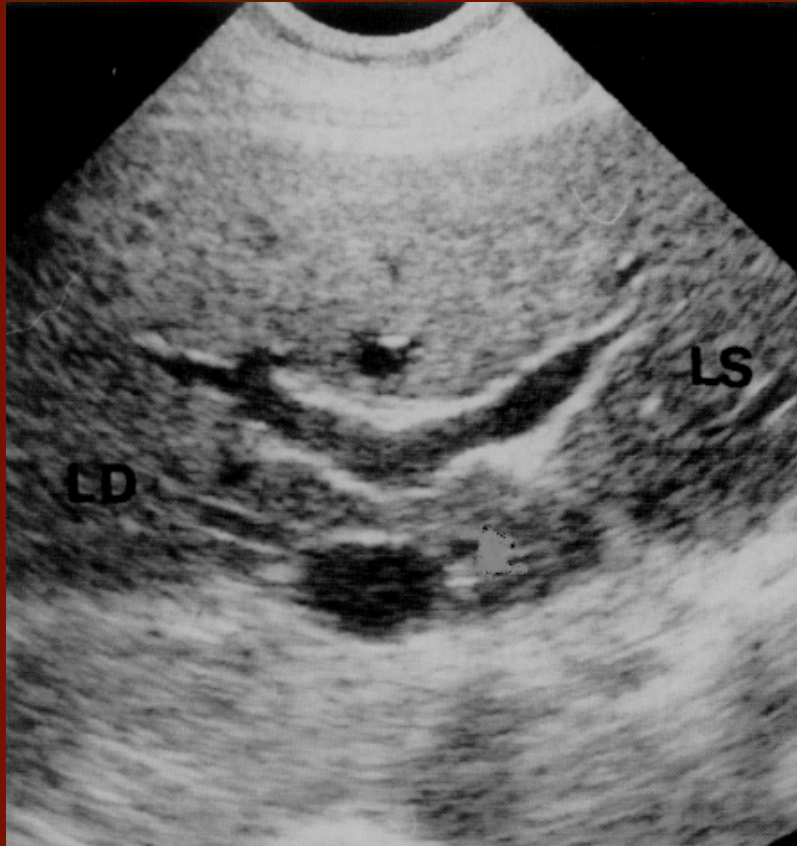Cancer colic infiltrativ



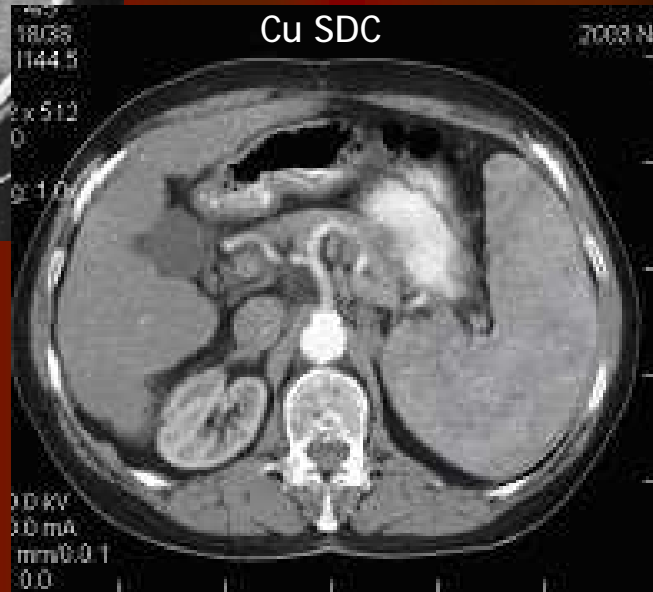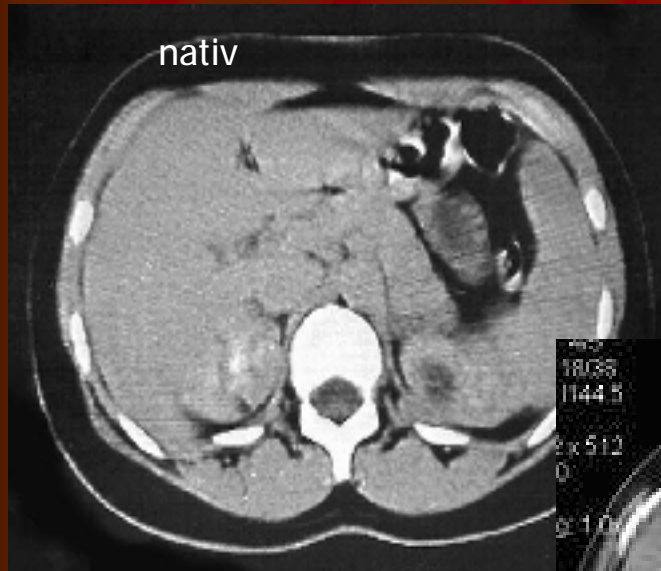
Cancer colic infiltrativ



Aspectul radiologic în colita ulcero-hemoragică

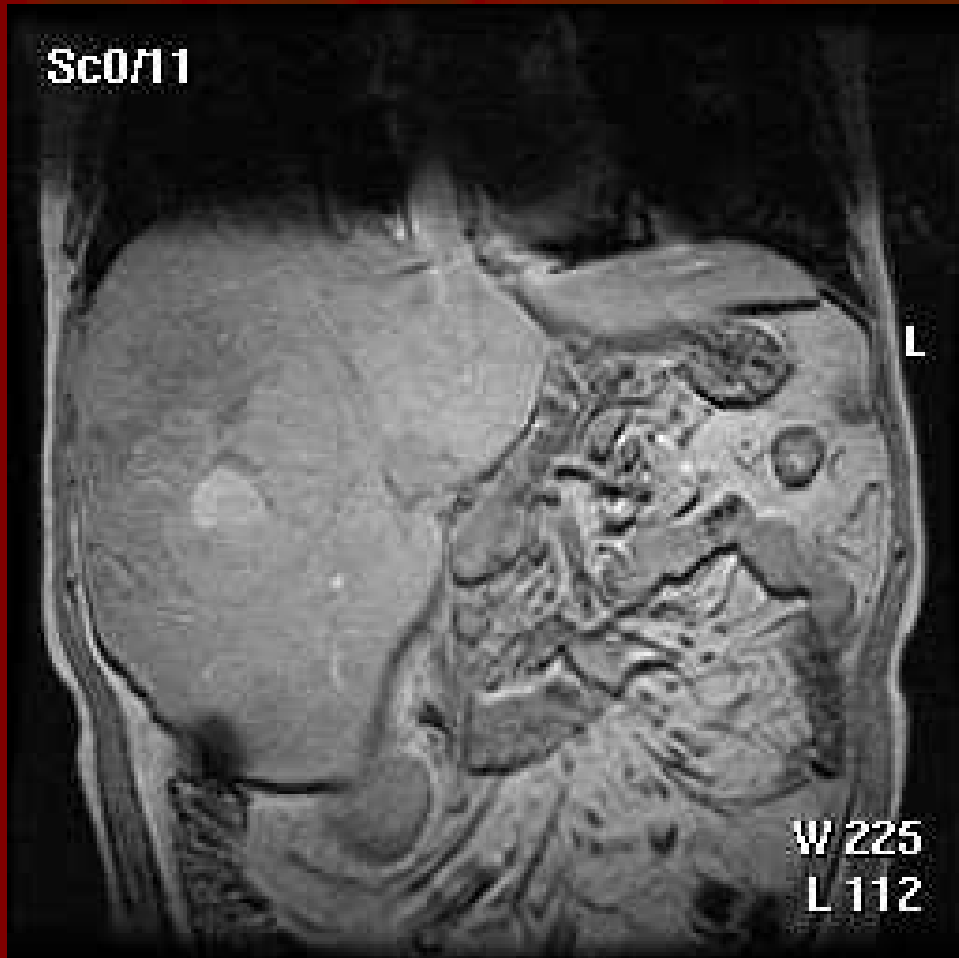

Aspect normal echografic hepatic



Computertomografia hepatică

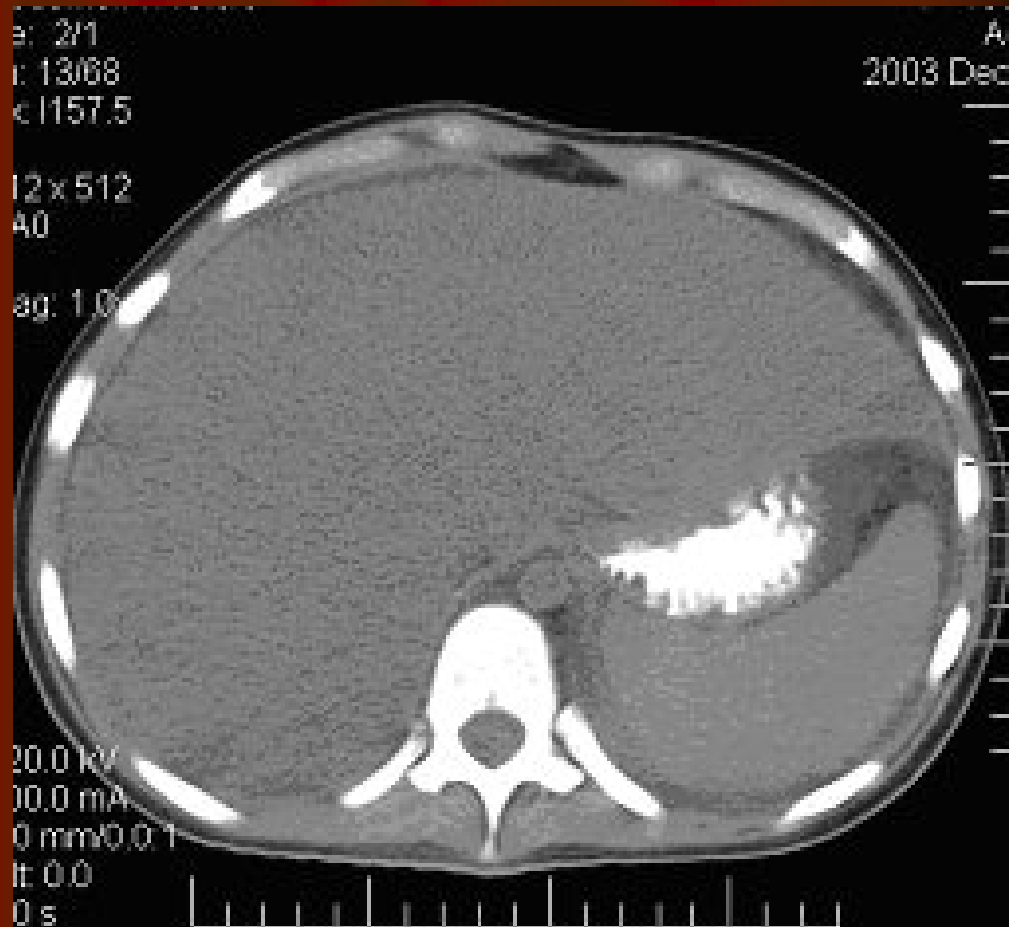Sc0/11



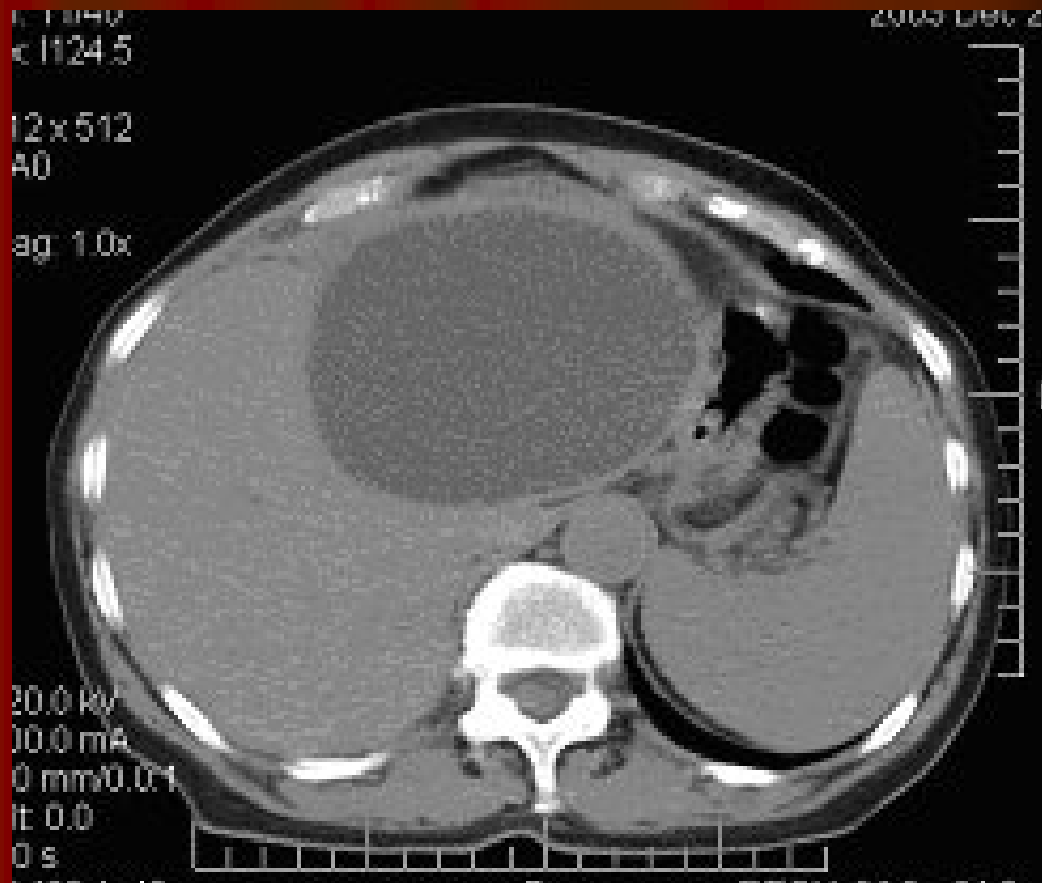L

W 225
L 112

Imagistica ficatului prin IRM

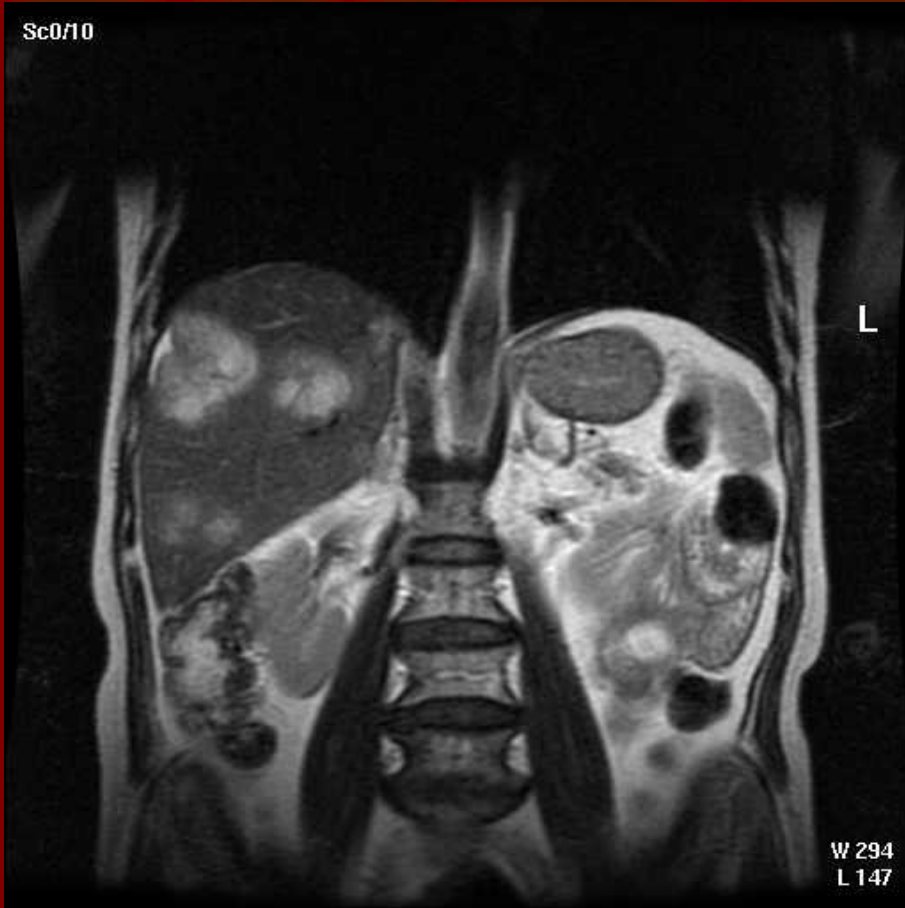

Ciroza hepatică -CT



Chist hidatic hepatic-CT

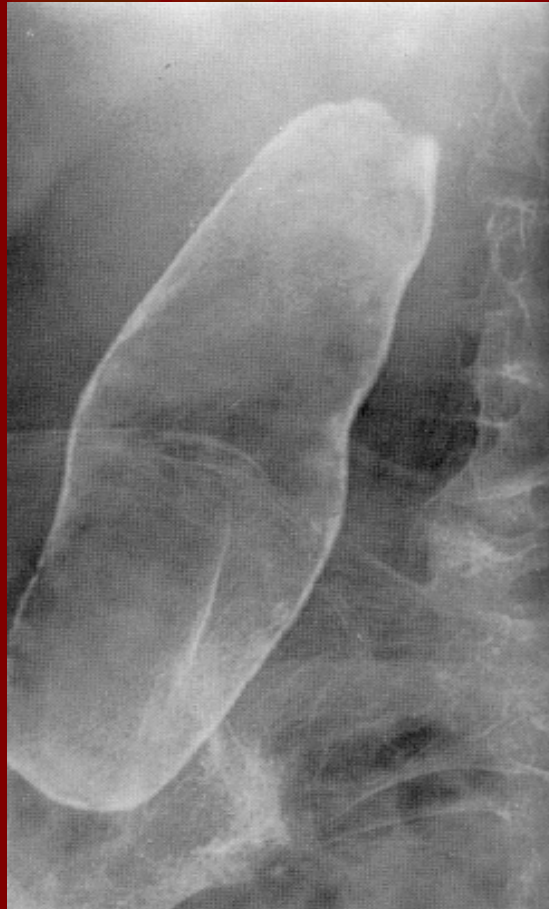Sc0/10



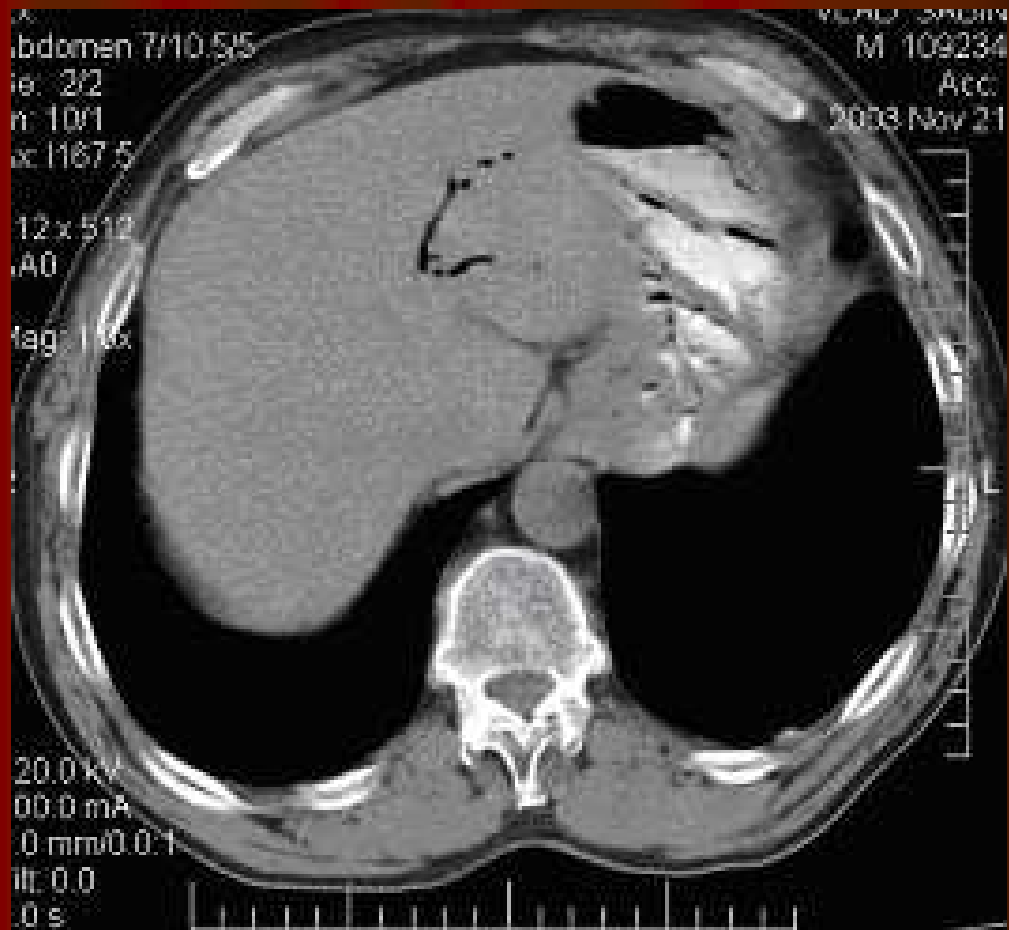L

W 294
L 147

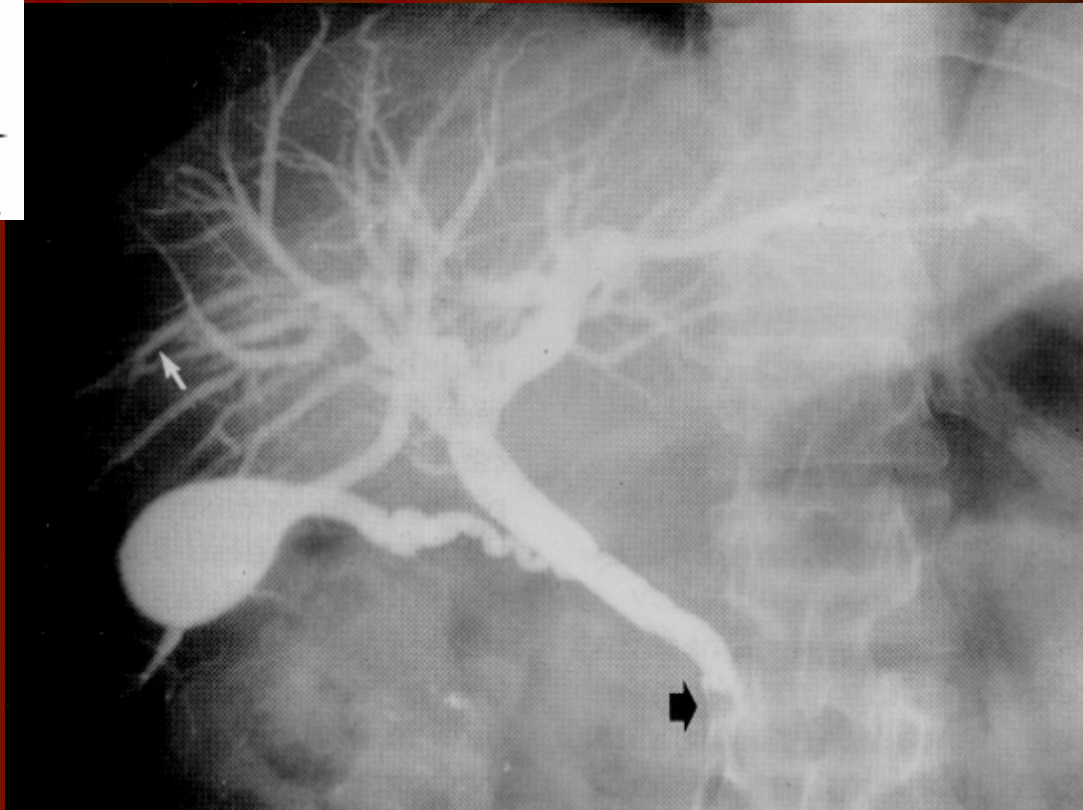
Metastaze hepaticae-aspect IRM



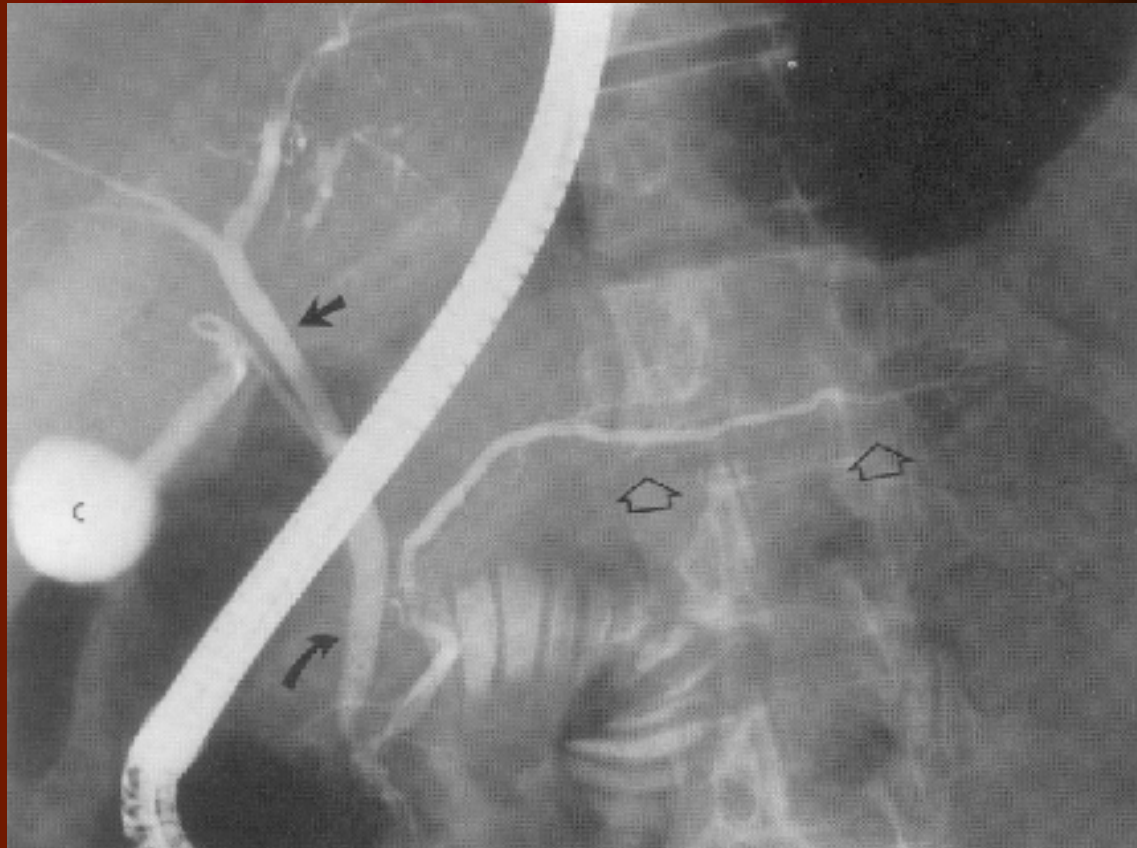Vezica de porțelan



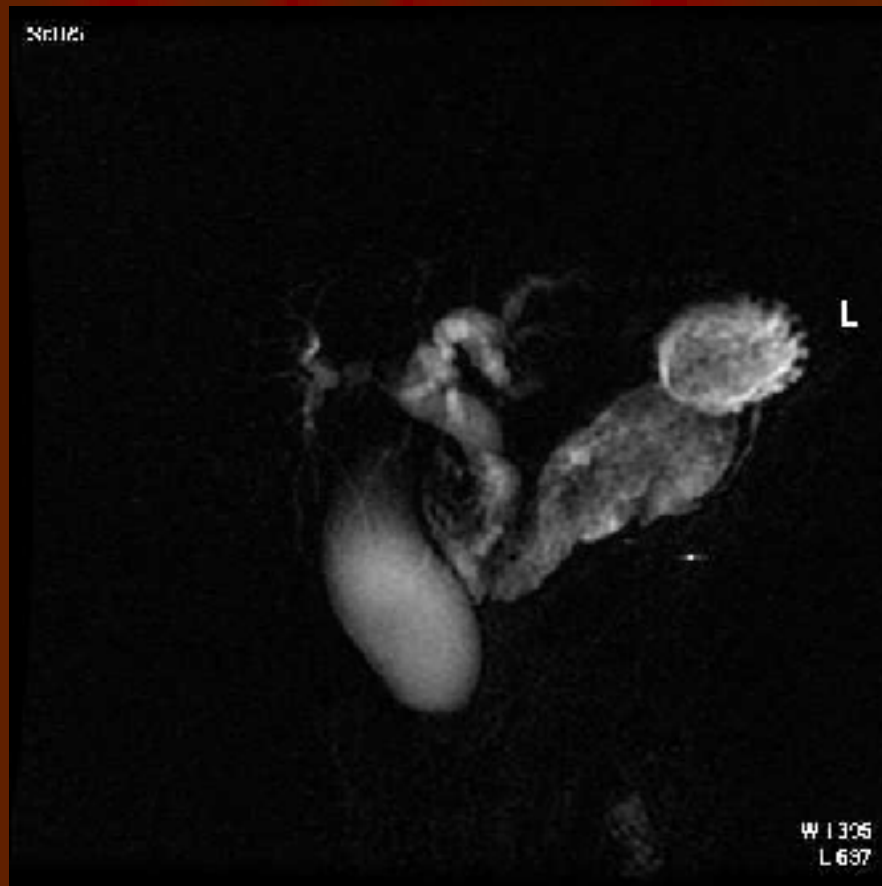Aerobilie CT



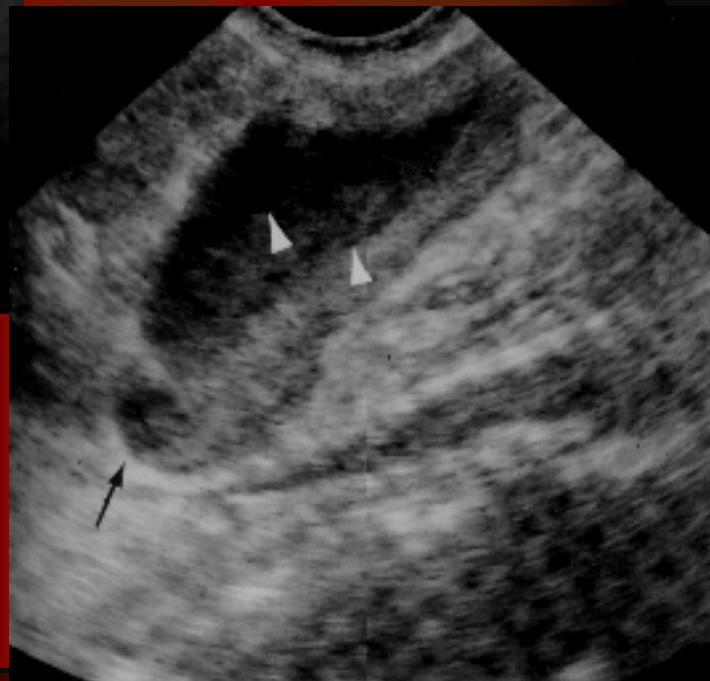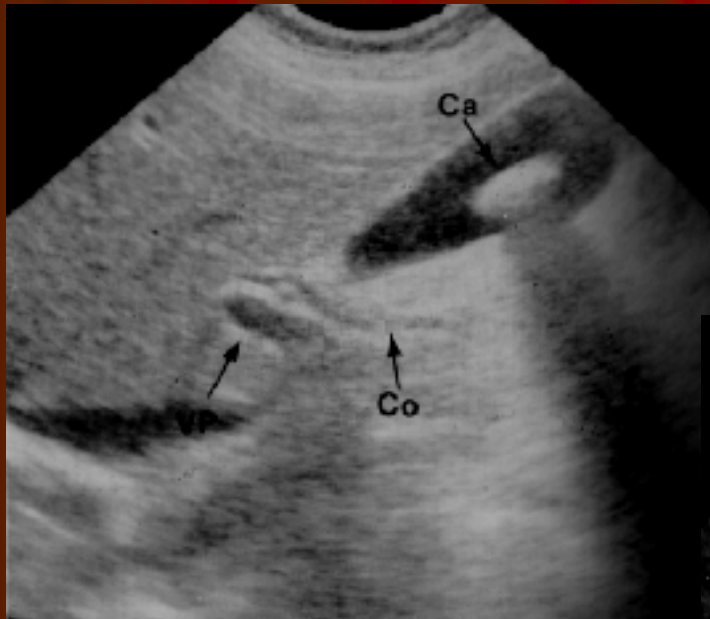Colangiografia –obstrucție coledociană



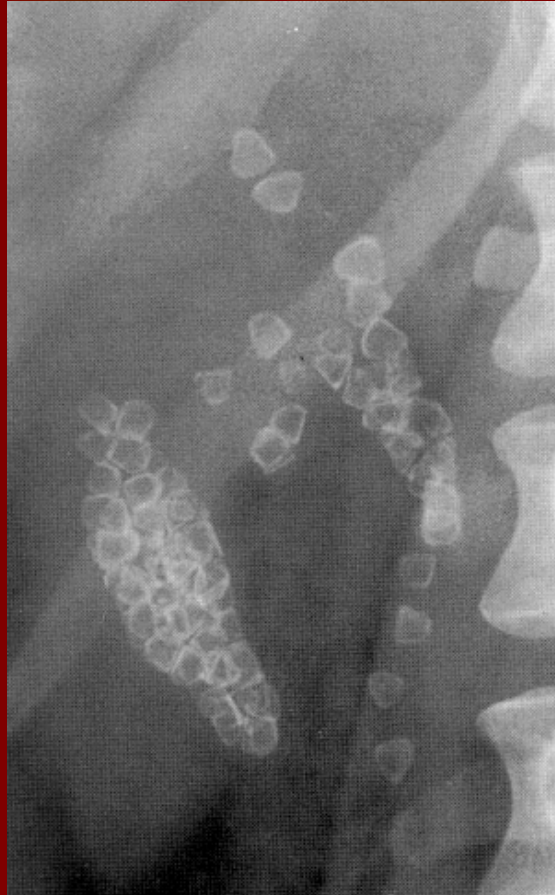
ERCP aspect normal –hepatic, cistic, vesicula,
Colecoc, Wirsung



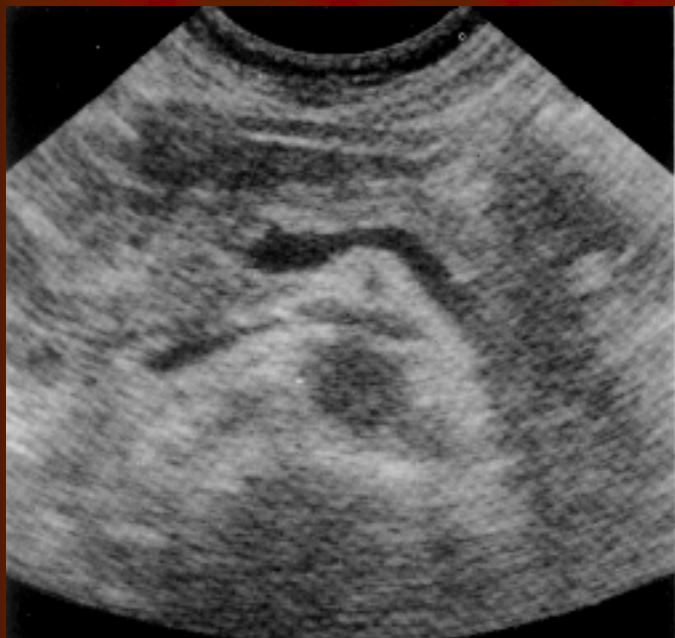
Colangio IRM



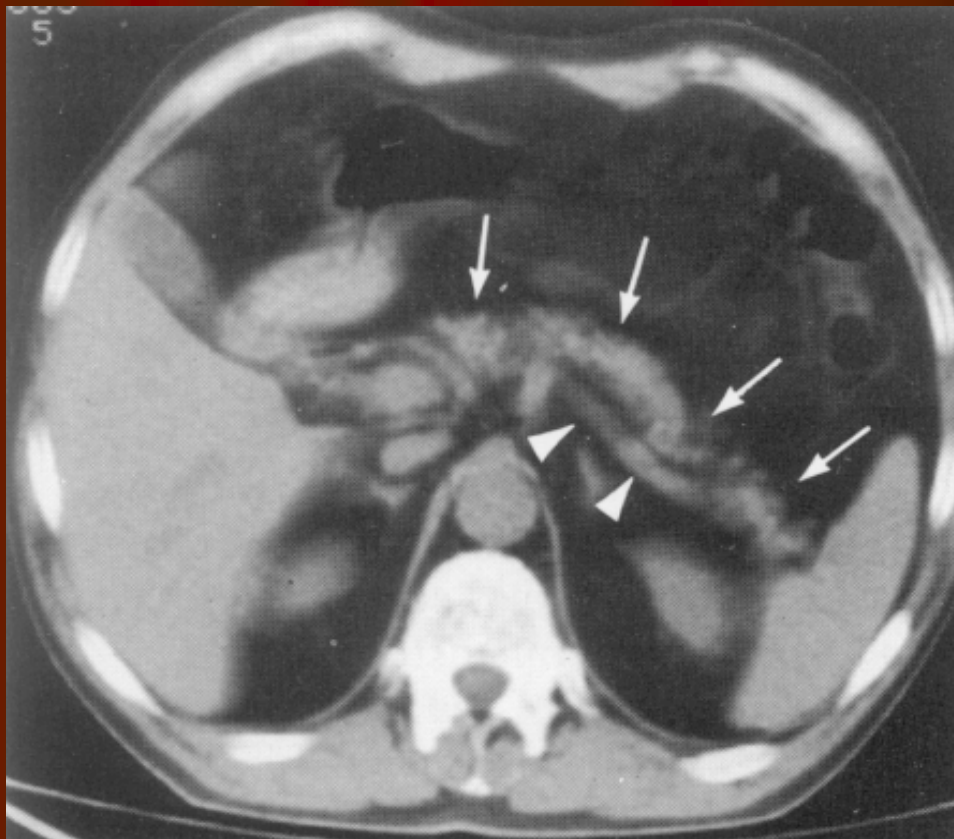
Ecografie-litiază veziculară
-sludge biliar



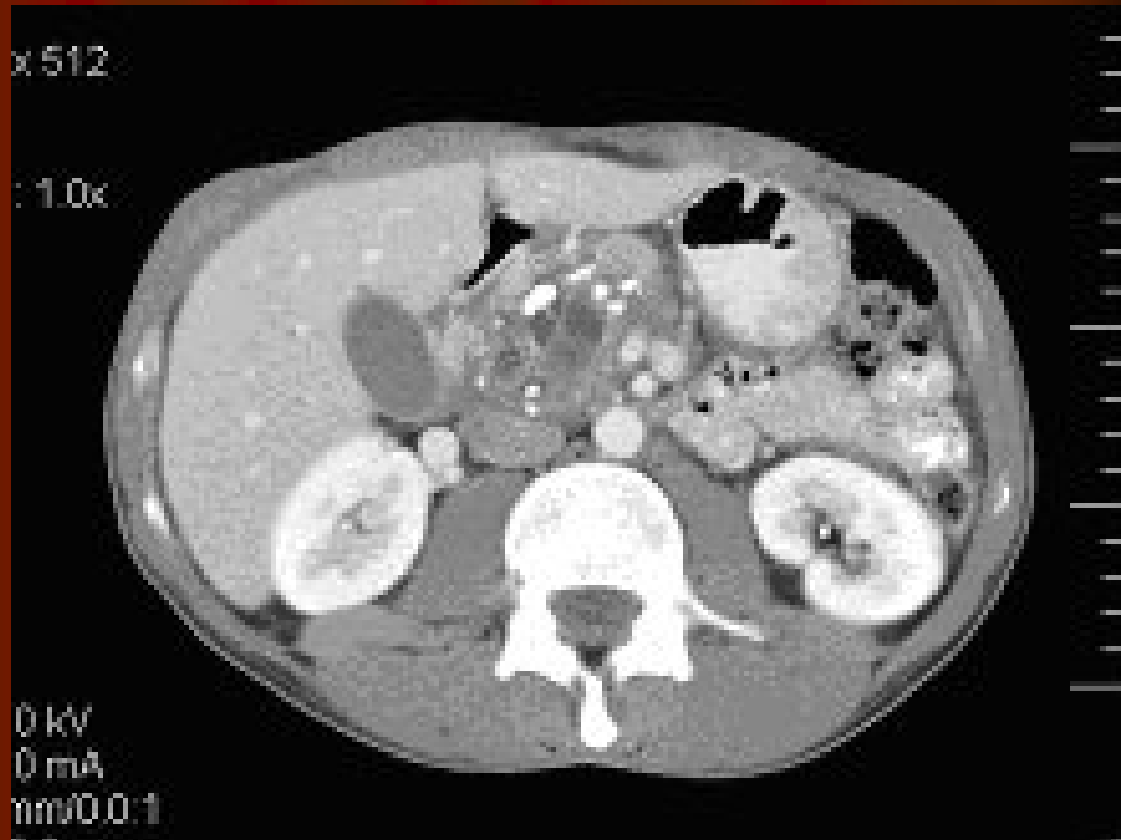Litiiza veziculară și coledociană



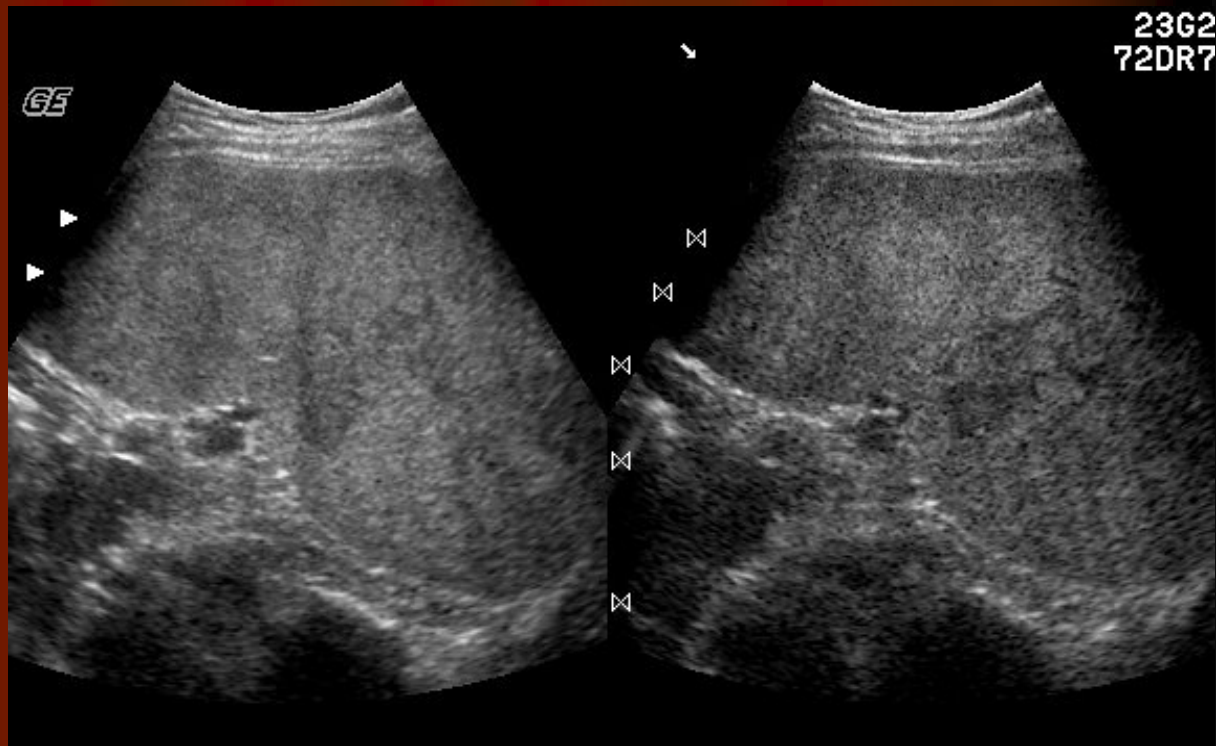Aspect normal ultrasonografic al pancreasului



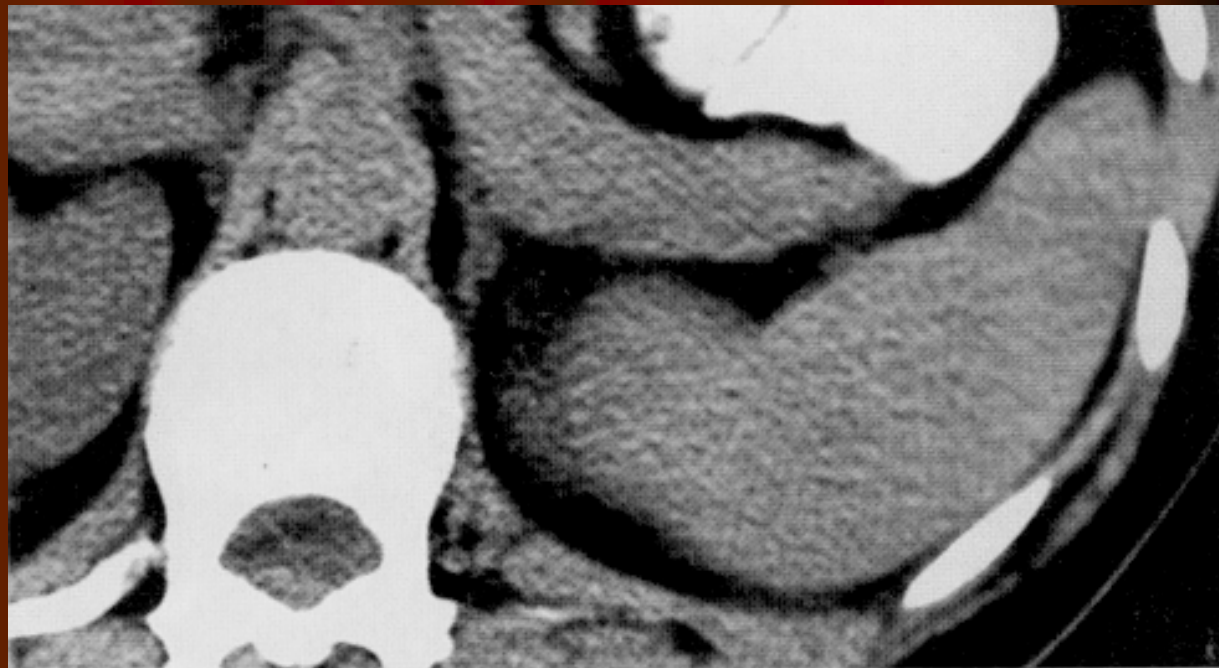
Imaginea computer tomografică a pancreasului



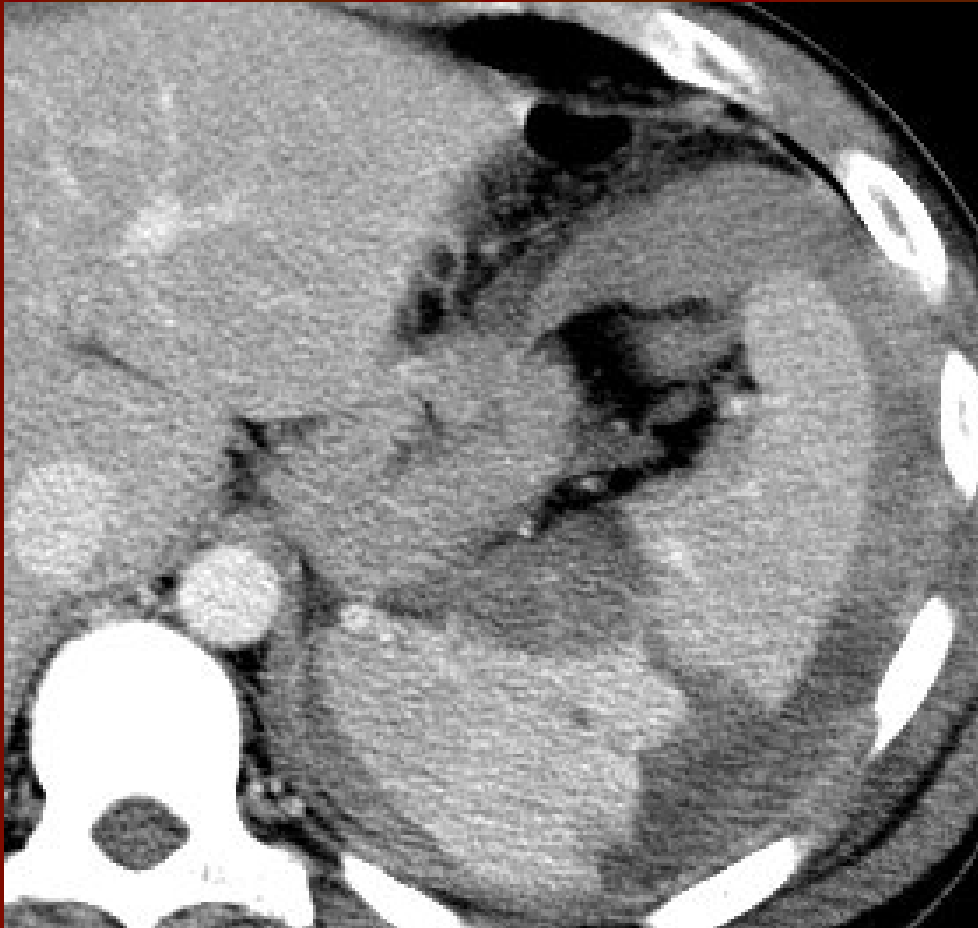Pancreatita cronică



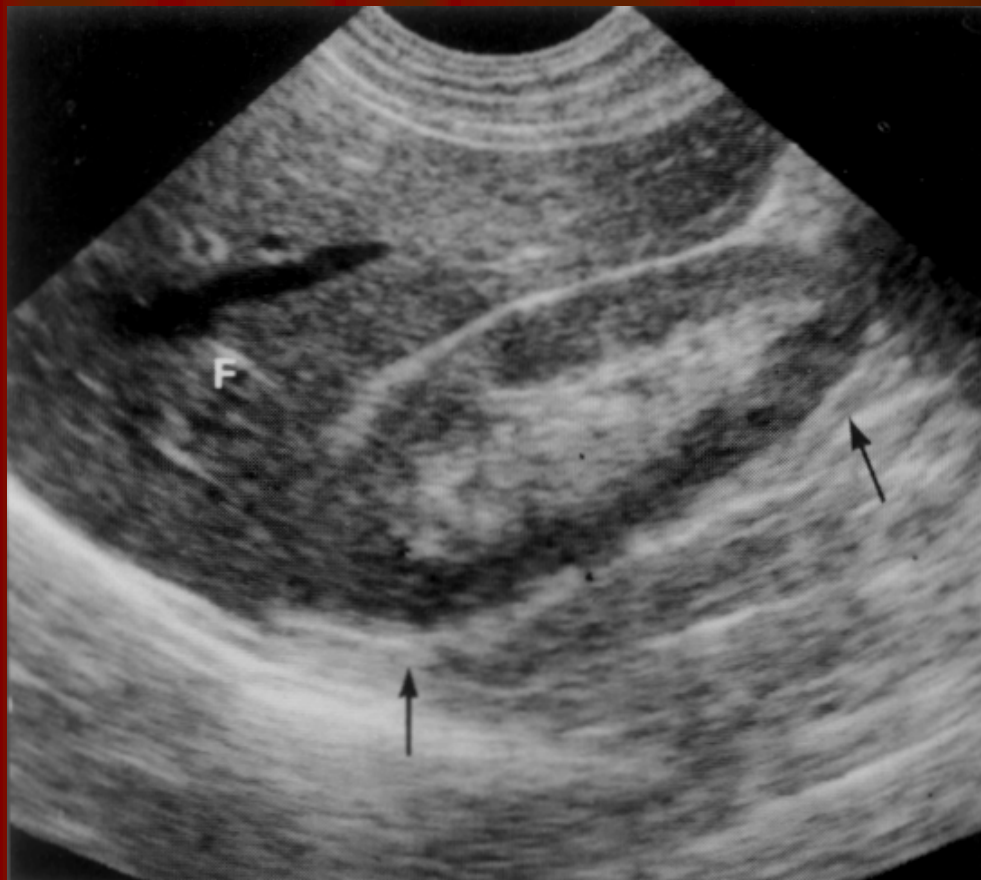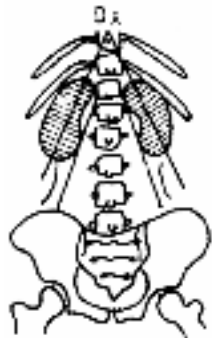Ecografie normală splină



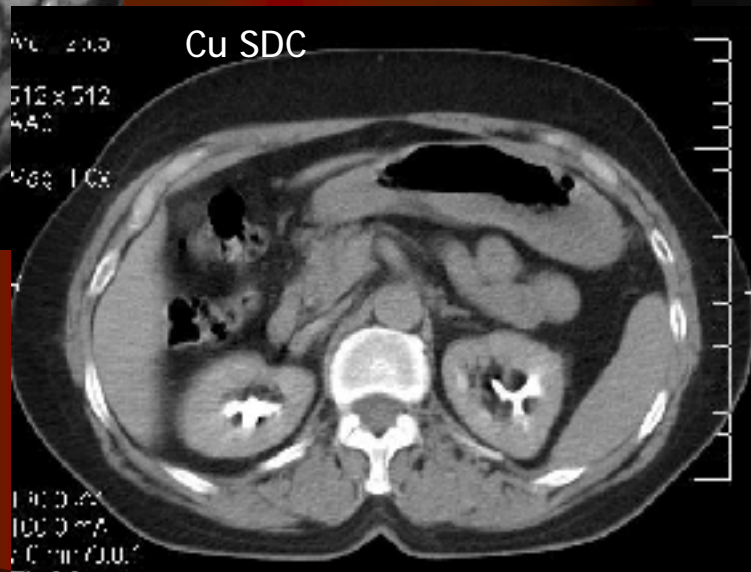
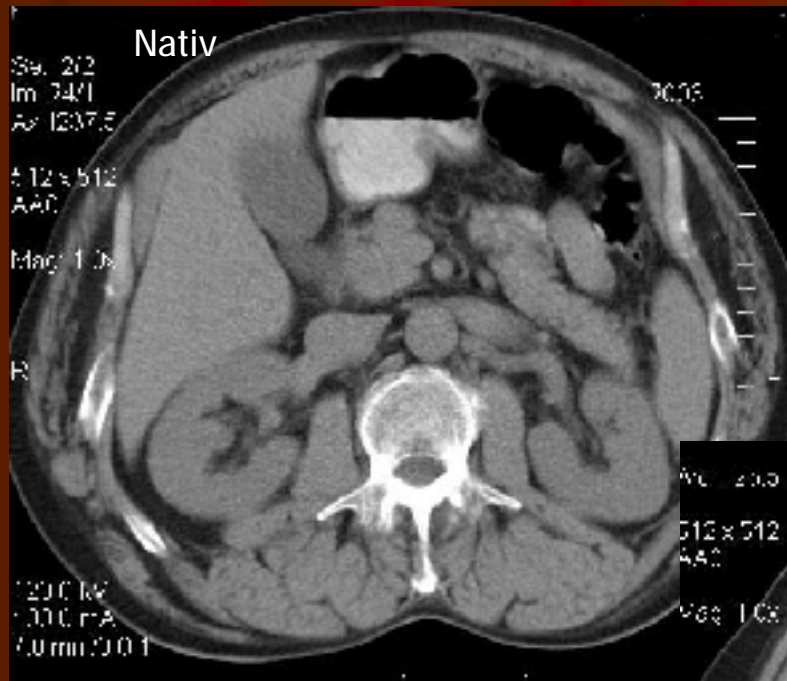
Tomografie computerizată –splina



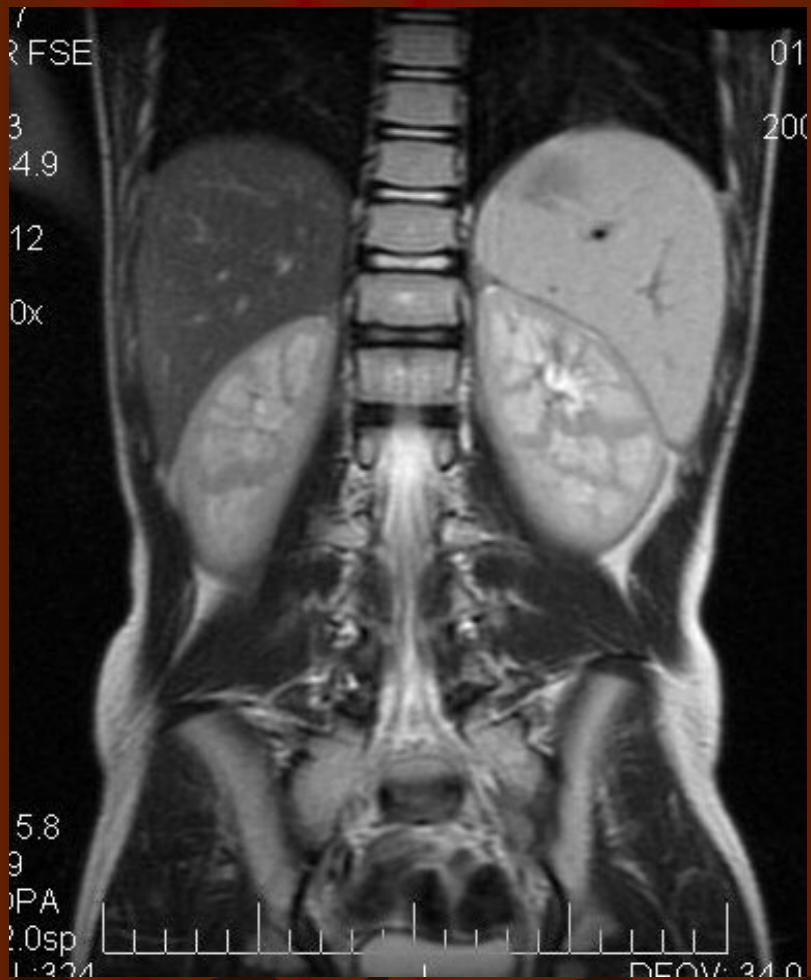Laceratija splenică CT



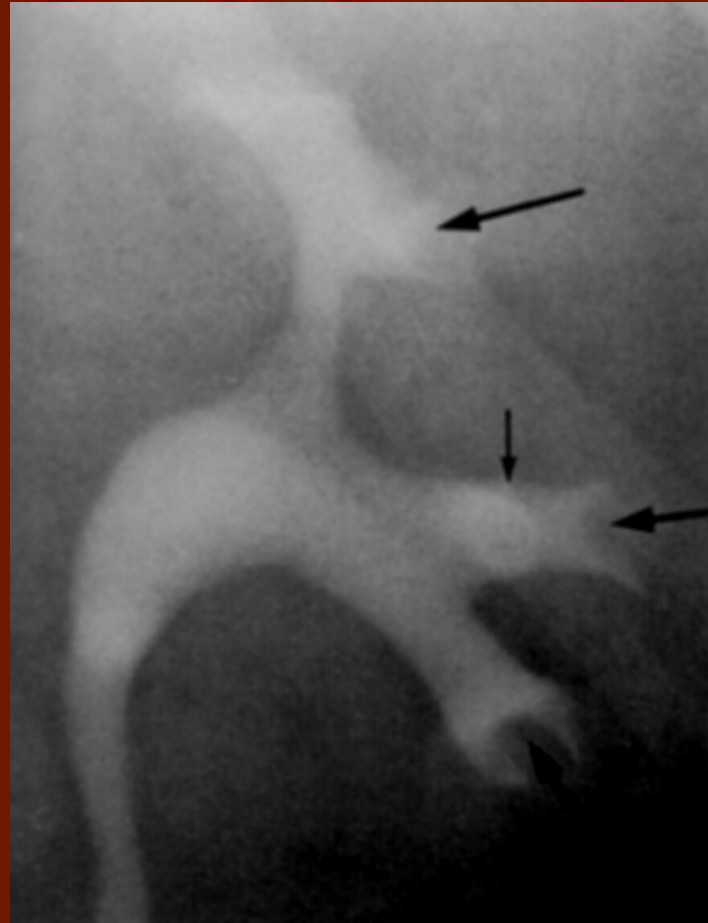
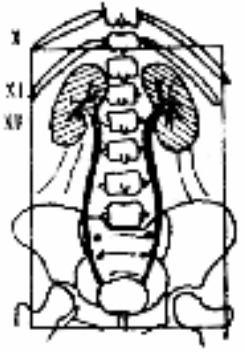
Ecografia renală



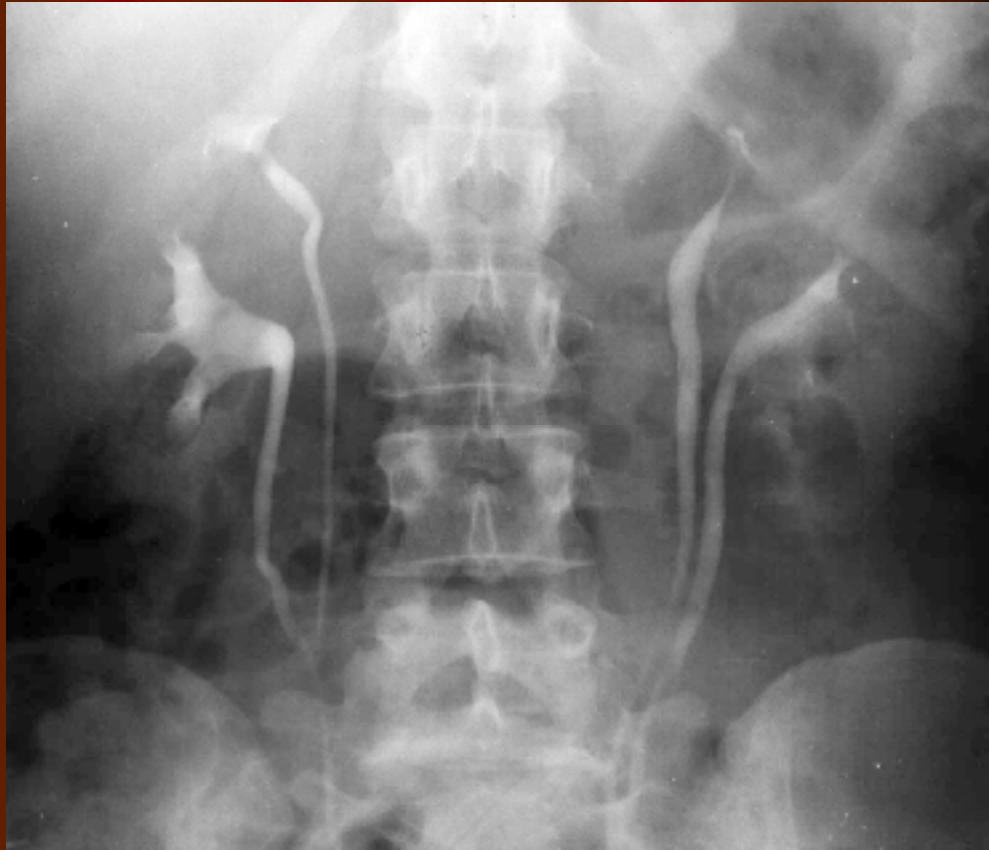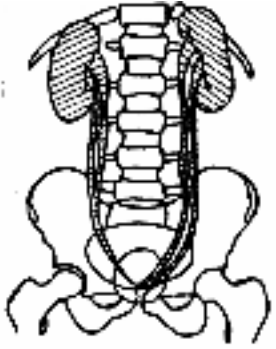
Computertomografia renală



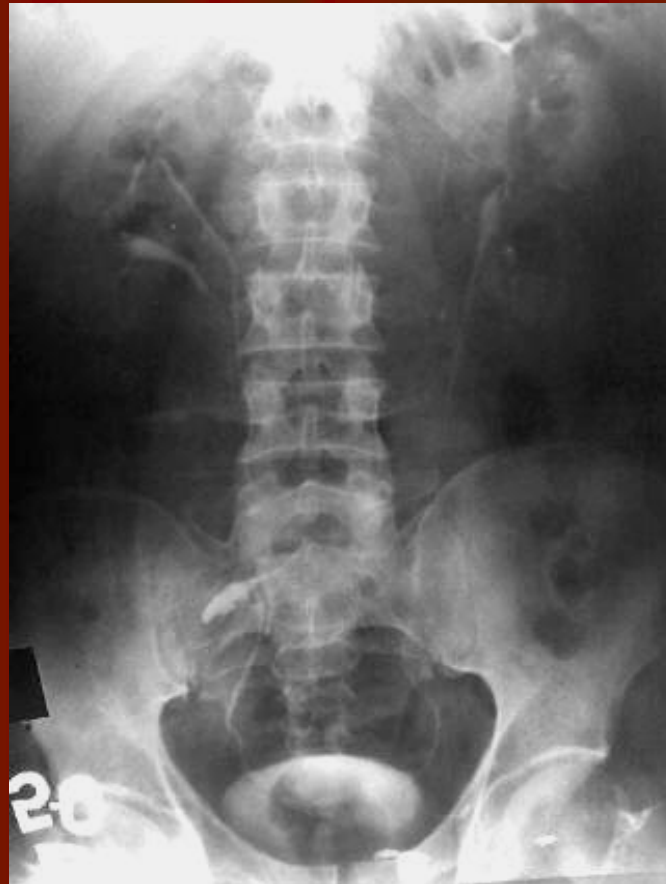IRM renal



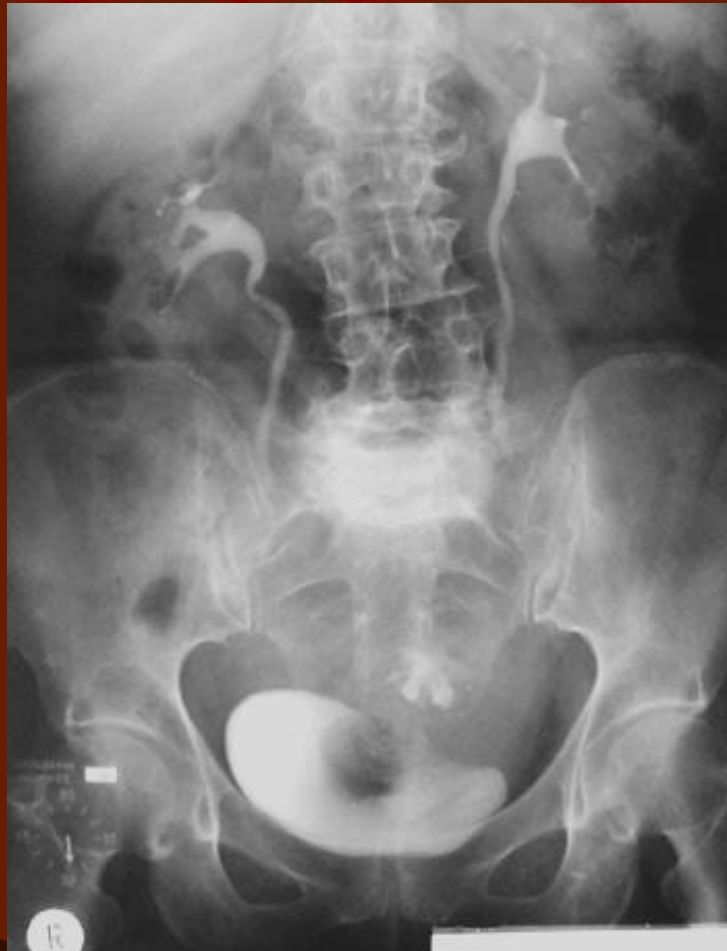Aspect normal renal – urografic - respectiv calicial



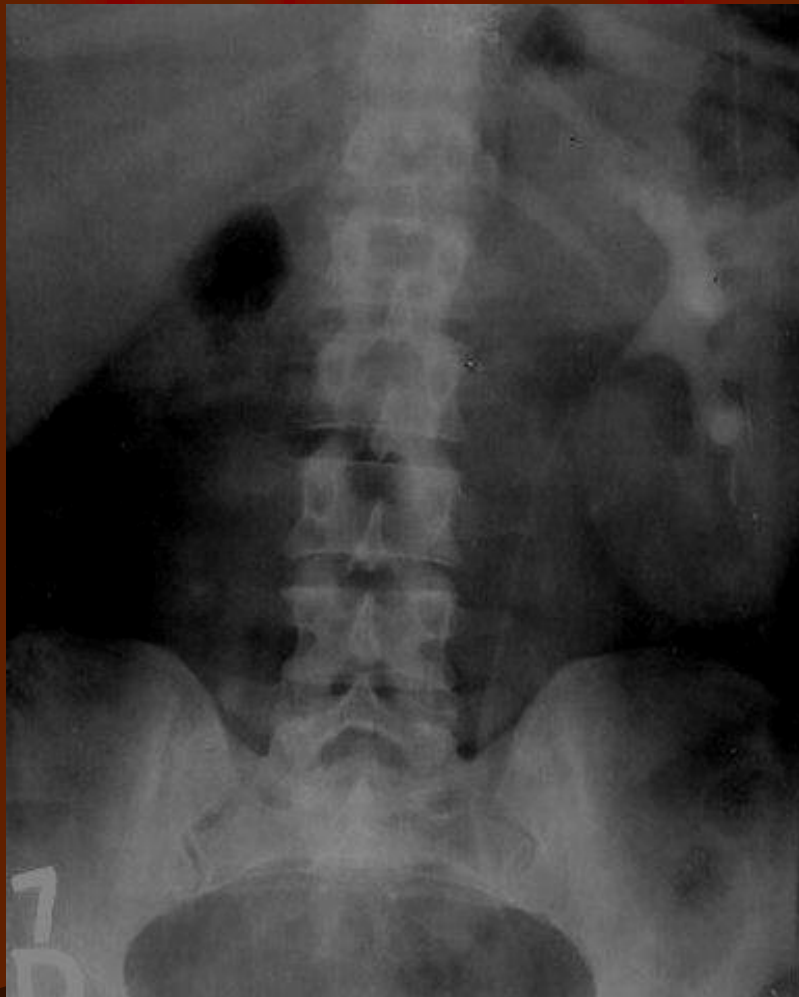Rinichi dubli bilaterali- urografie



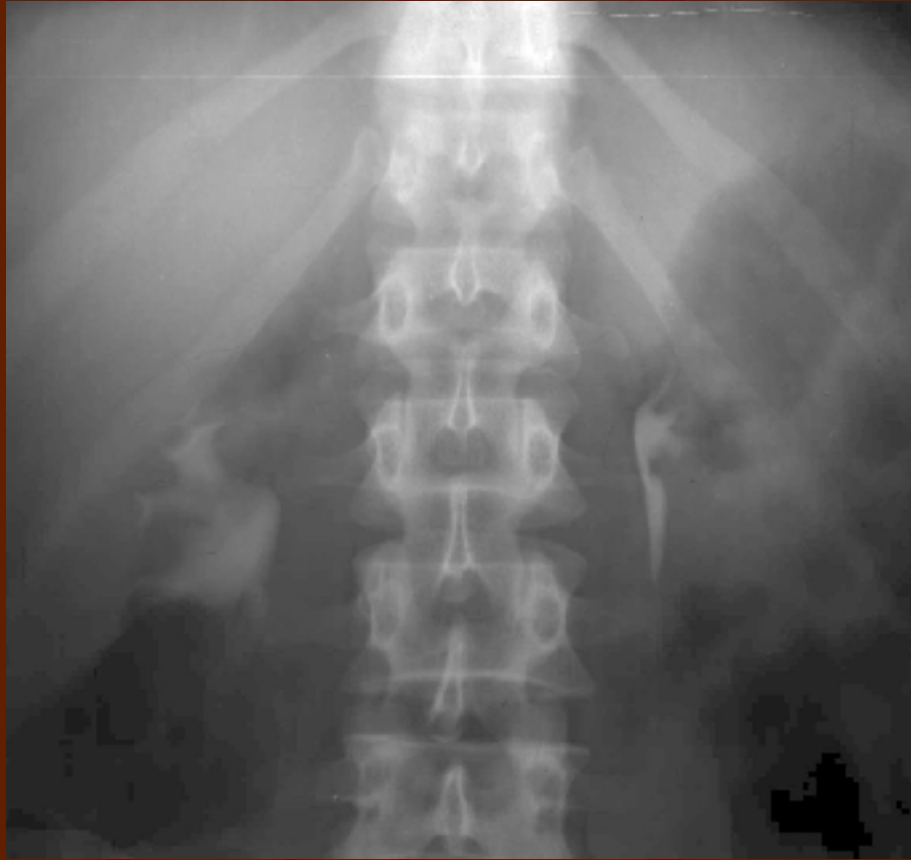Urografie – rinichi dublu dr. și supranumerar pelvin dr.



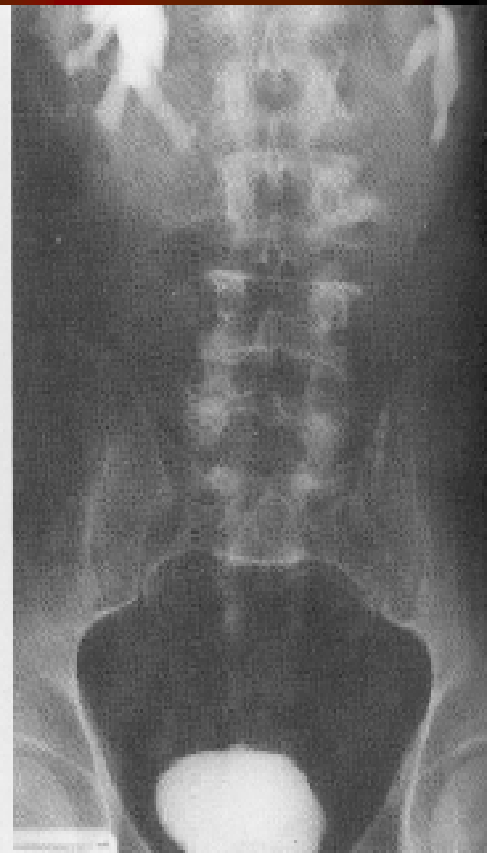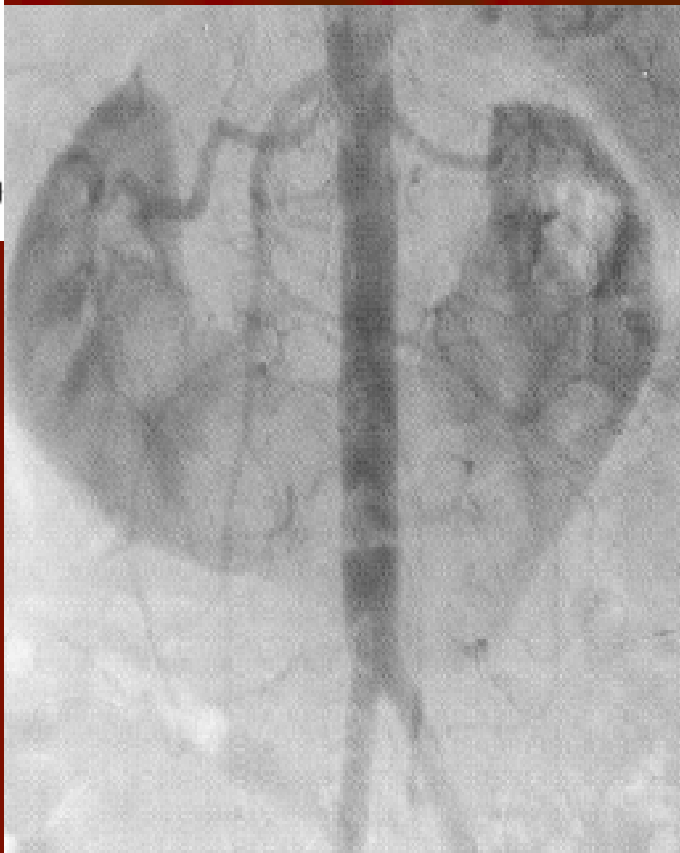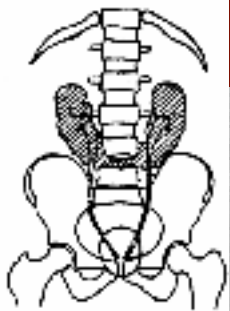
Urografie – rinichi supranumerar pelvin stâng



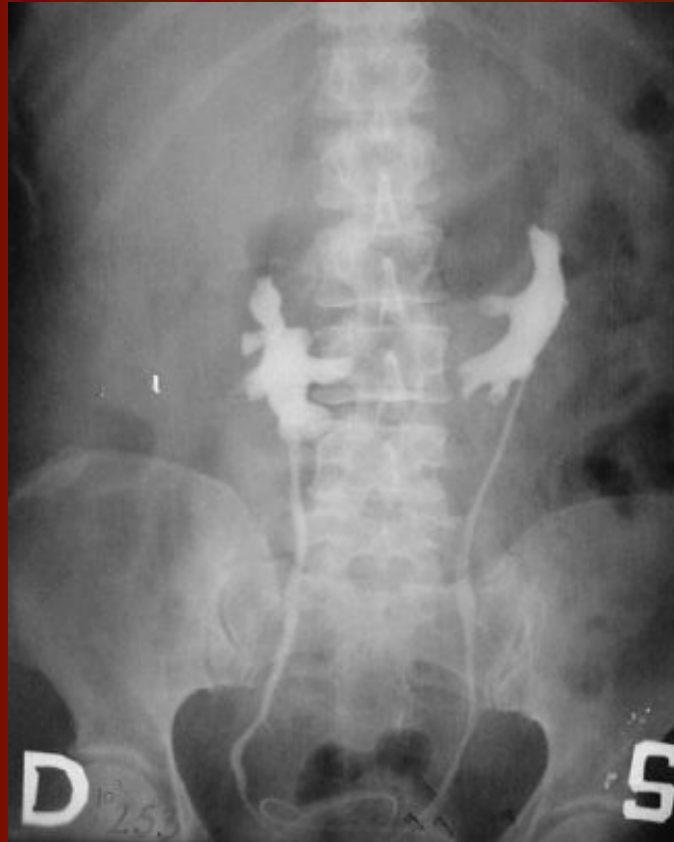Urografie – rinichi unic



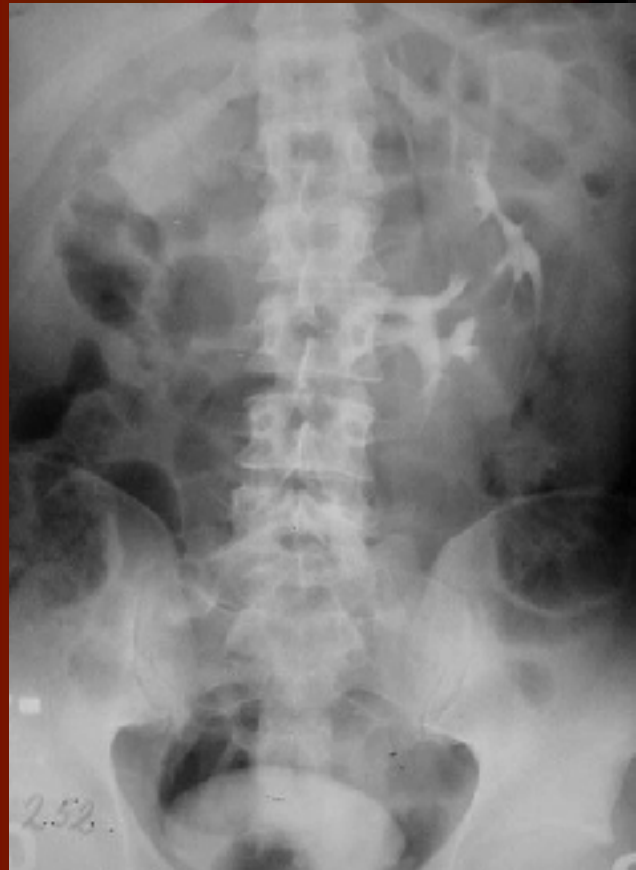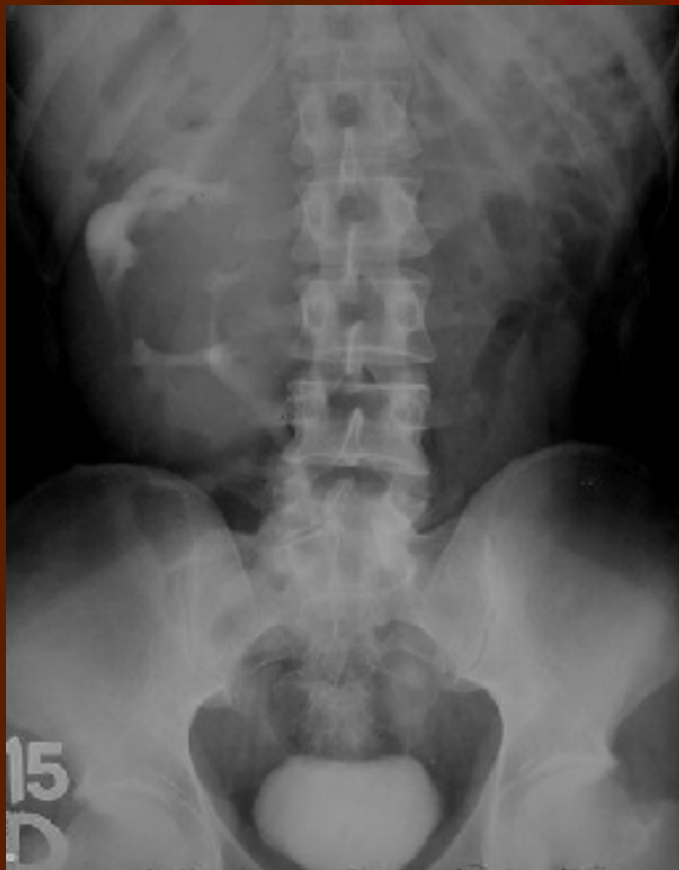Rinichi mic congenital stâng



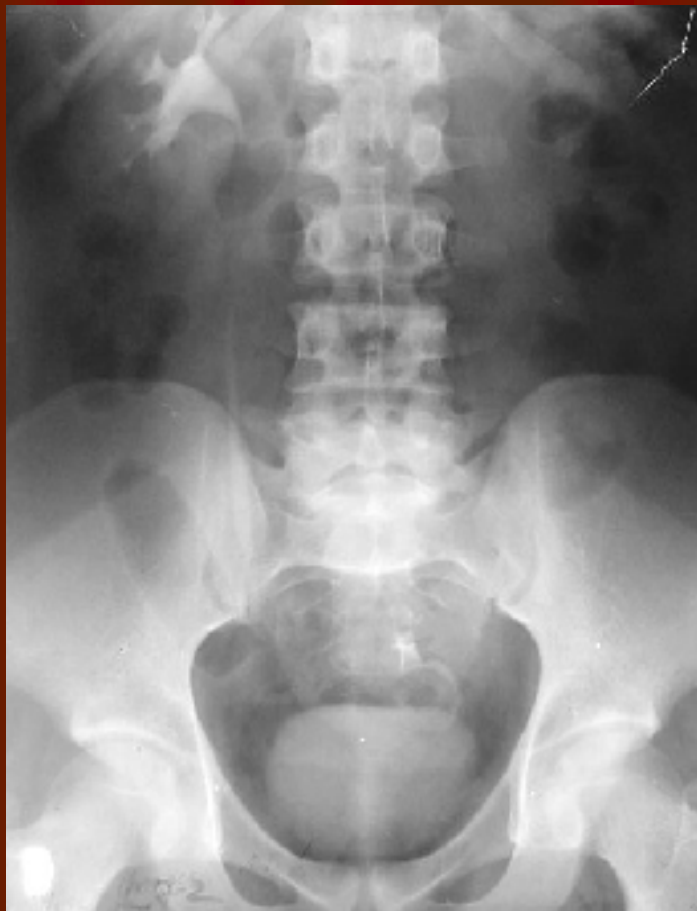Rinichiul în potcoavă
Aortografie + urografie



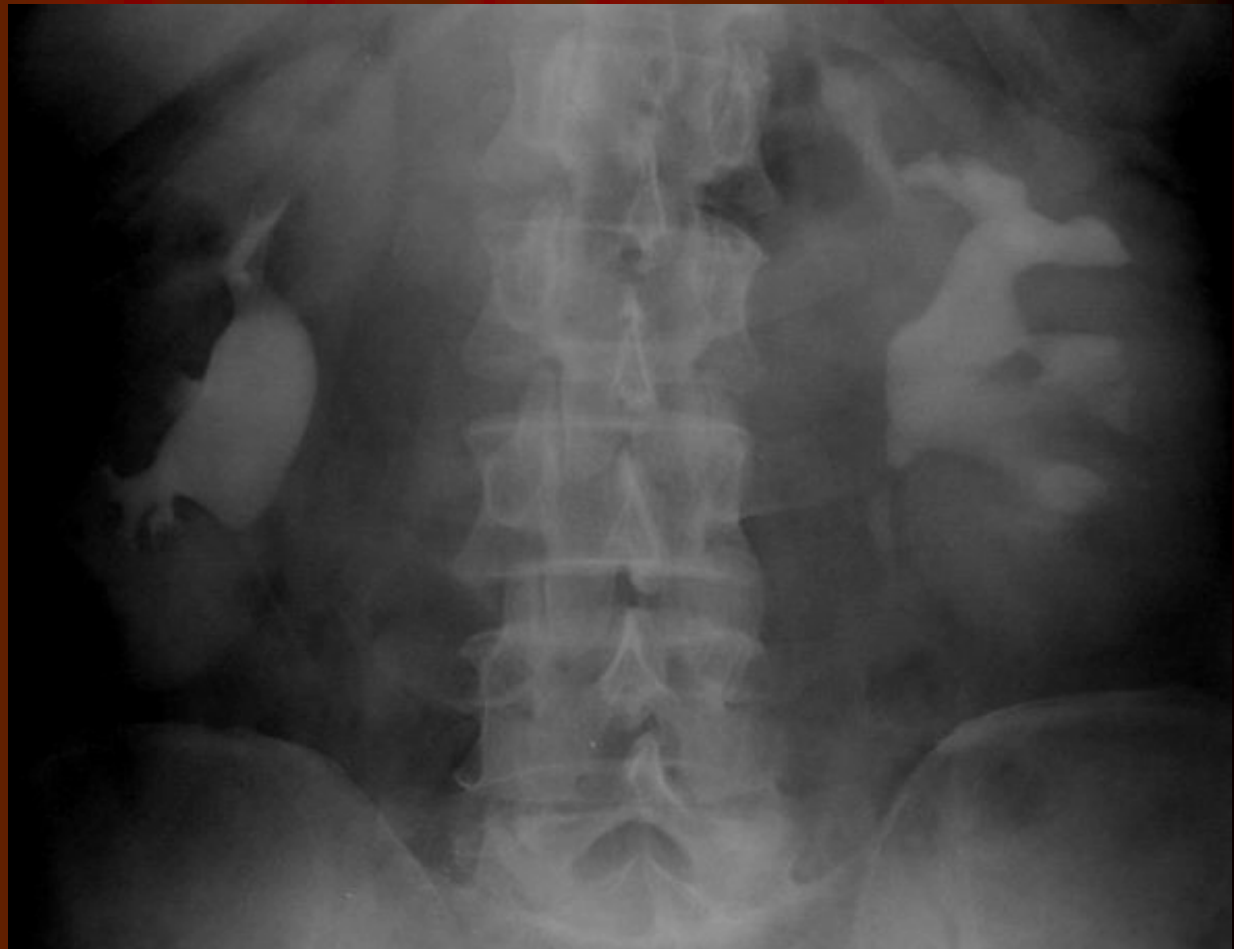Pielografie ascendentă – rinichi în potcoavă



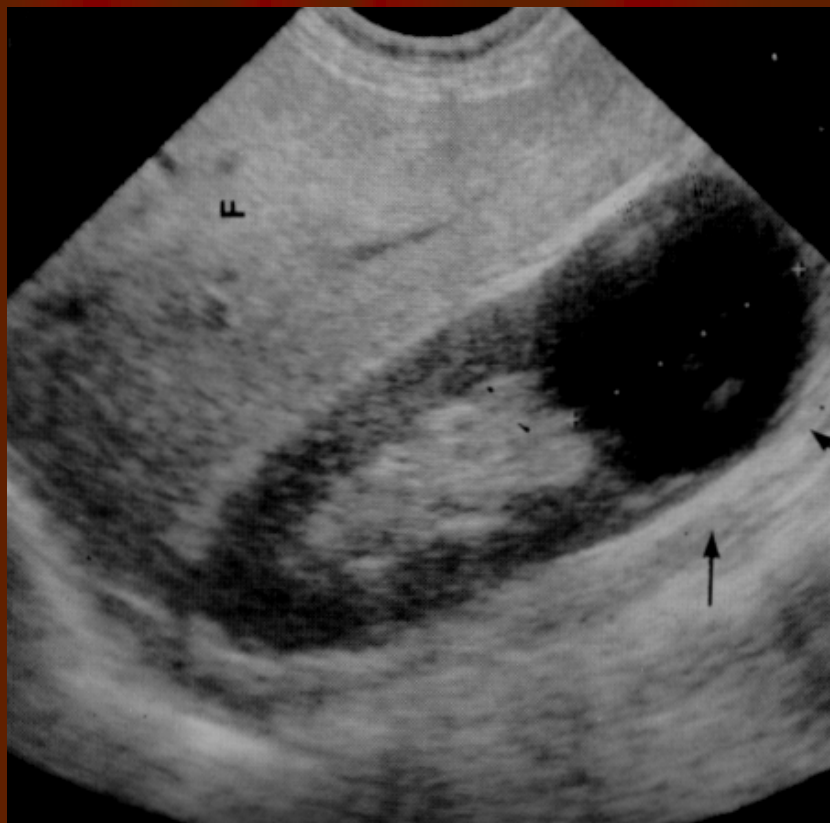
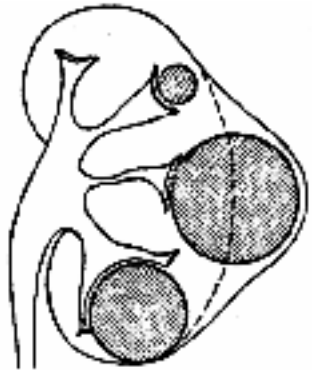
Urografie – ectopie încrucișată



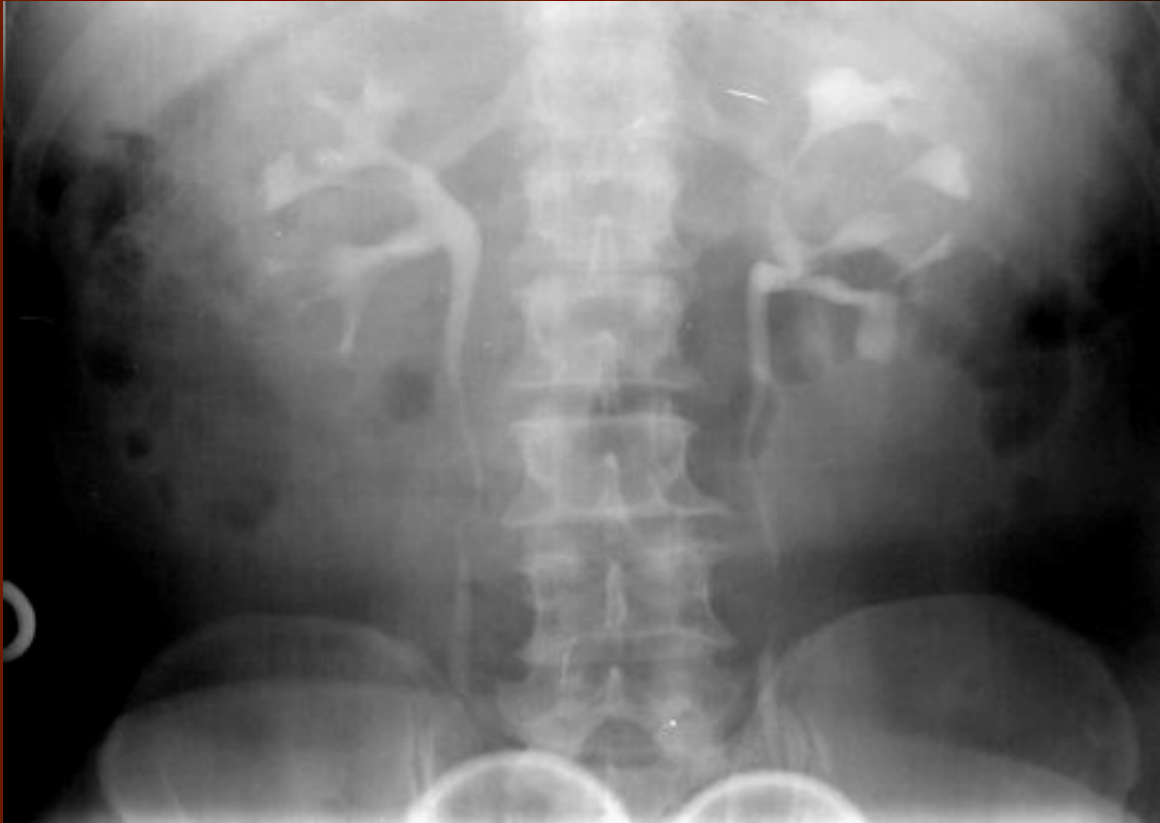Urografie – ectopie pelvină



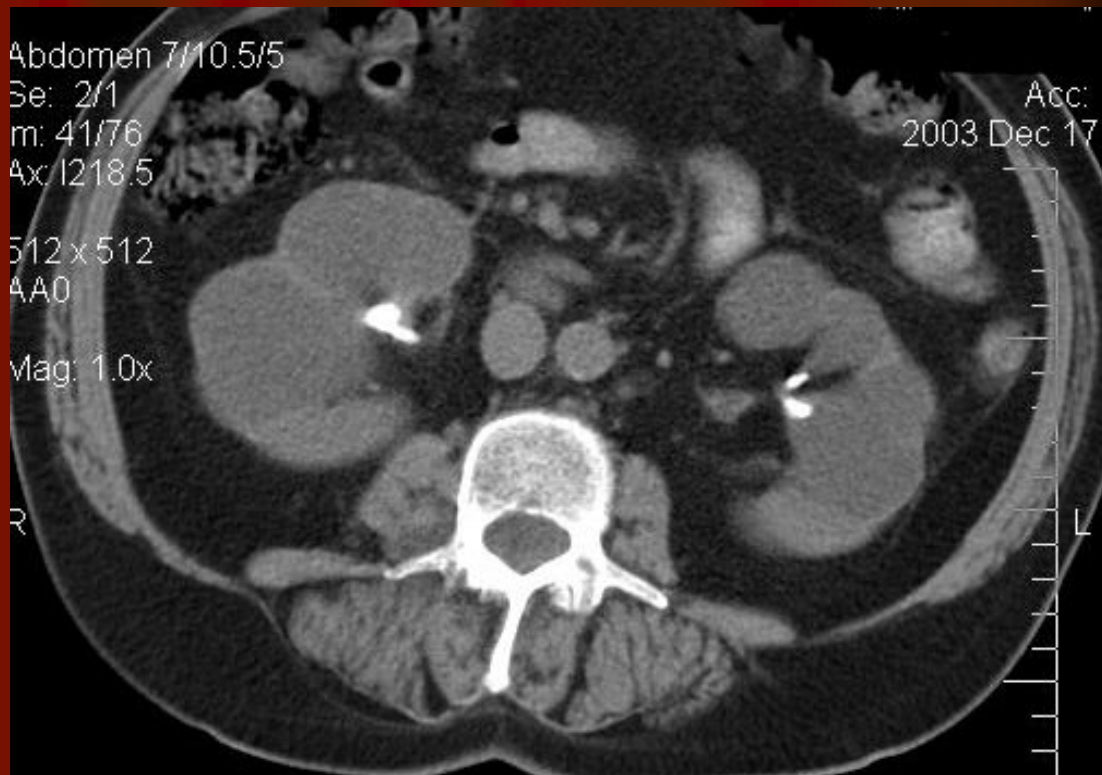
Urografie – stenoză de jonctiune pieloureterală



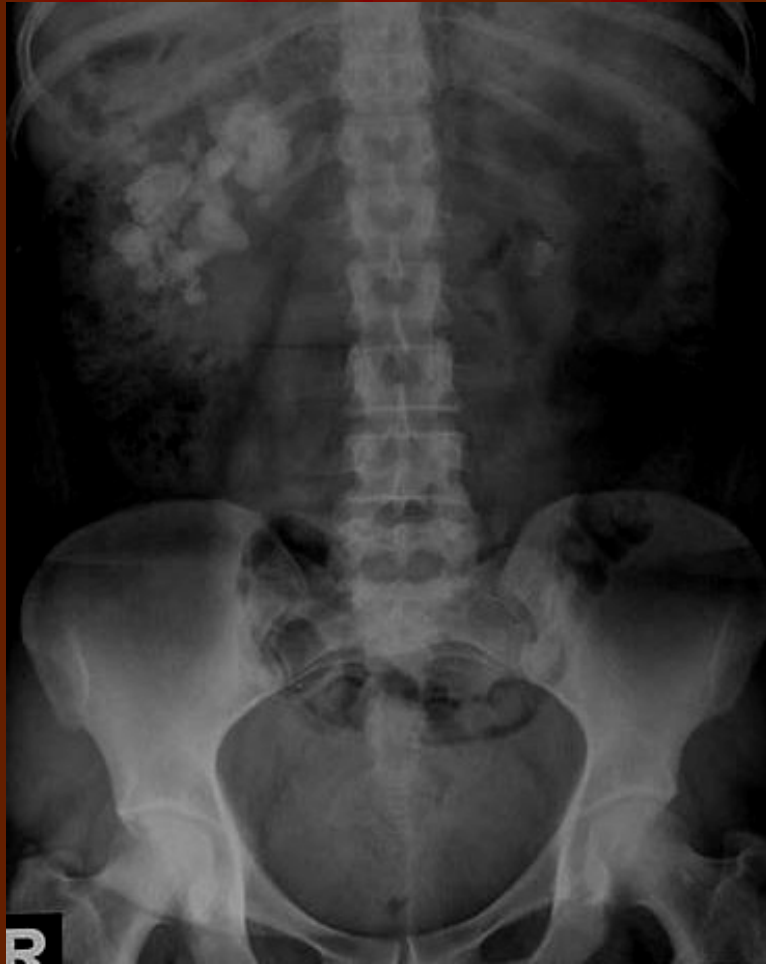Chiste renale - ecografie



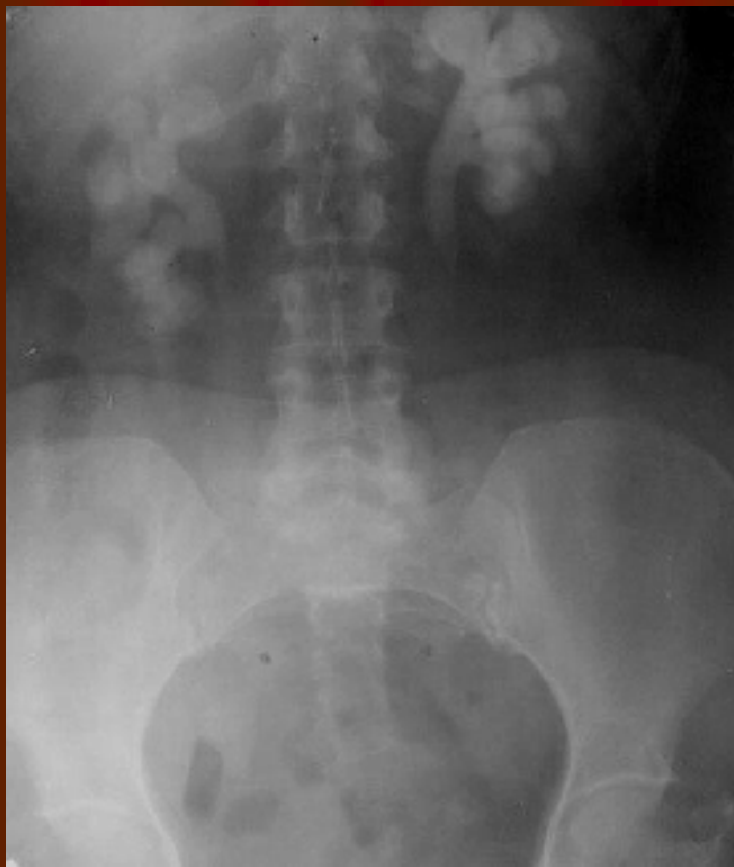Urografie - Polichistoza renală



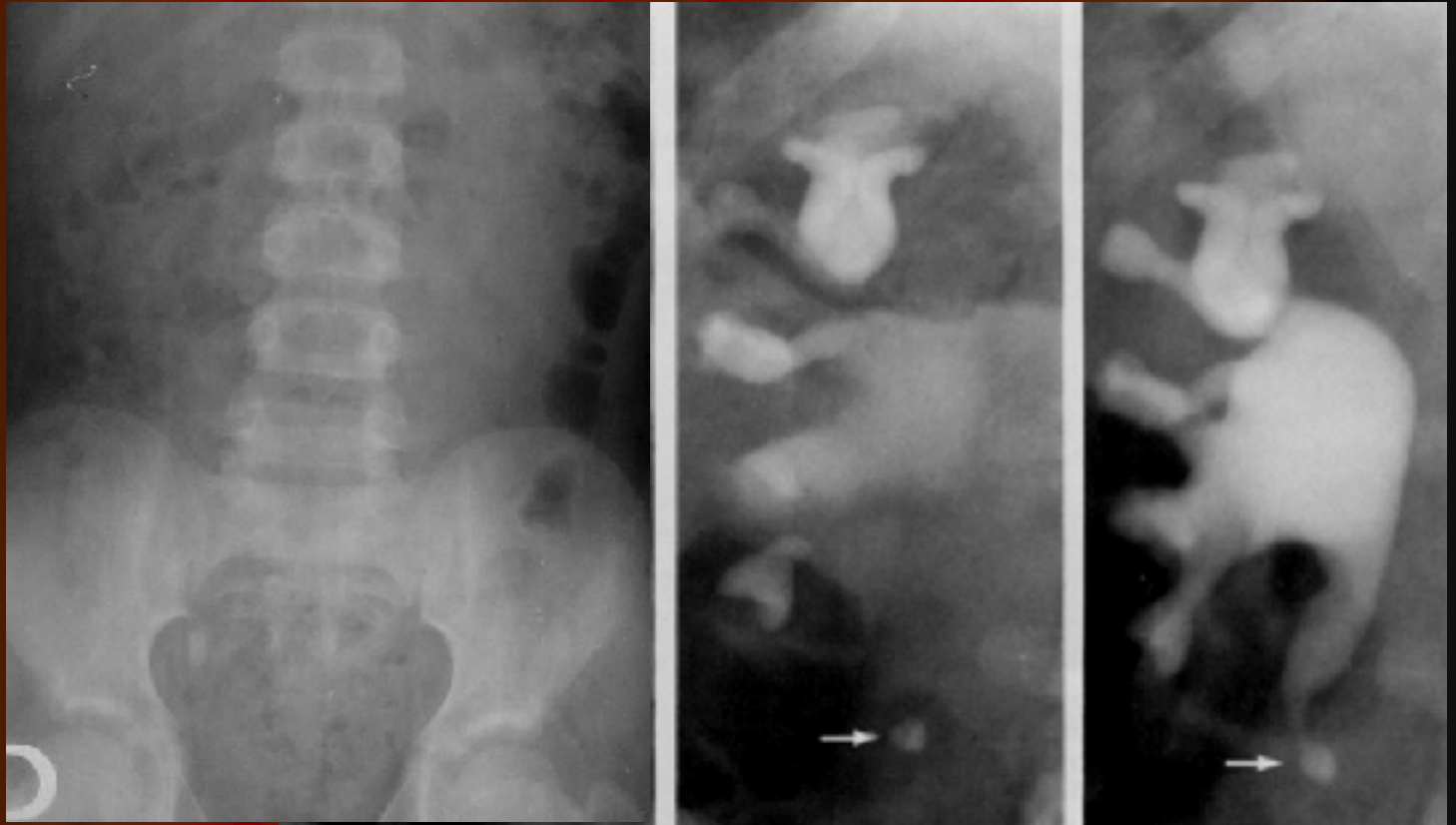
Polichistoza renală - CT



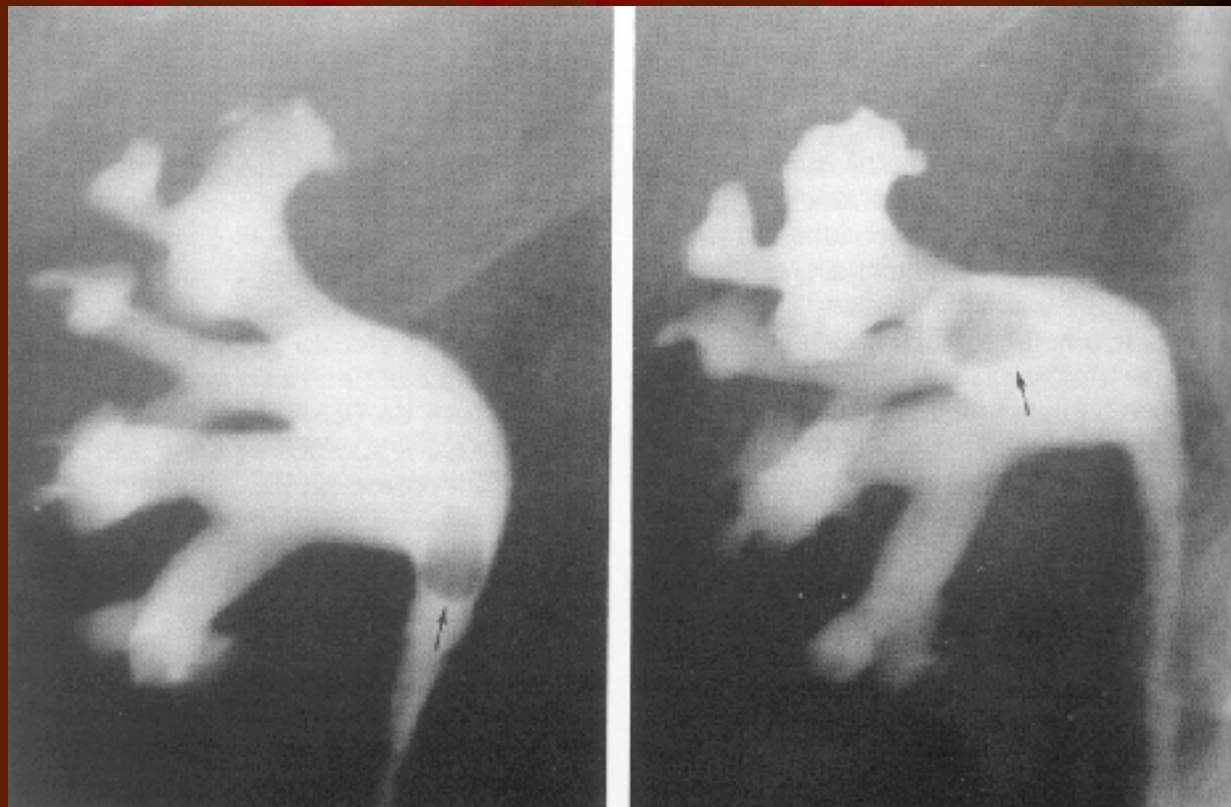Radiografie renală simplă – calculoză renală



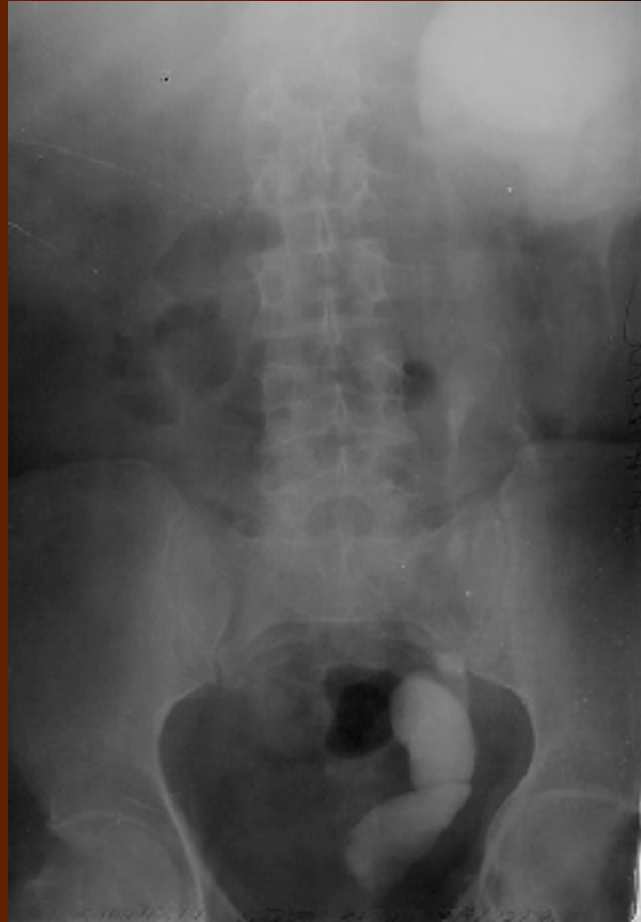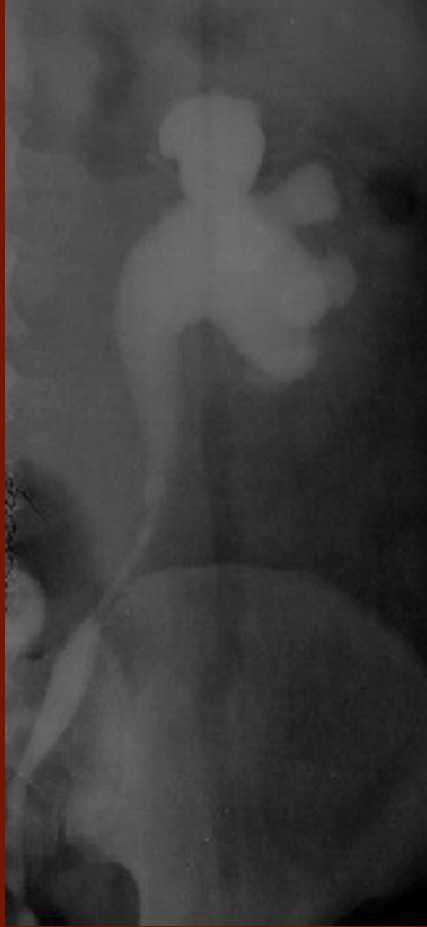
Radiografie renală simplă – calculi coraliformi



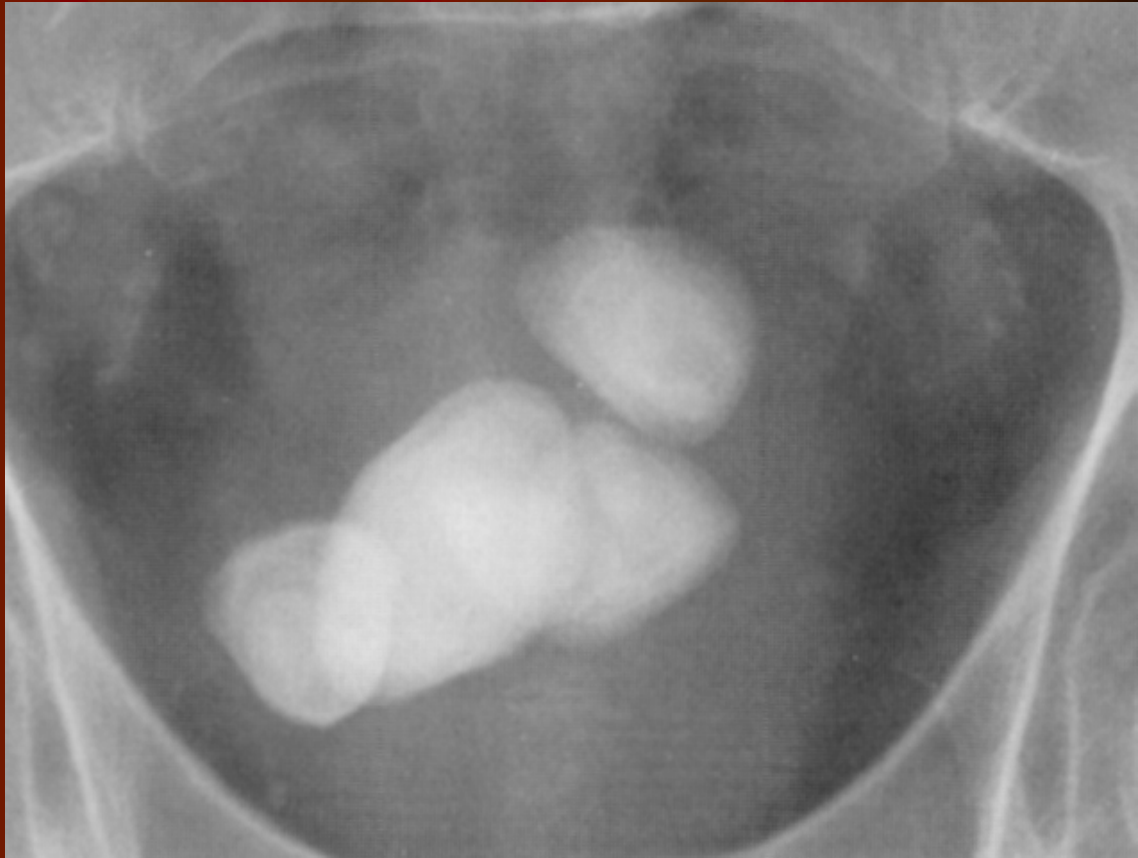Calcul ureteral – radiografie renală simplă
- urografie



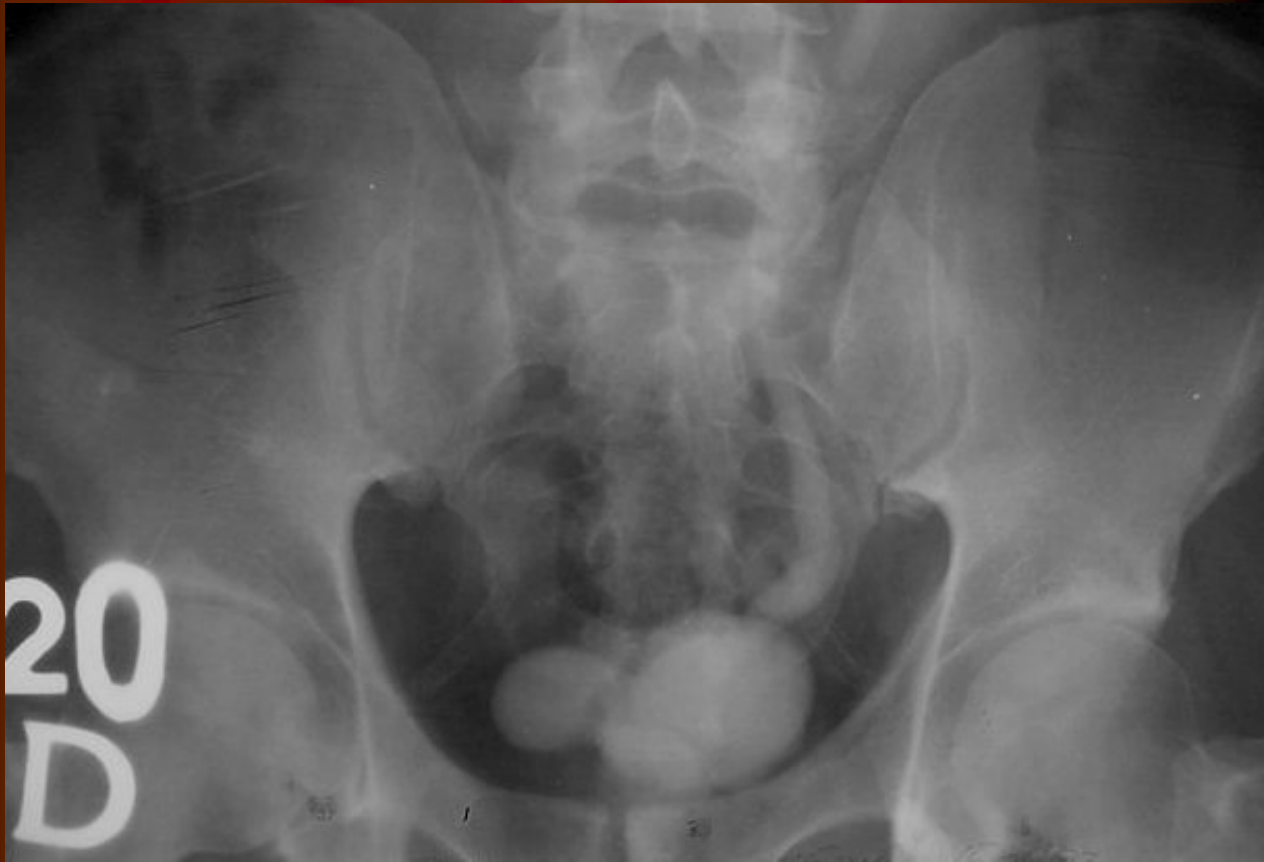Calcul radiotransparent



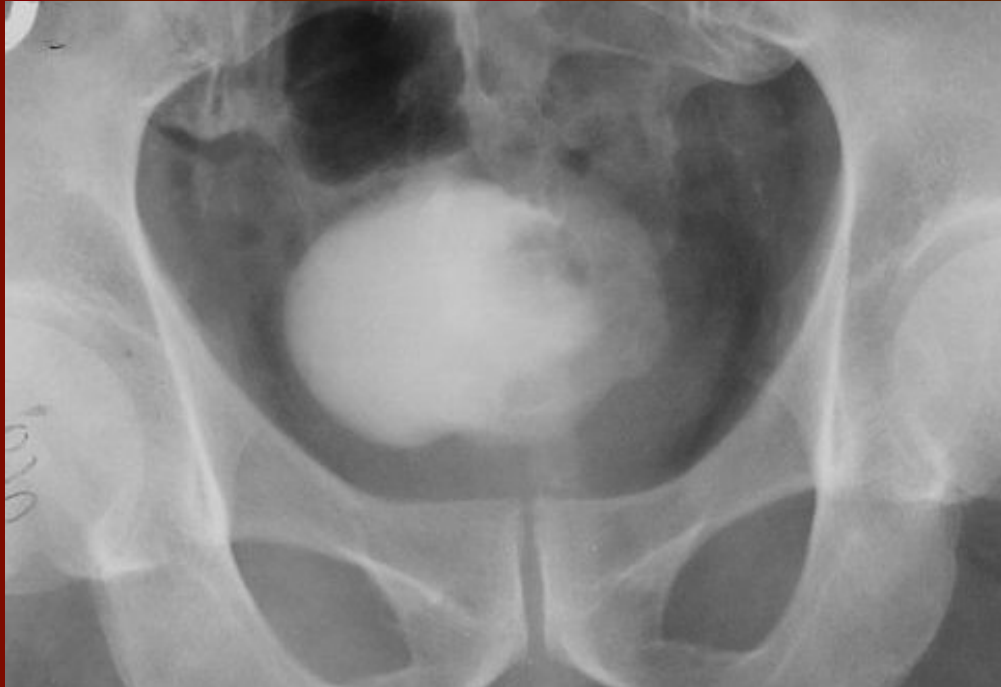Urografie - ureterohidronefroză



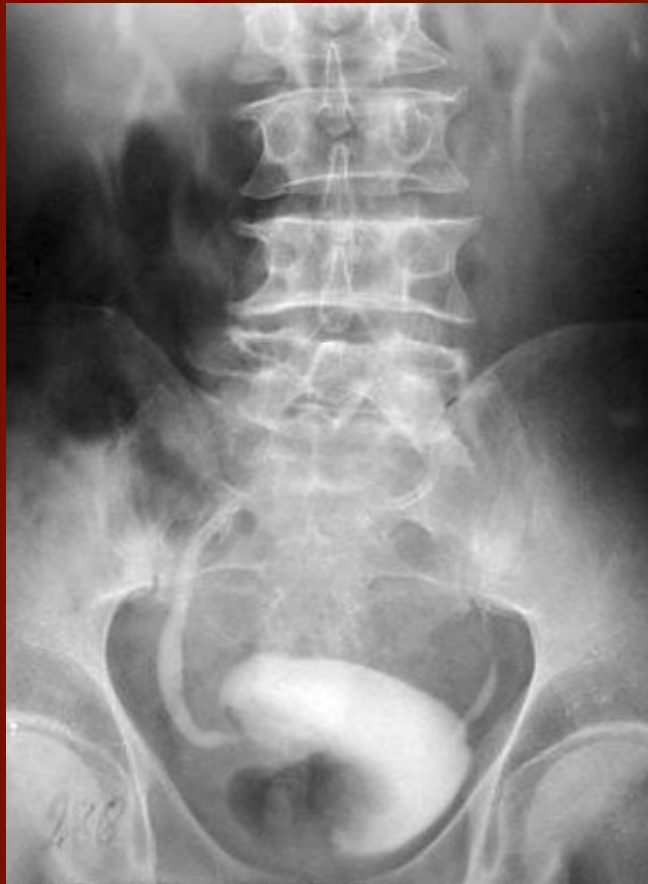Calcoli radioopaci vezicali



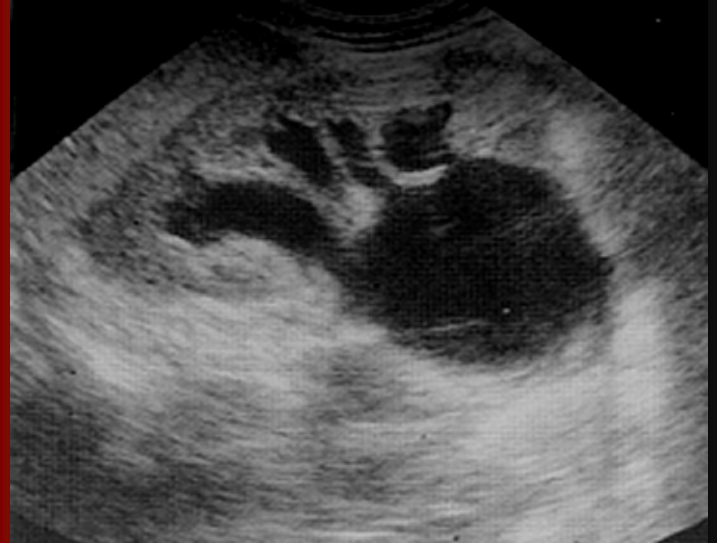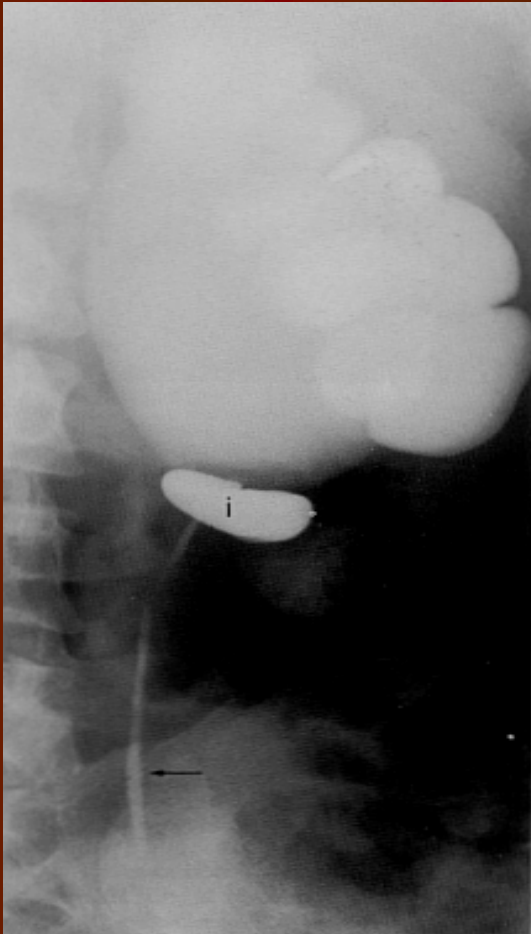Urografie – diverticoli vezicali



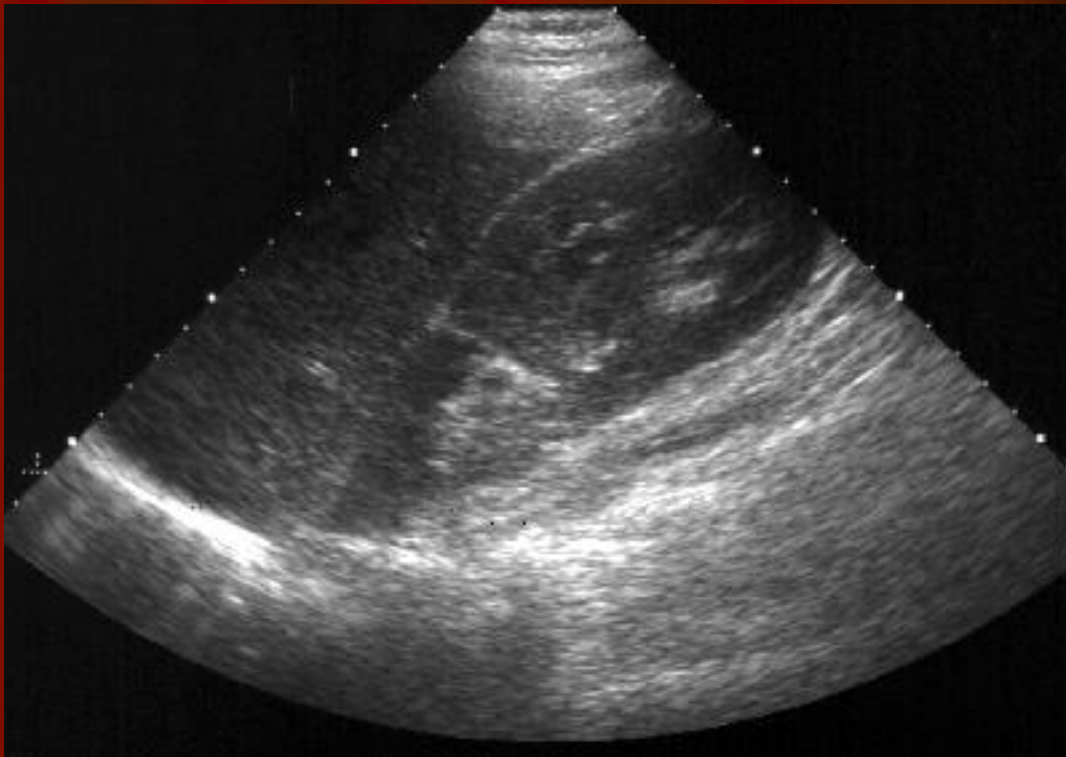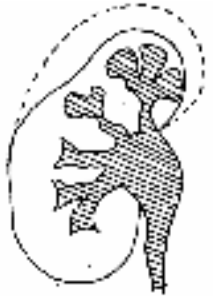Cistografie – cancer proliferativ vezică



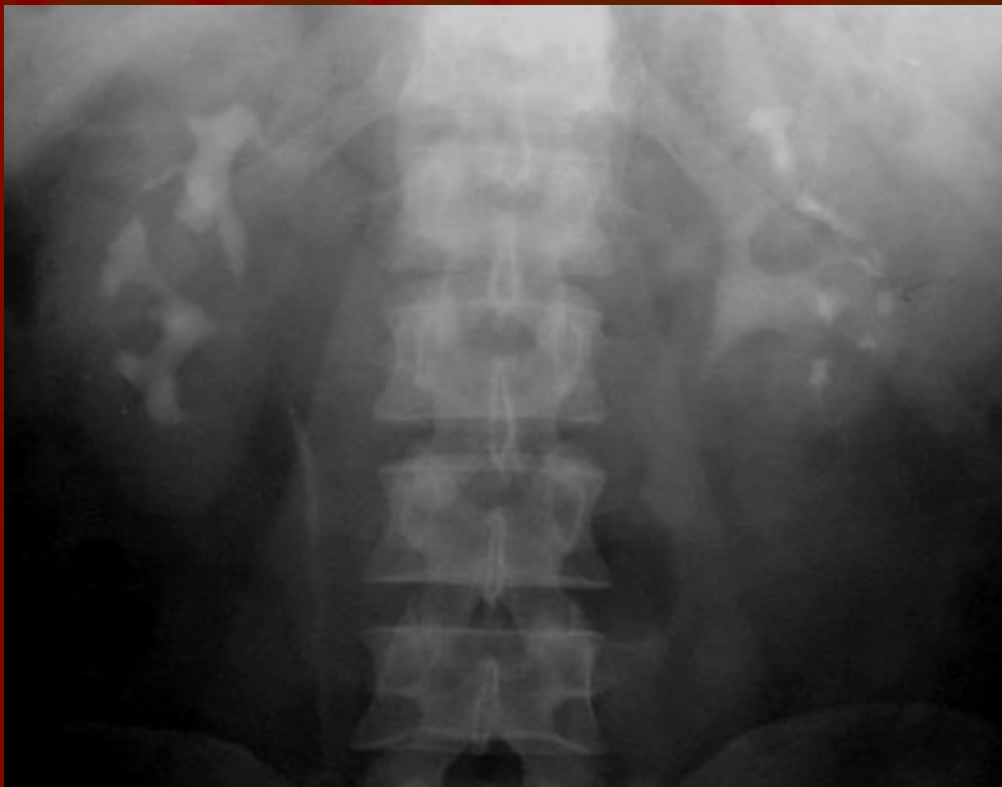Urografie – cancer proliferativ vezică



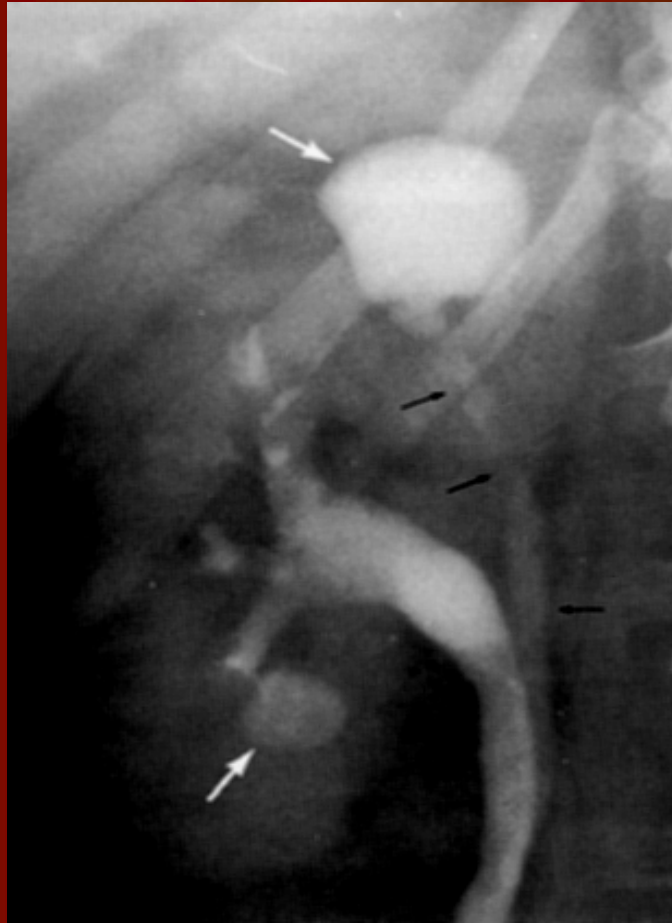
Hidronefroză-urografie, respectiv ecografie



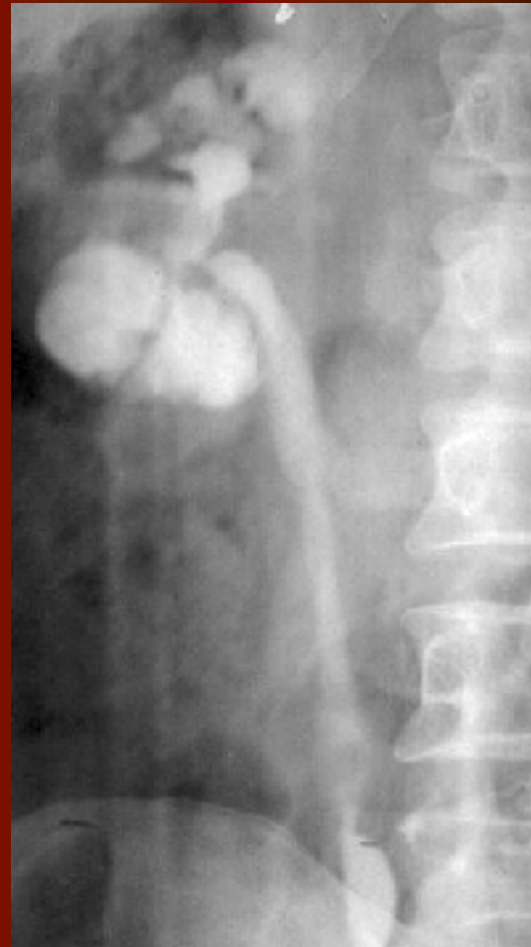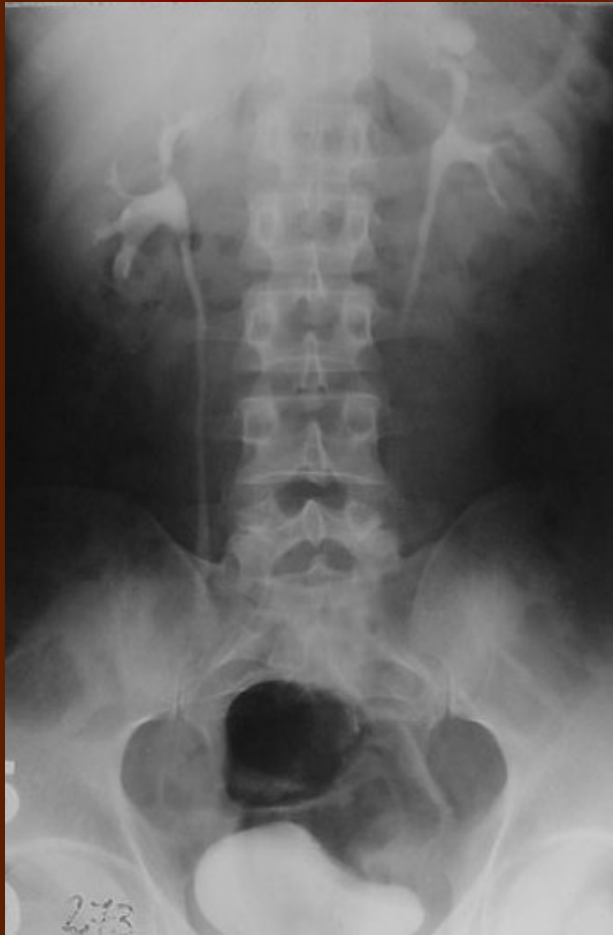Pielonefrită localizată –ecografie



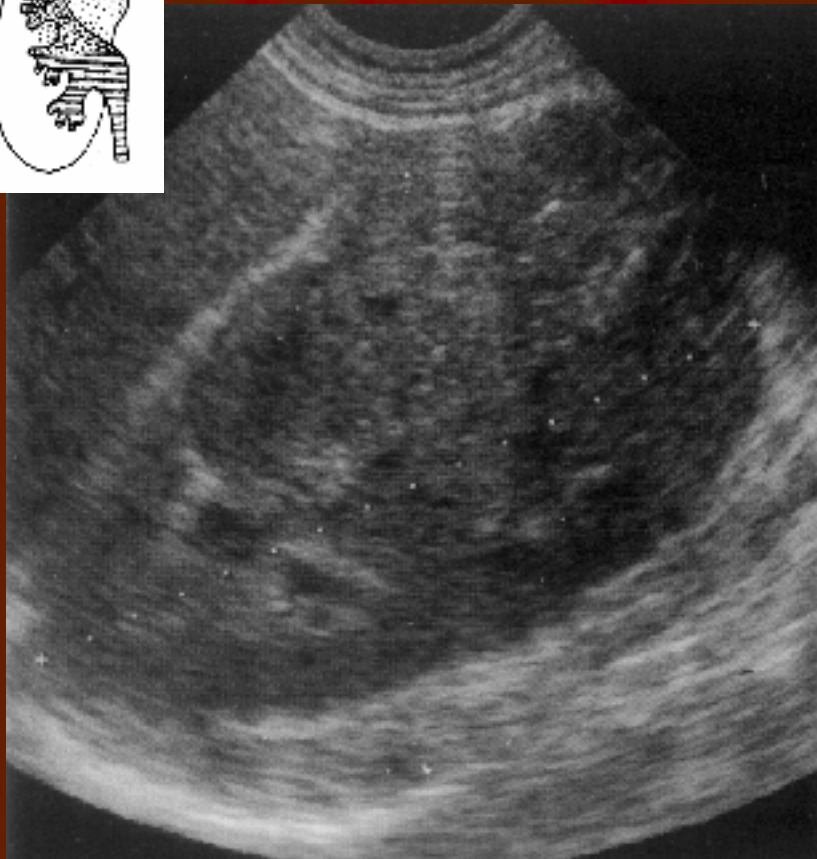
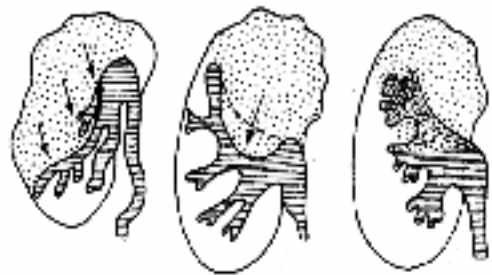
Pielonefrită – urografie



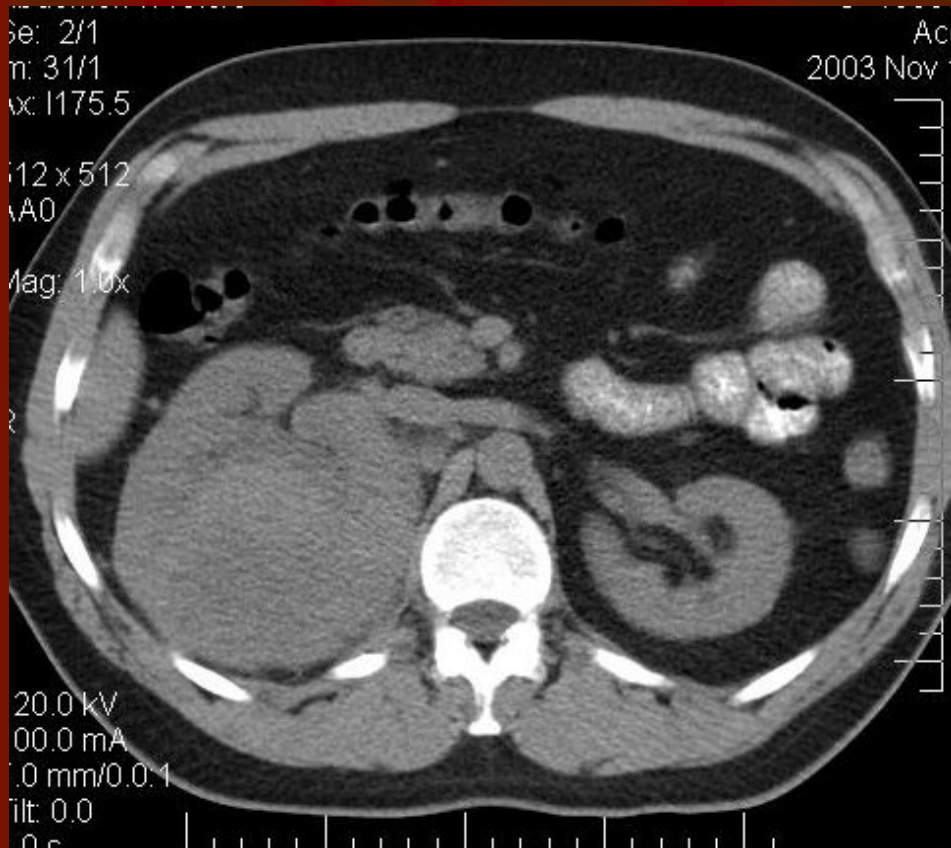
Urografie-leziuni polimorfe tuberculoase



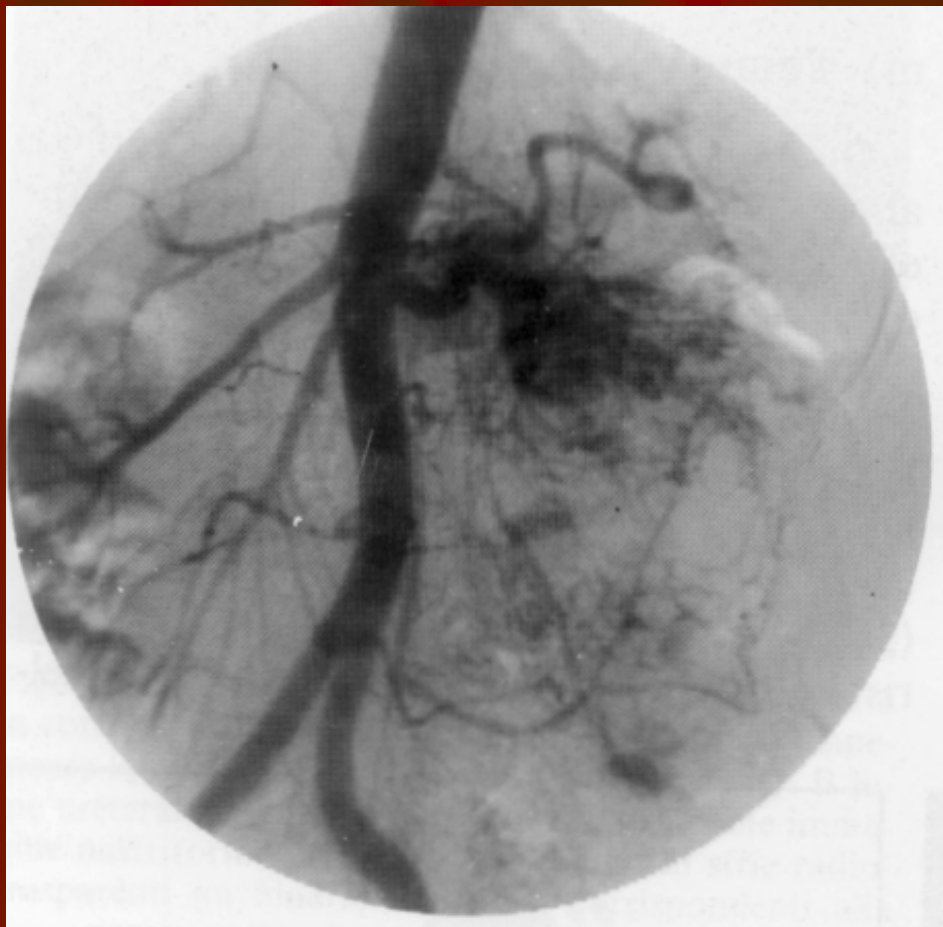Urografie-leziuni polimorfe tuberculoase



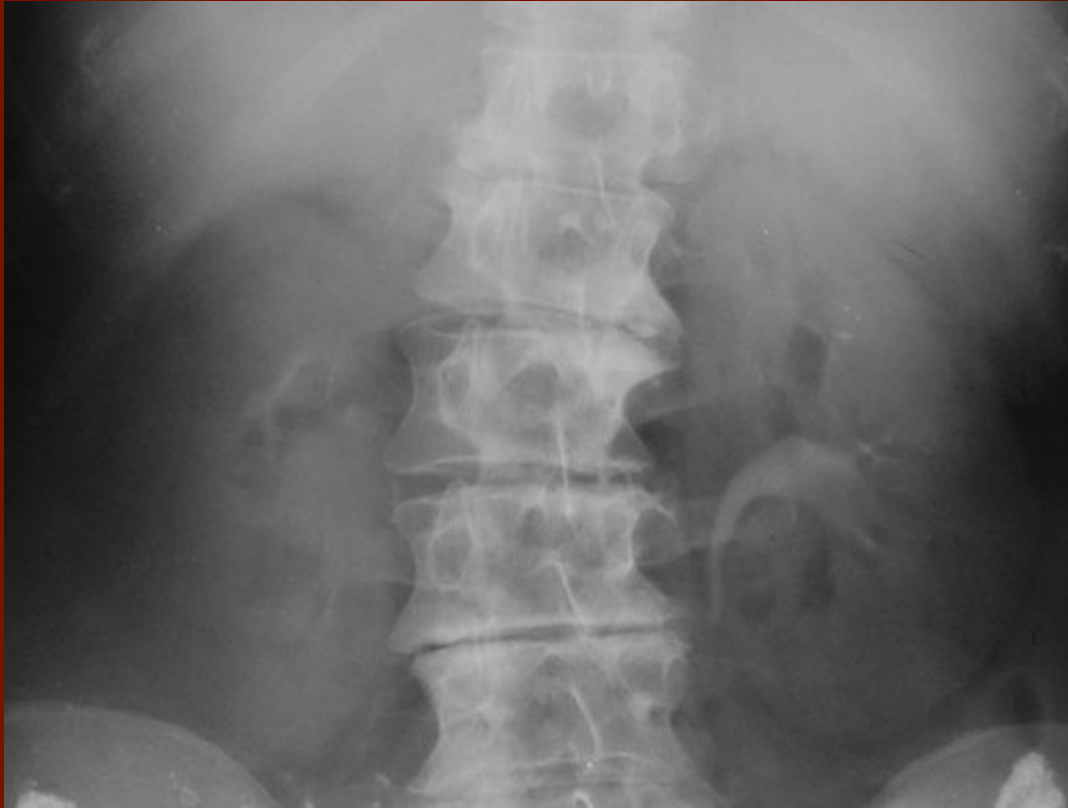Neoplasm parenchimatous renal- echografie



Cancerul renal - CT

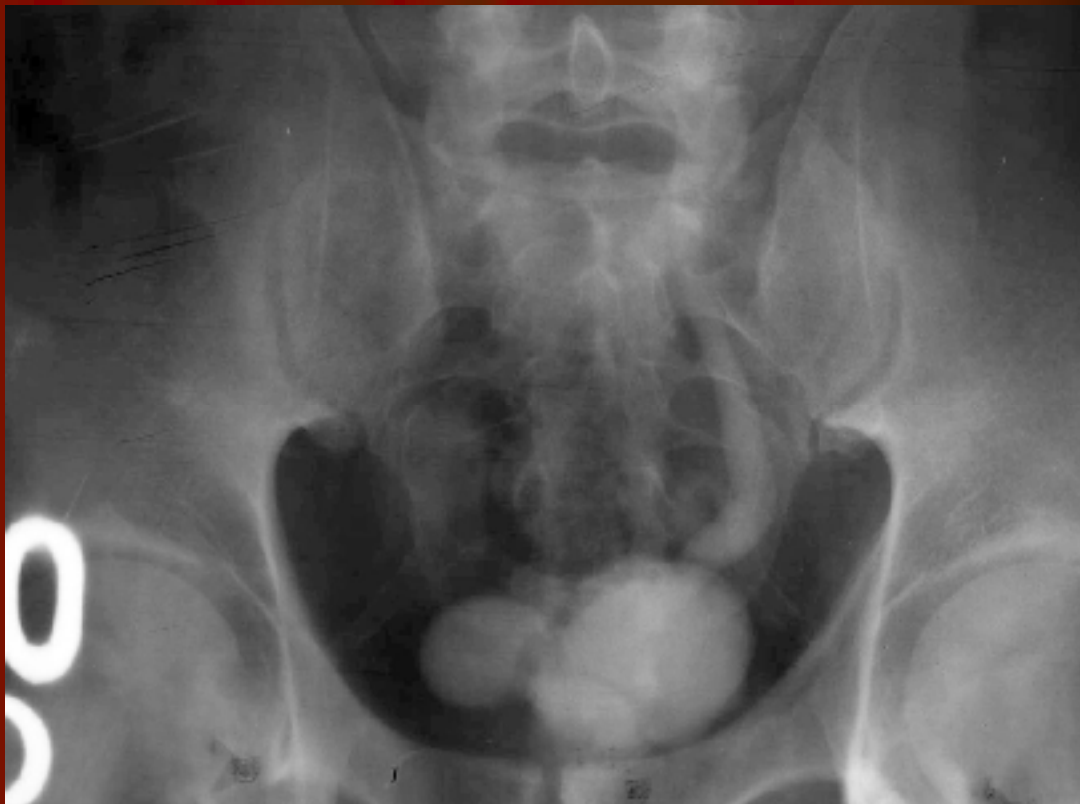

Angiografie renală-tumoră renală

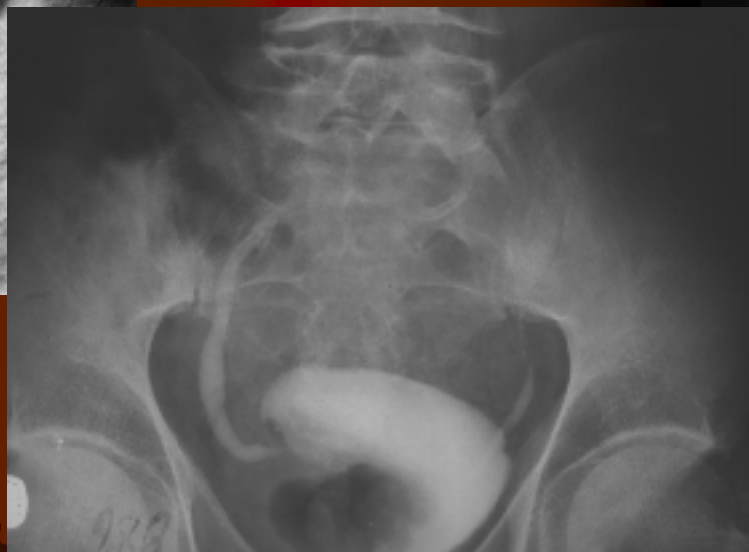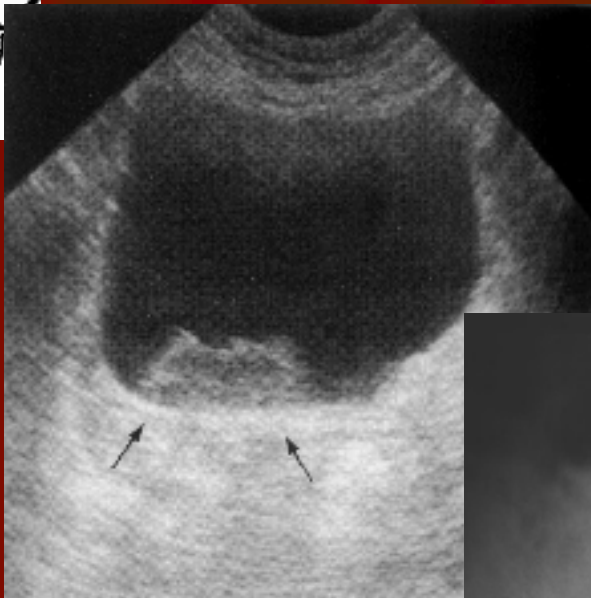
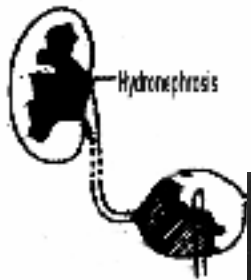


Cancerul renal - urografie

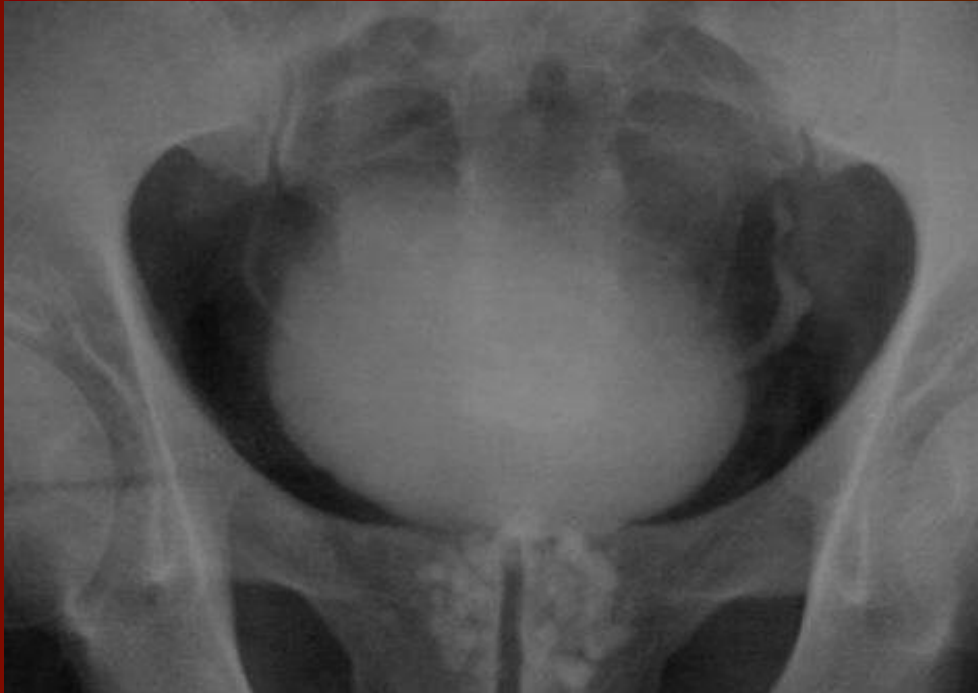



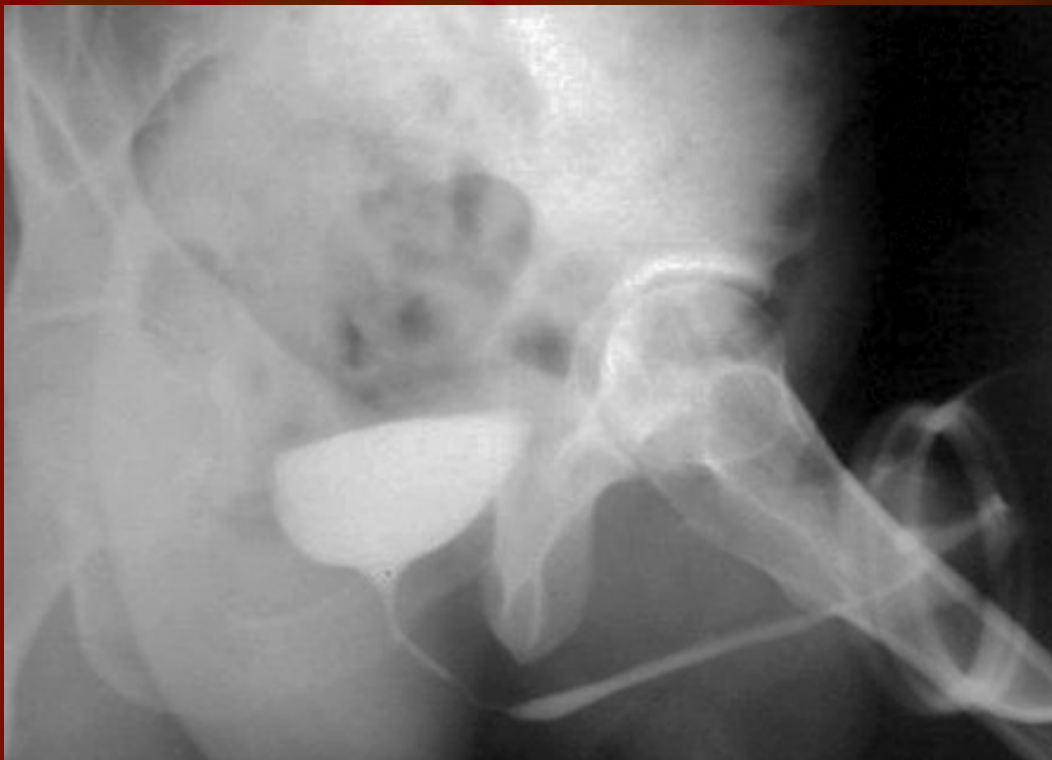Diverticul vezical - cistografie



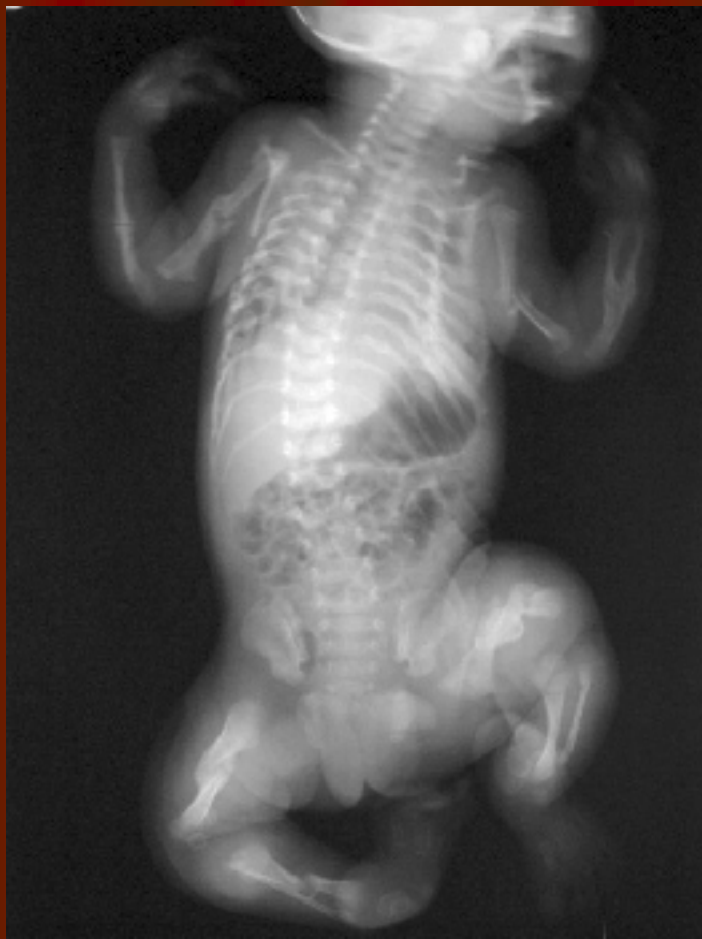Cancer vezical-ecografie
-cistografie



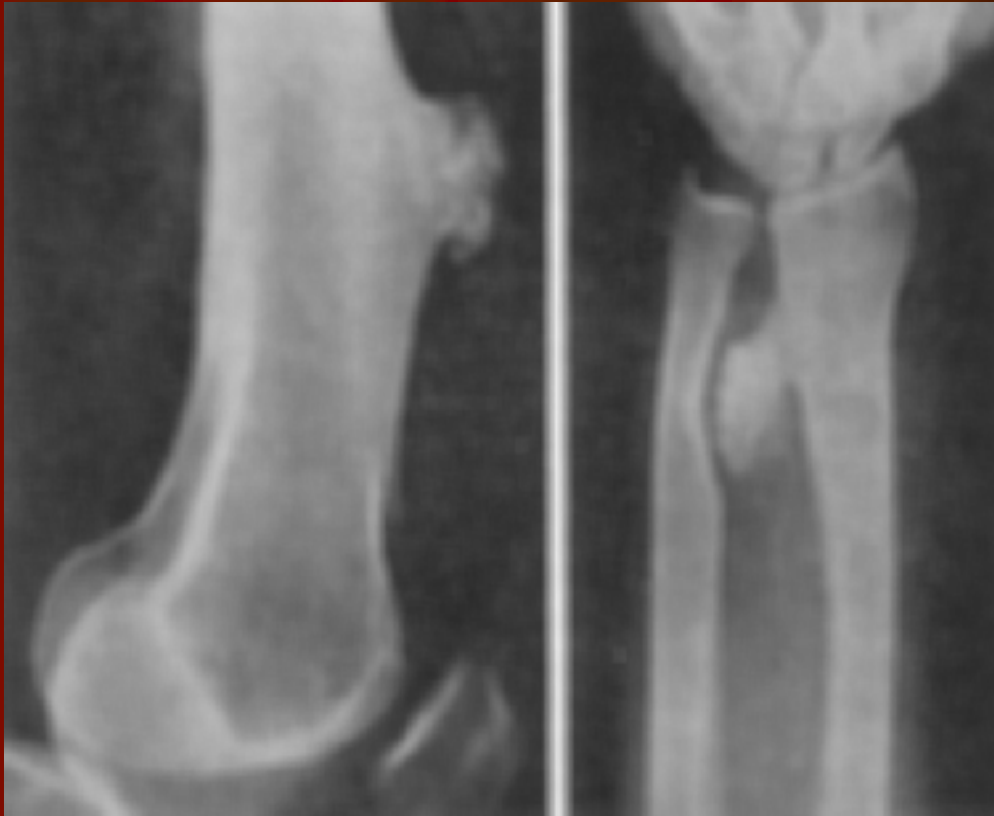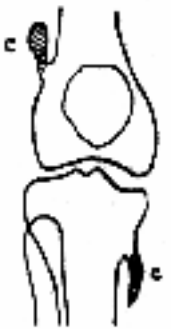Calcificări prostatice



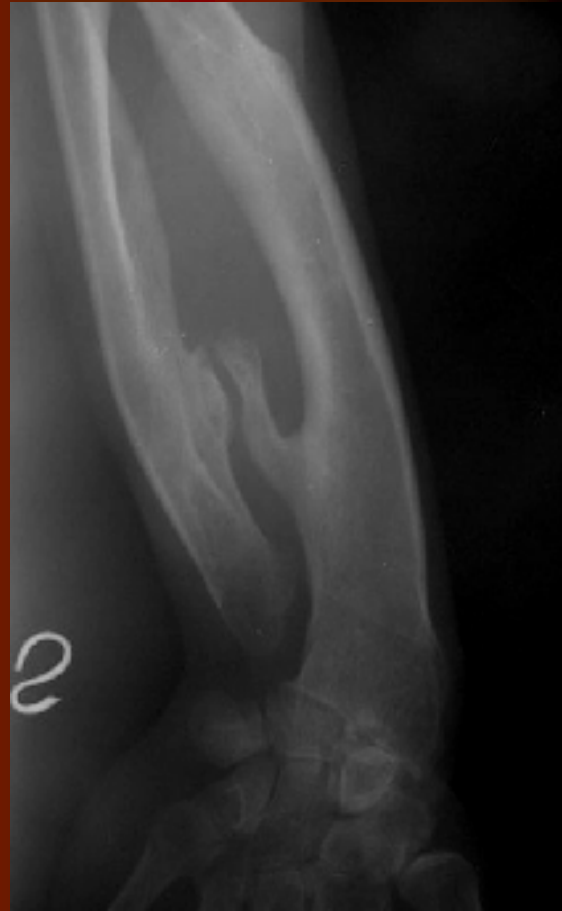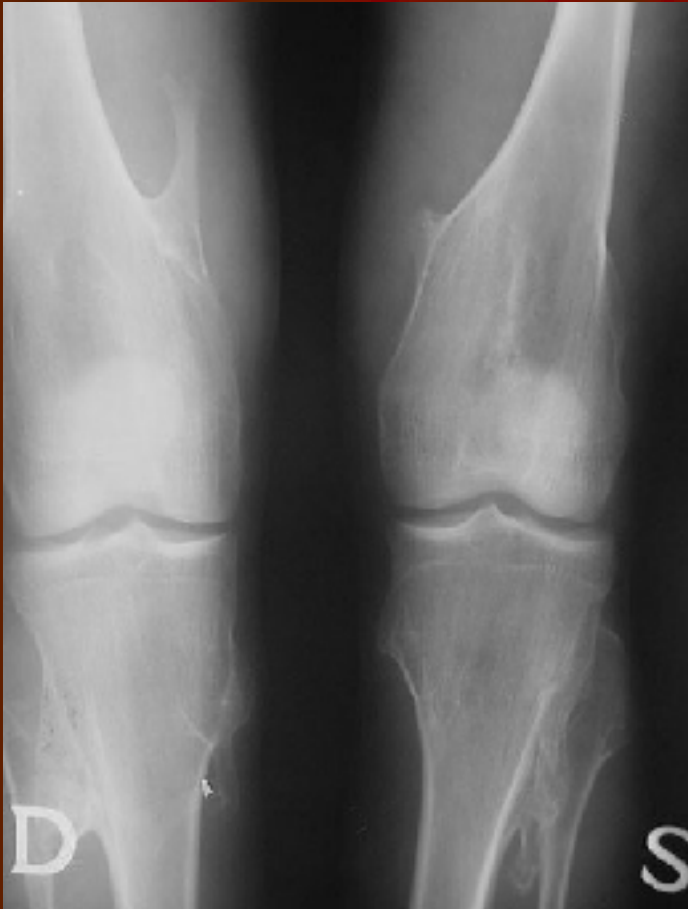Cistografie permicțională – stenoza uretrei prostatice



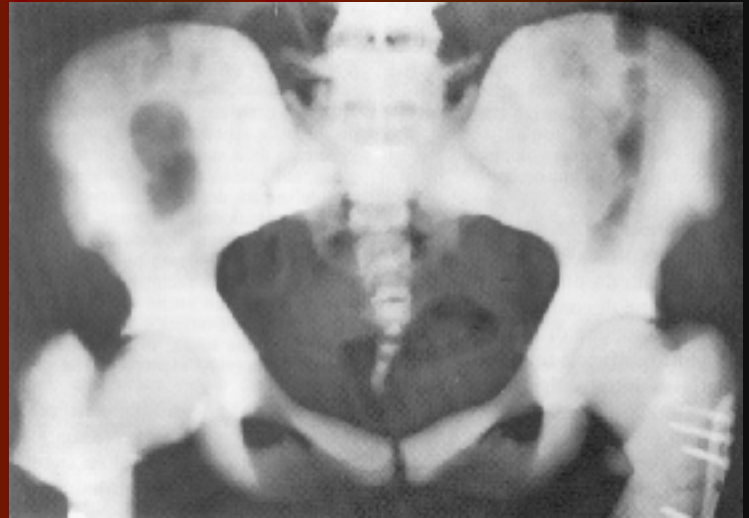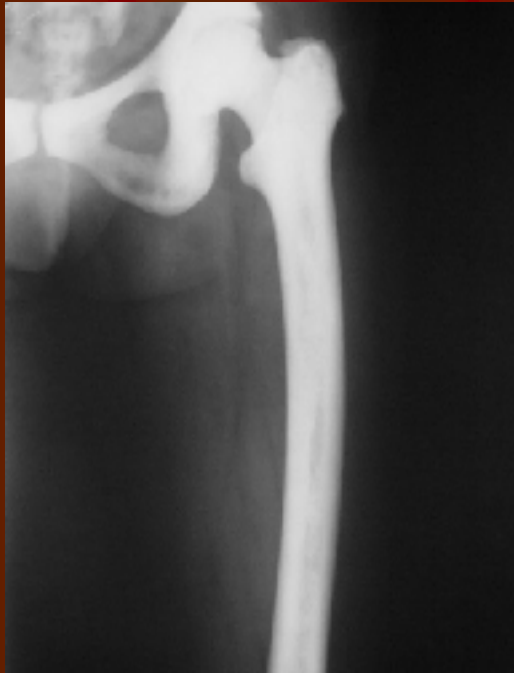Osteogeneza imperfectă



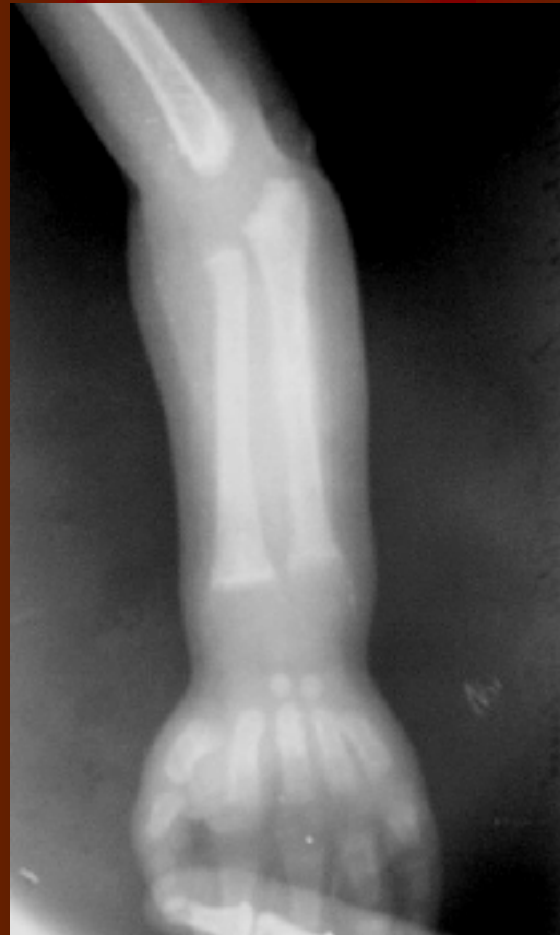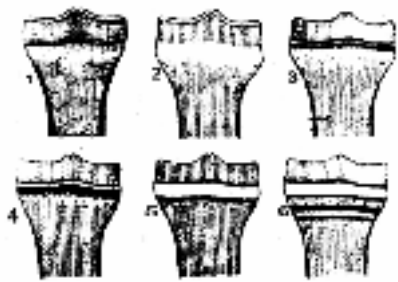Boala Ombredanne



Boala Ombredanne

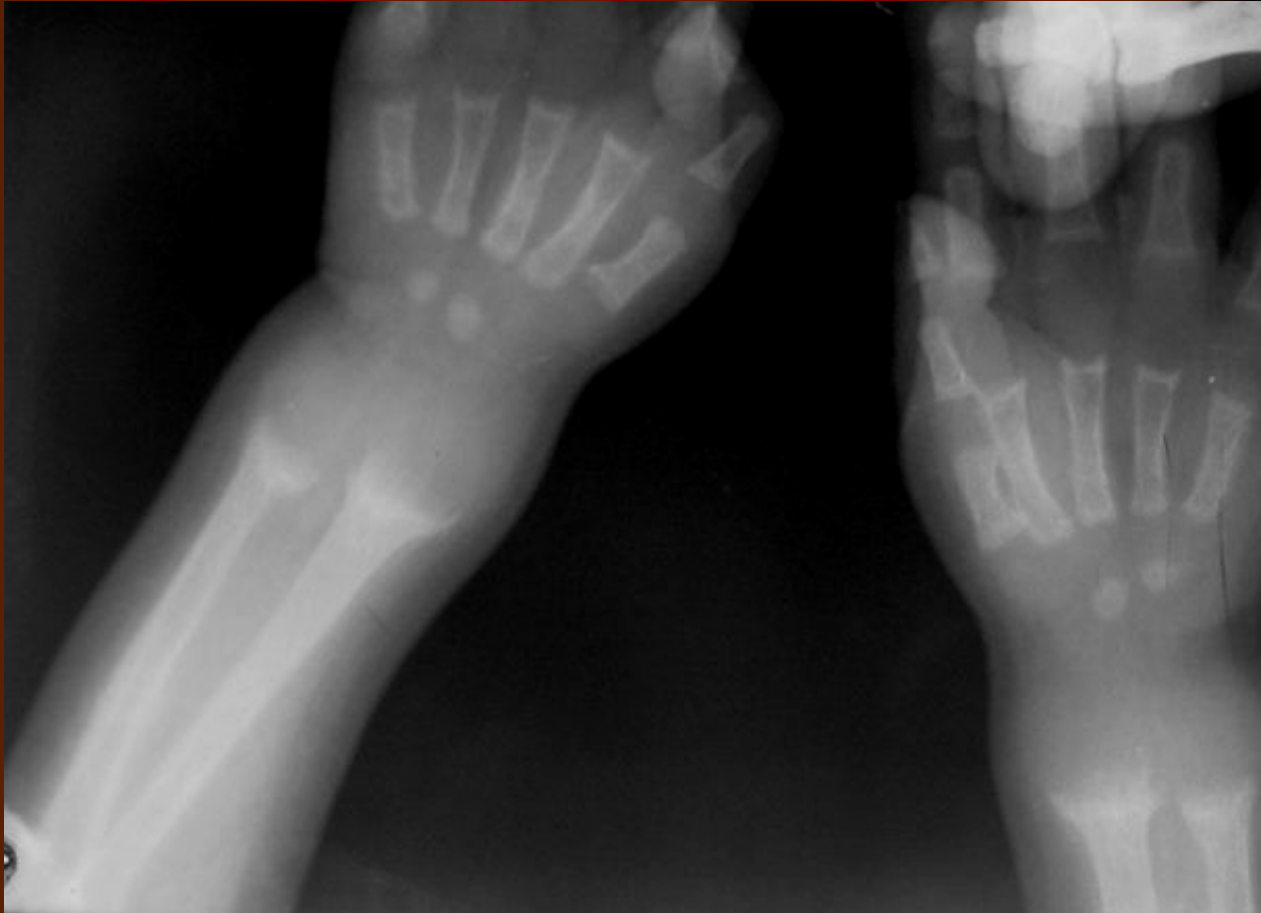

Boala oaselor de marmură

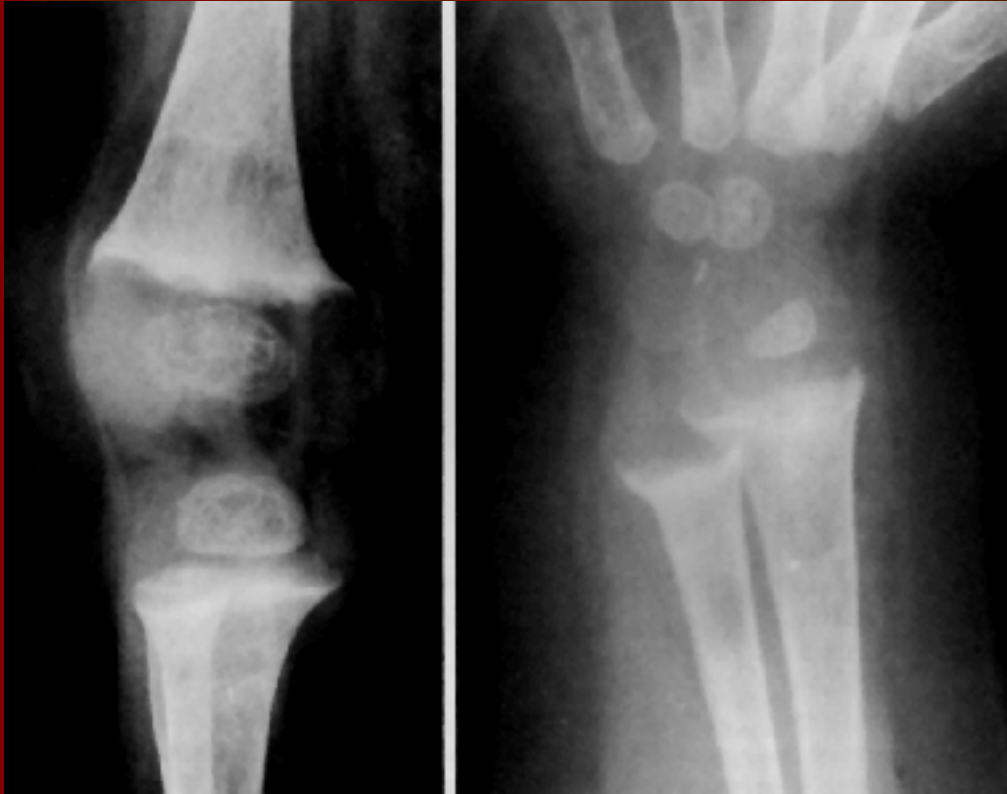

Rahitism

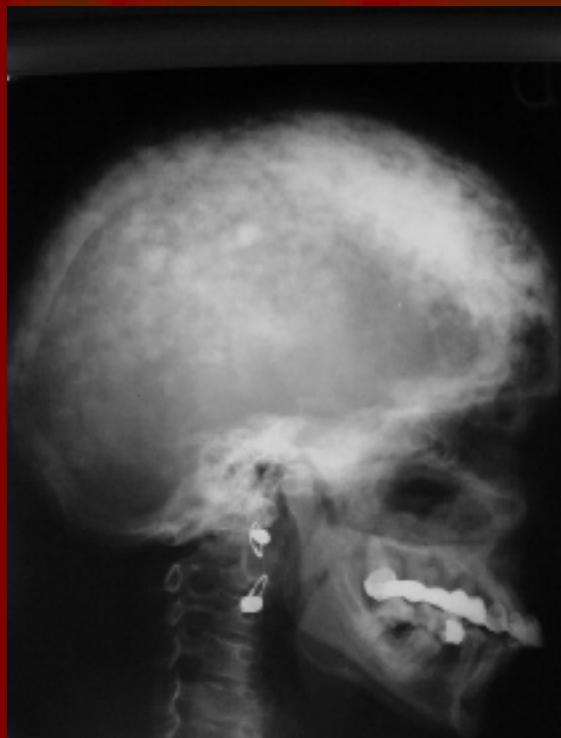
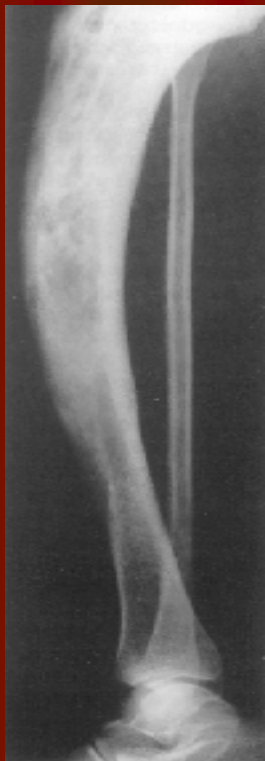
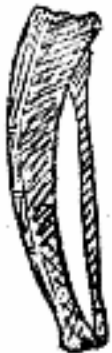

Rahitism

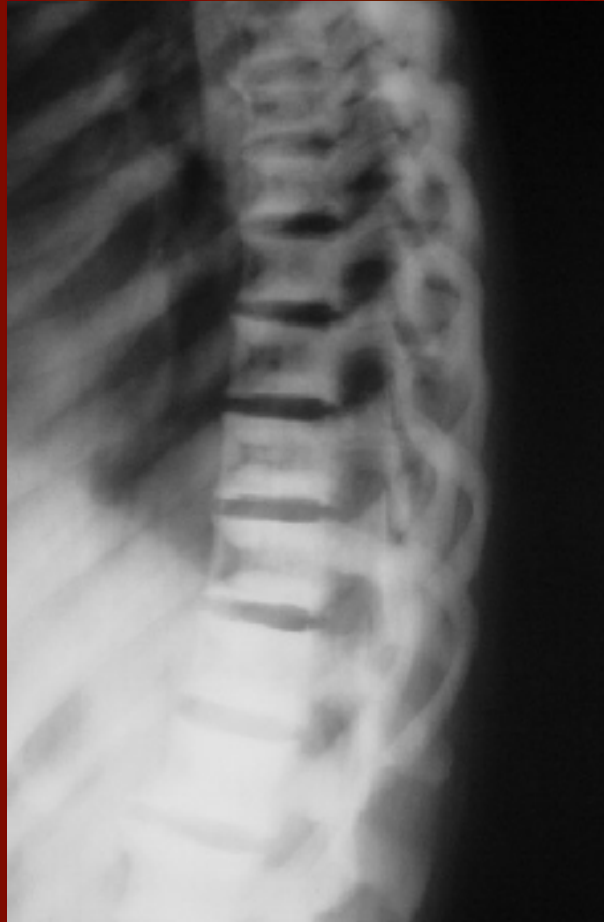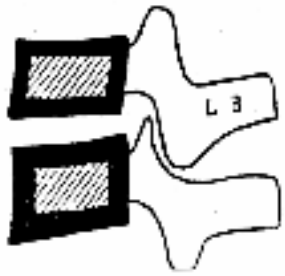


Rahitismul tardiv

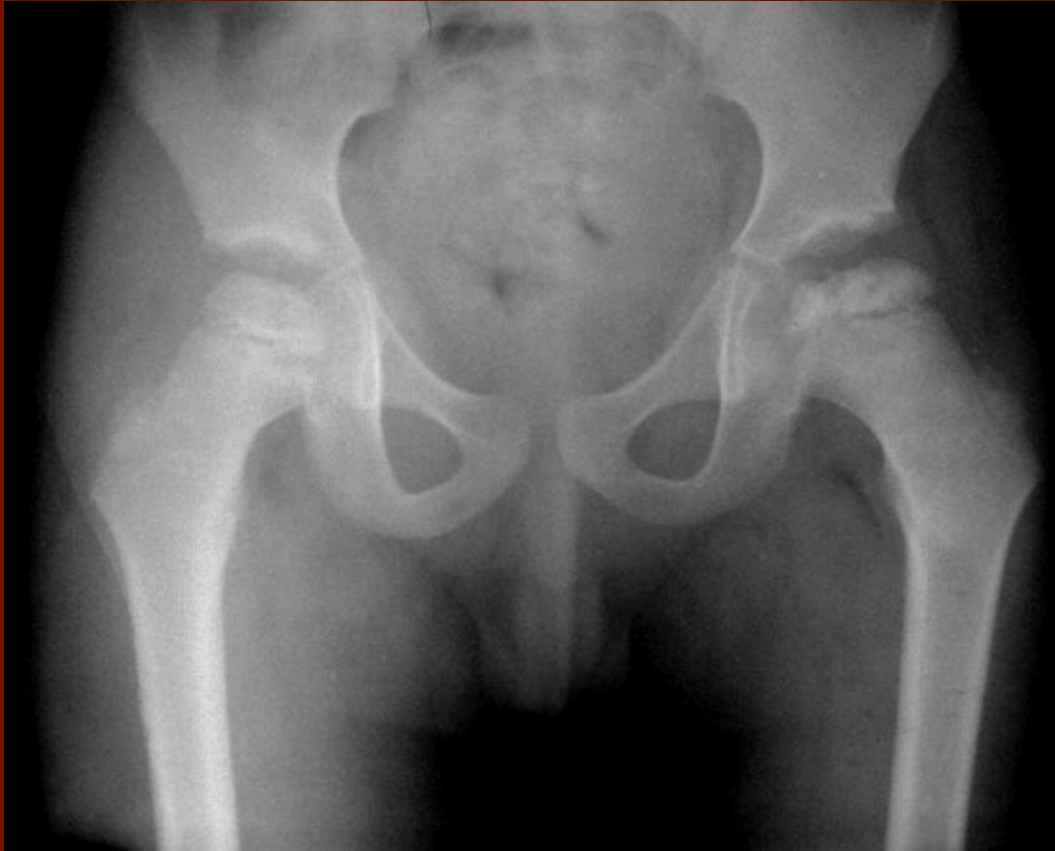

Boală Paget

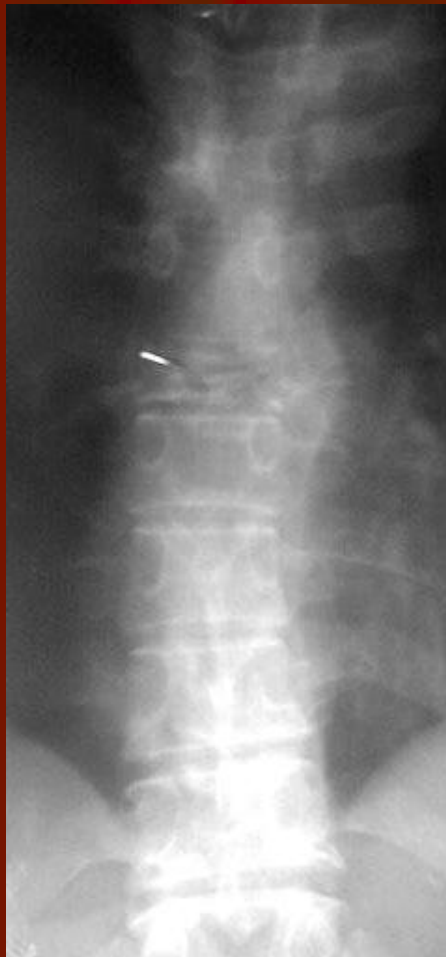




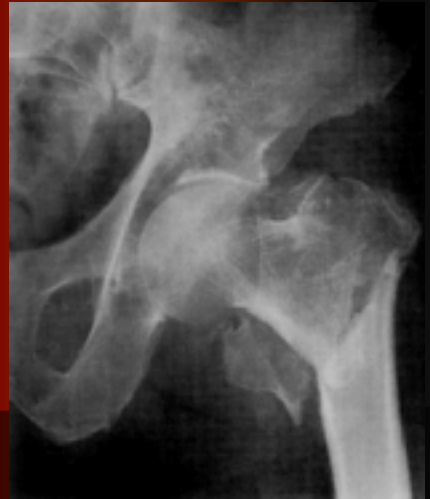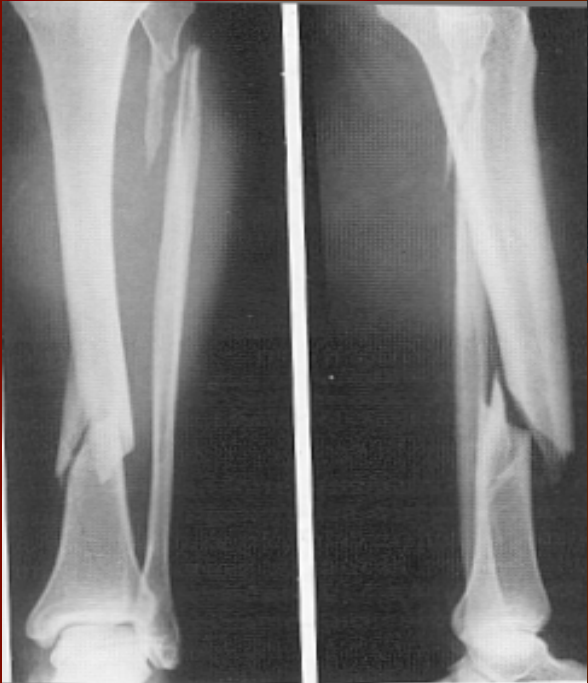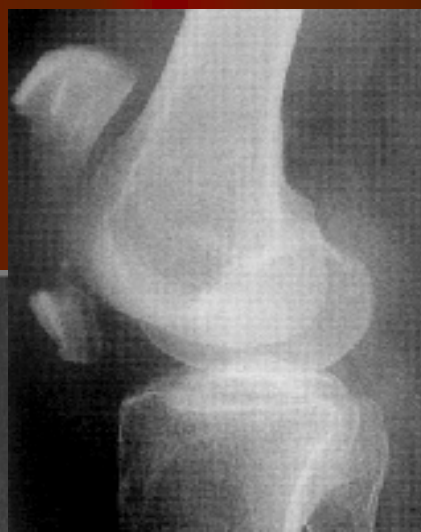Boală Paget



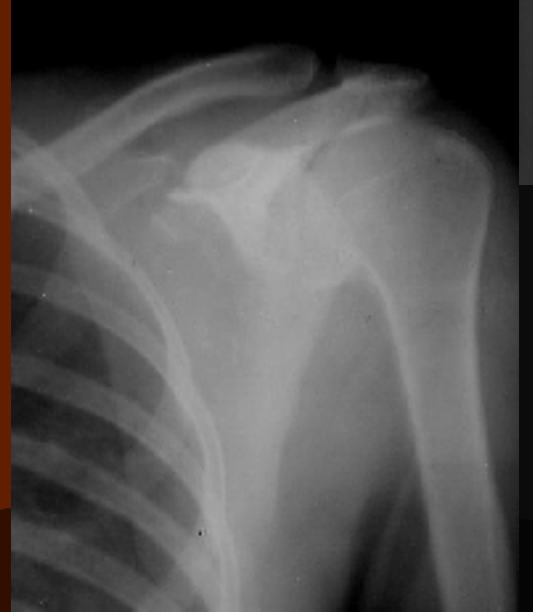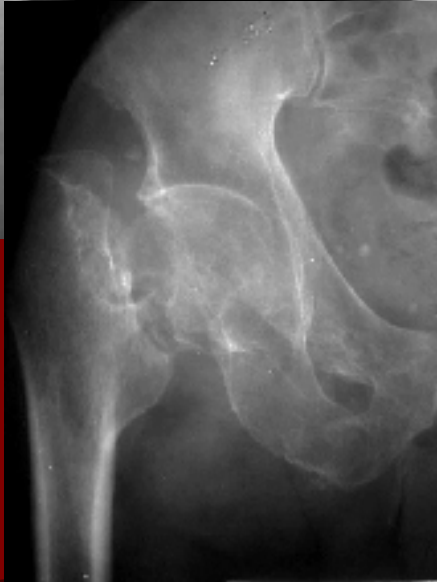
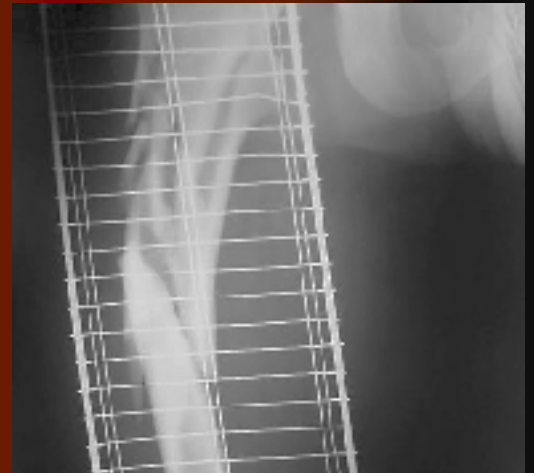
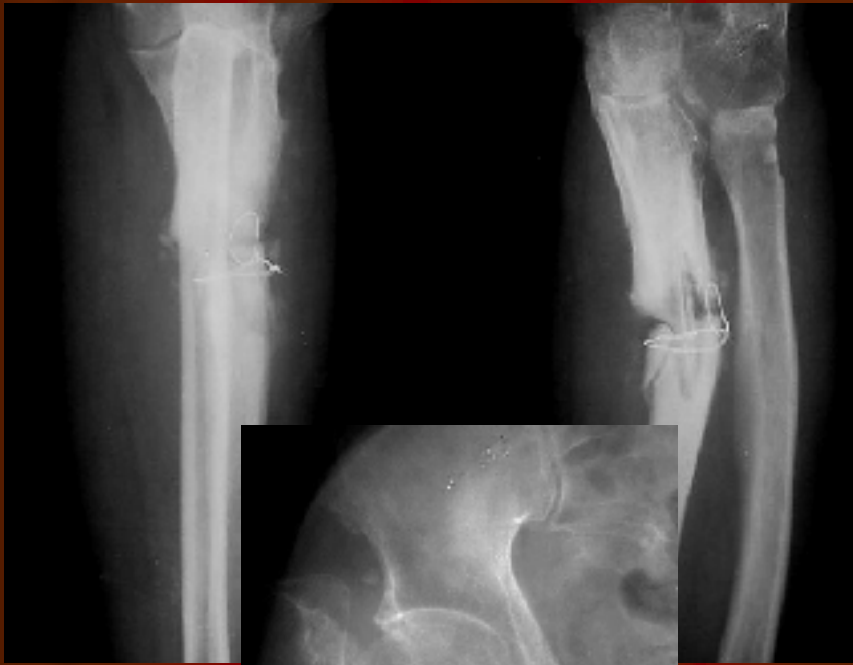Necroza osoasă aseptică de cap femural



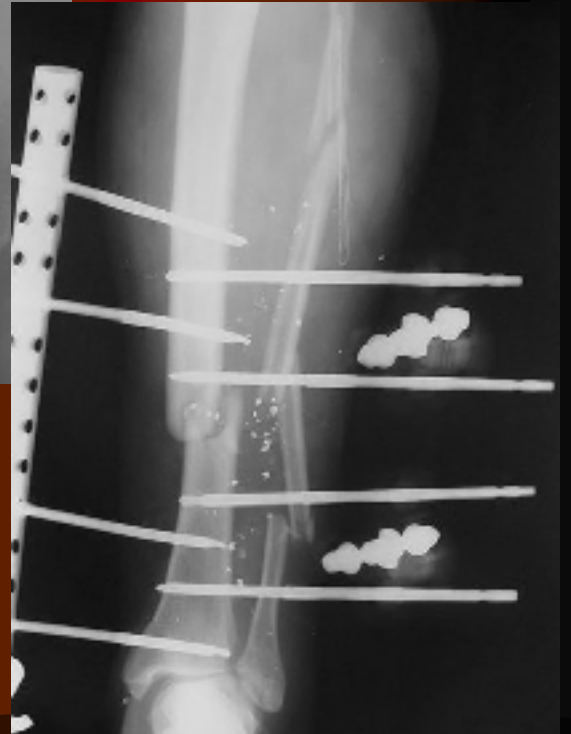
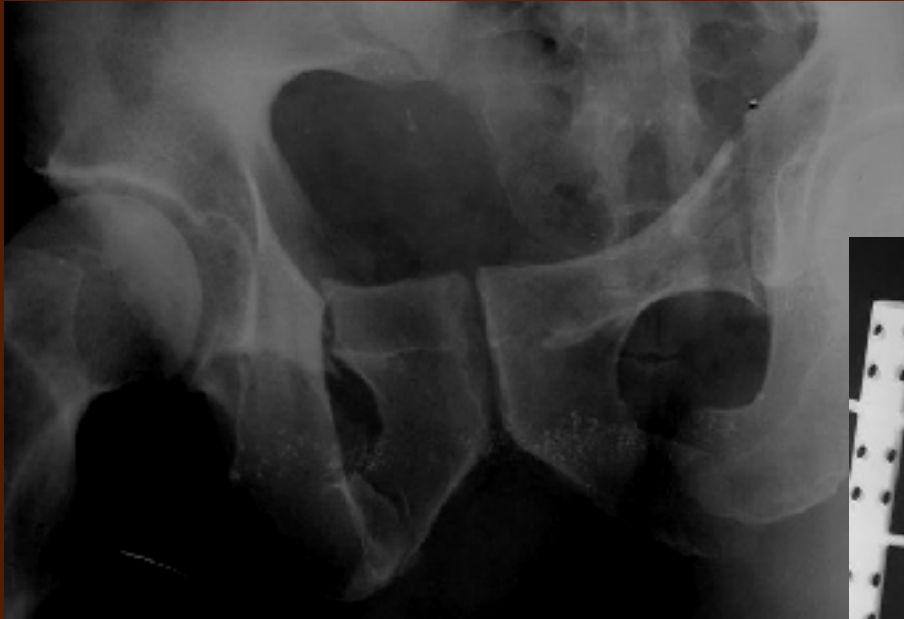Vertebră plană



Fracturi cominutive cu diferite localizări



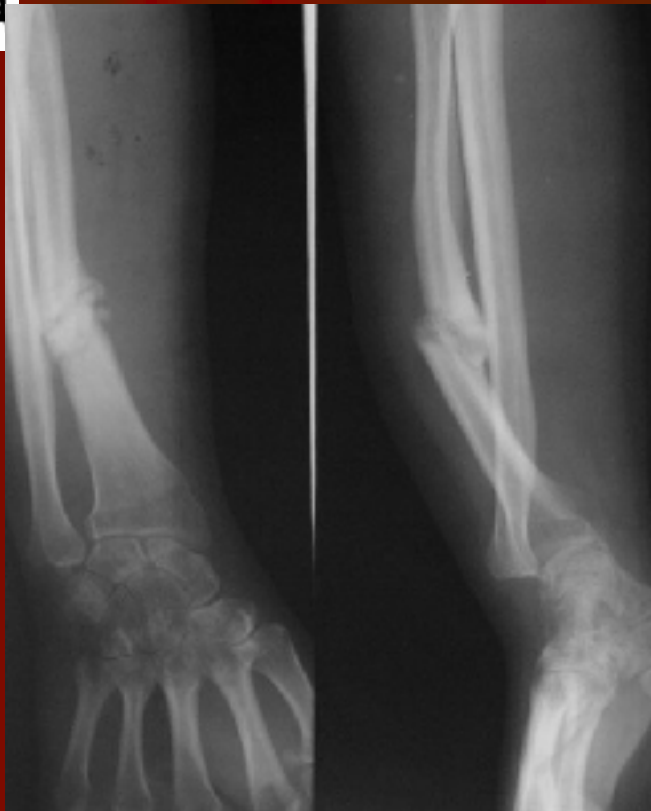Fracturi cu diferite localizări



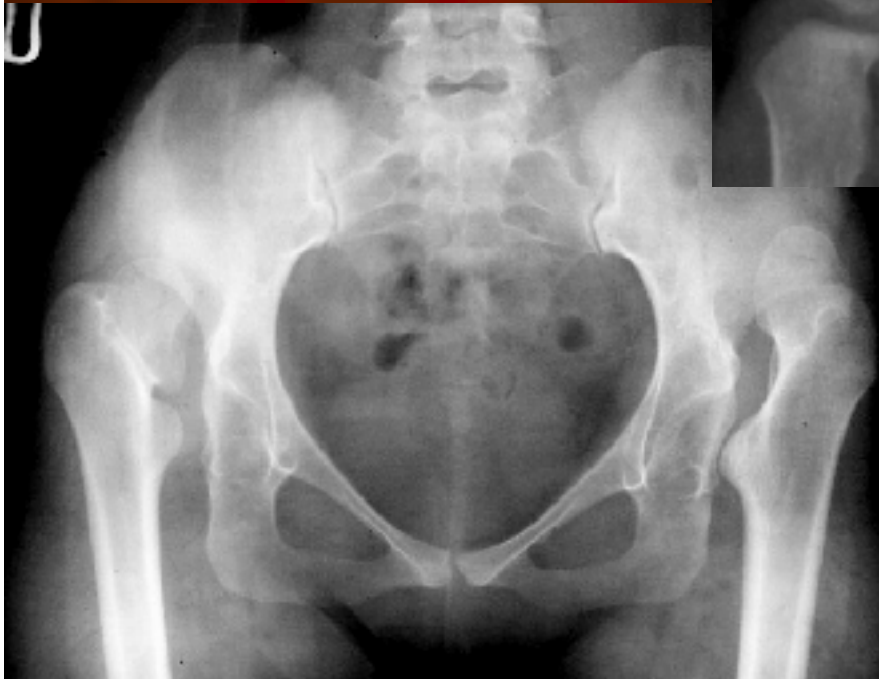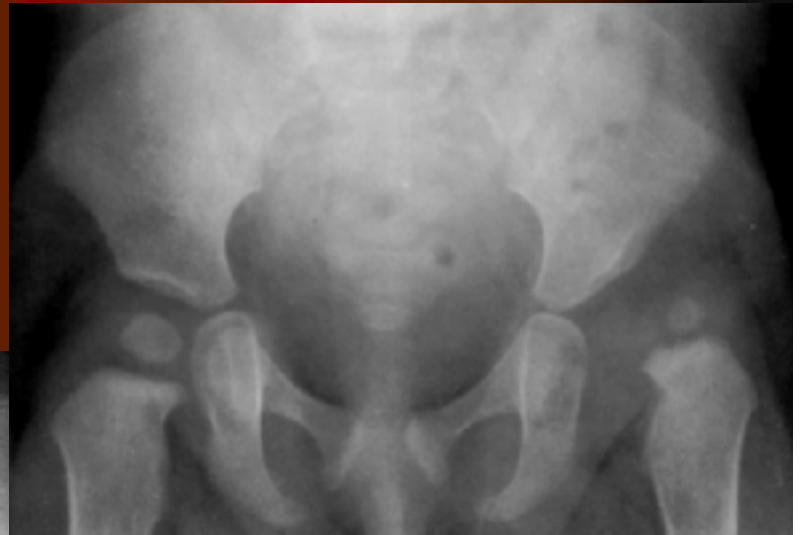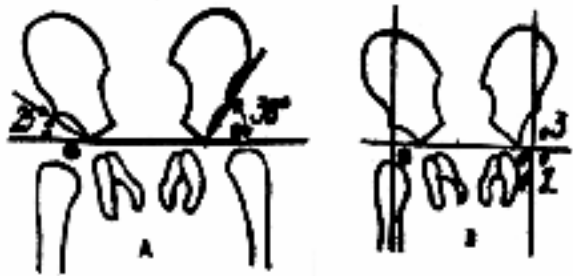
Fracturi multiple



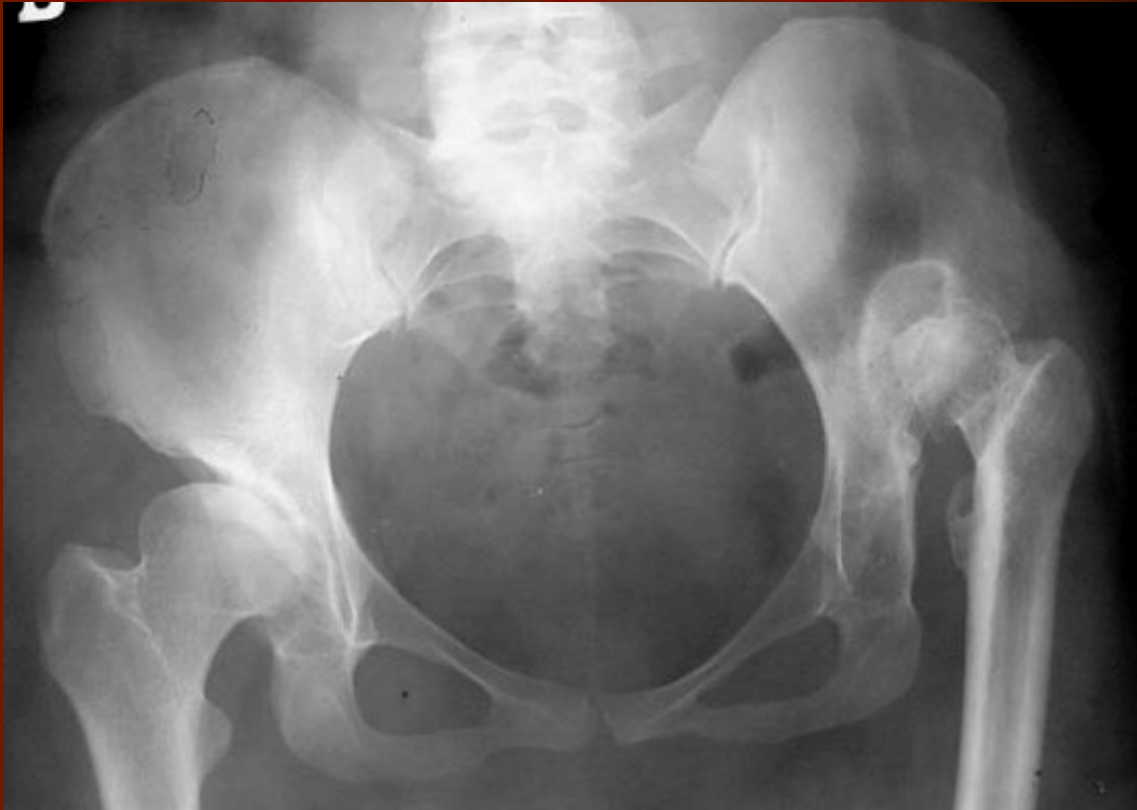Formarea calusului



Pseudartroză

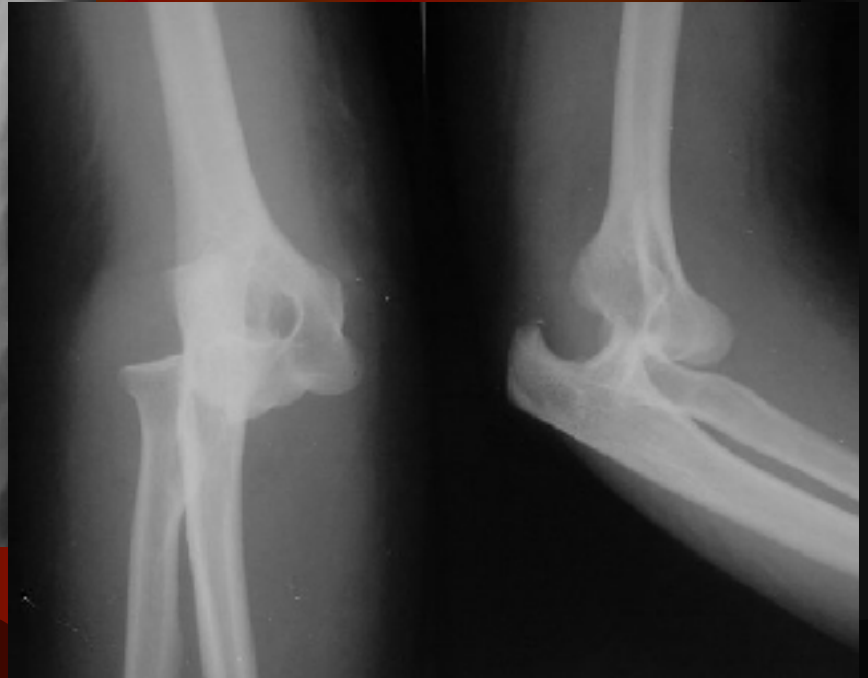
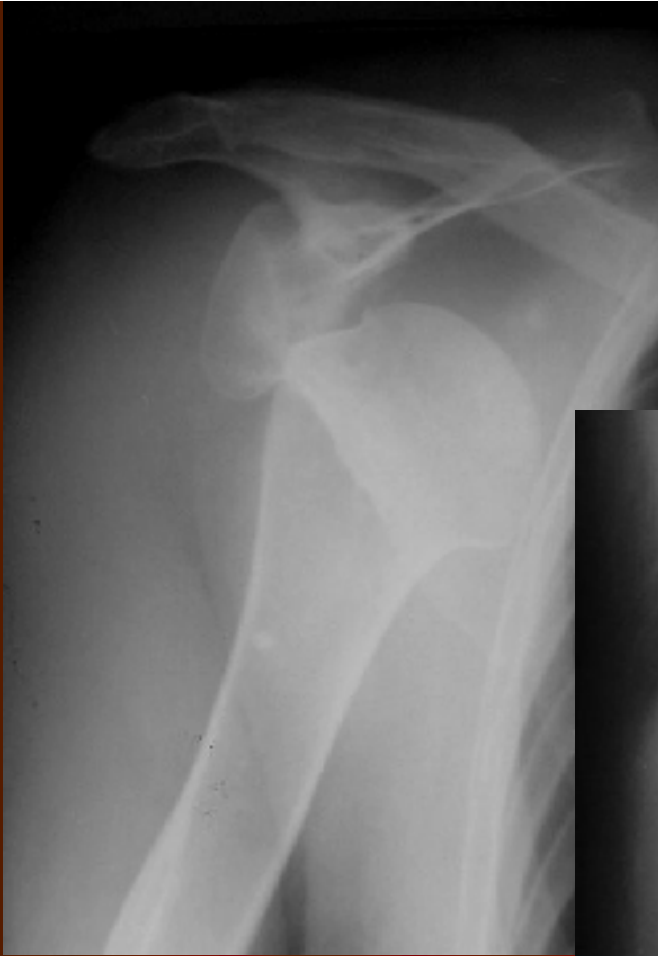
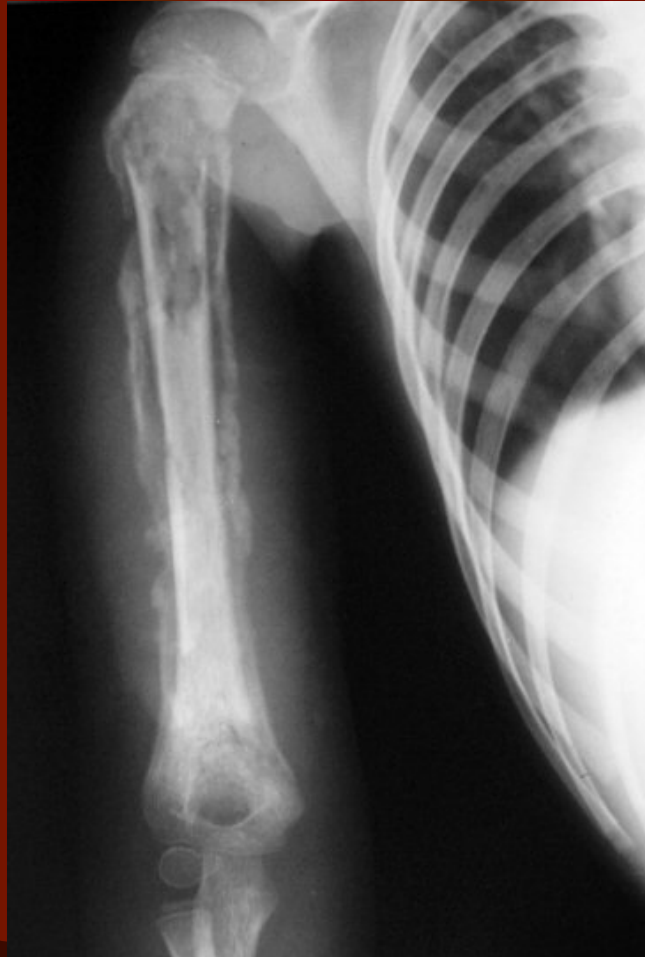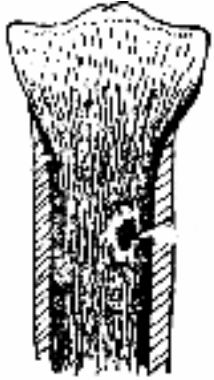
Luxație congenitală de șold



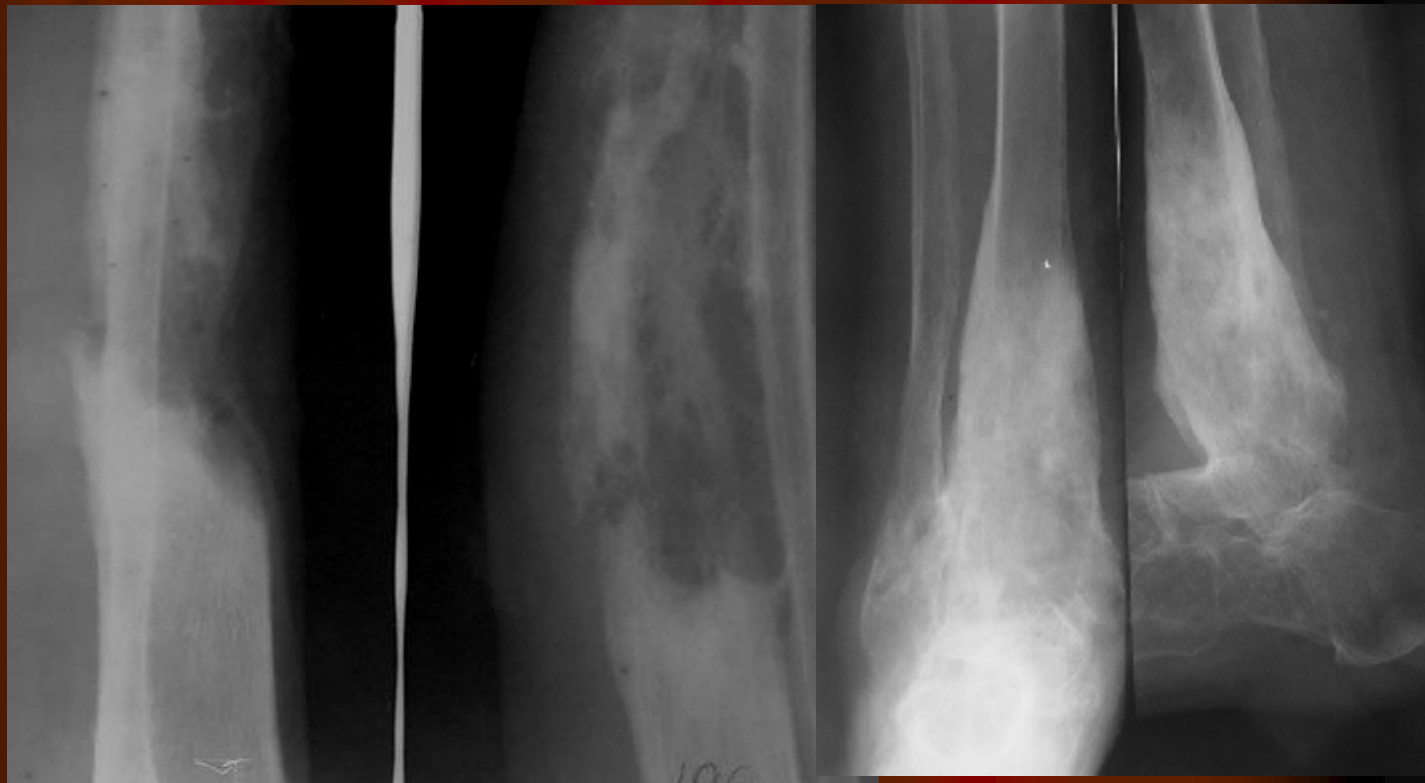
Luxație congenitală de șold

Luxații traumatiche

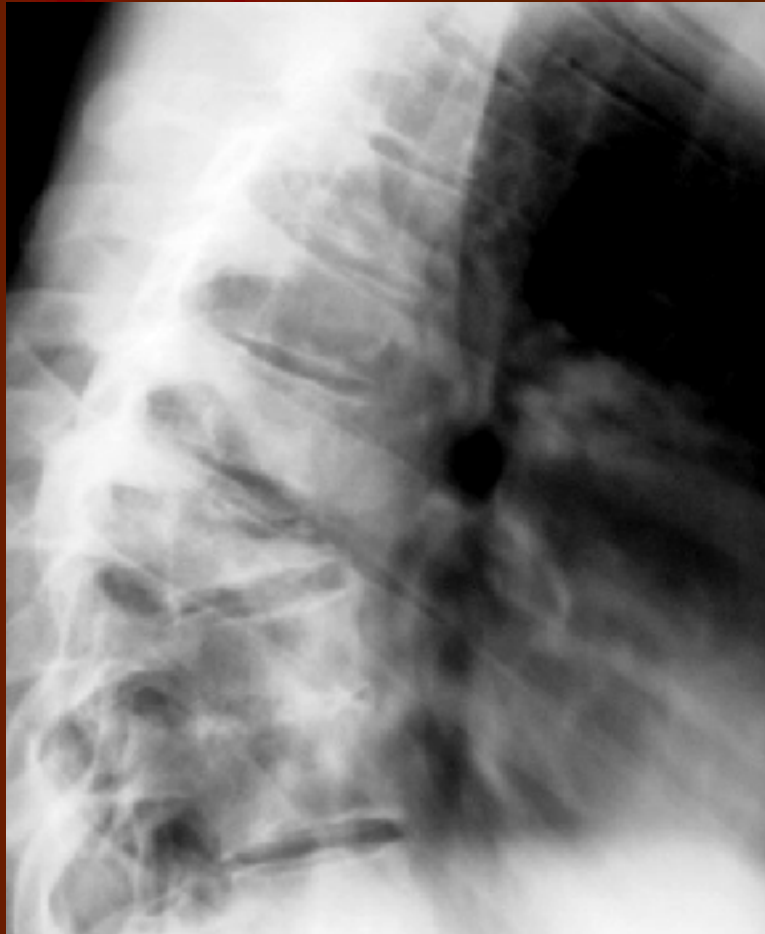
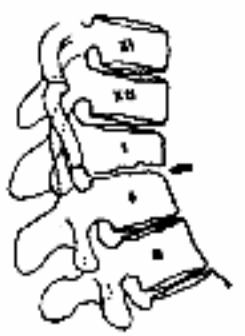


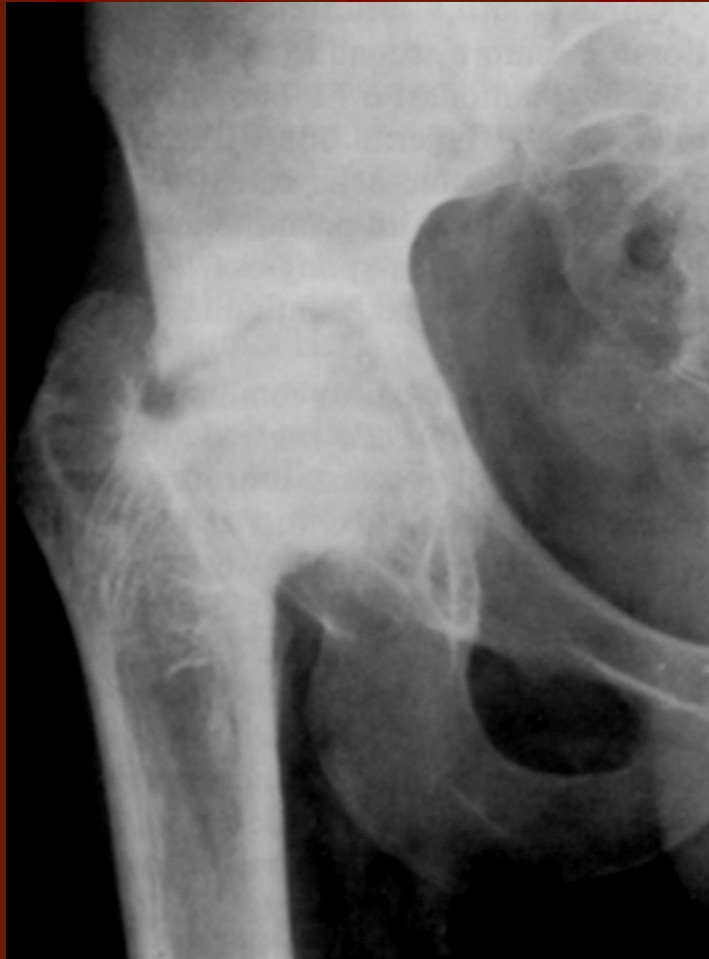Osteomieliță humerală



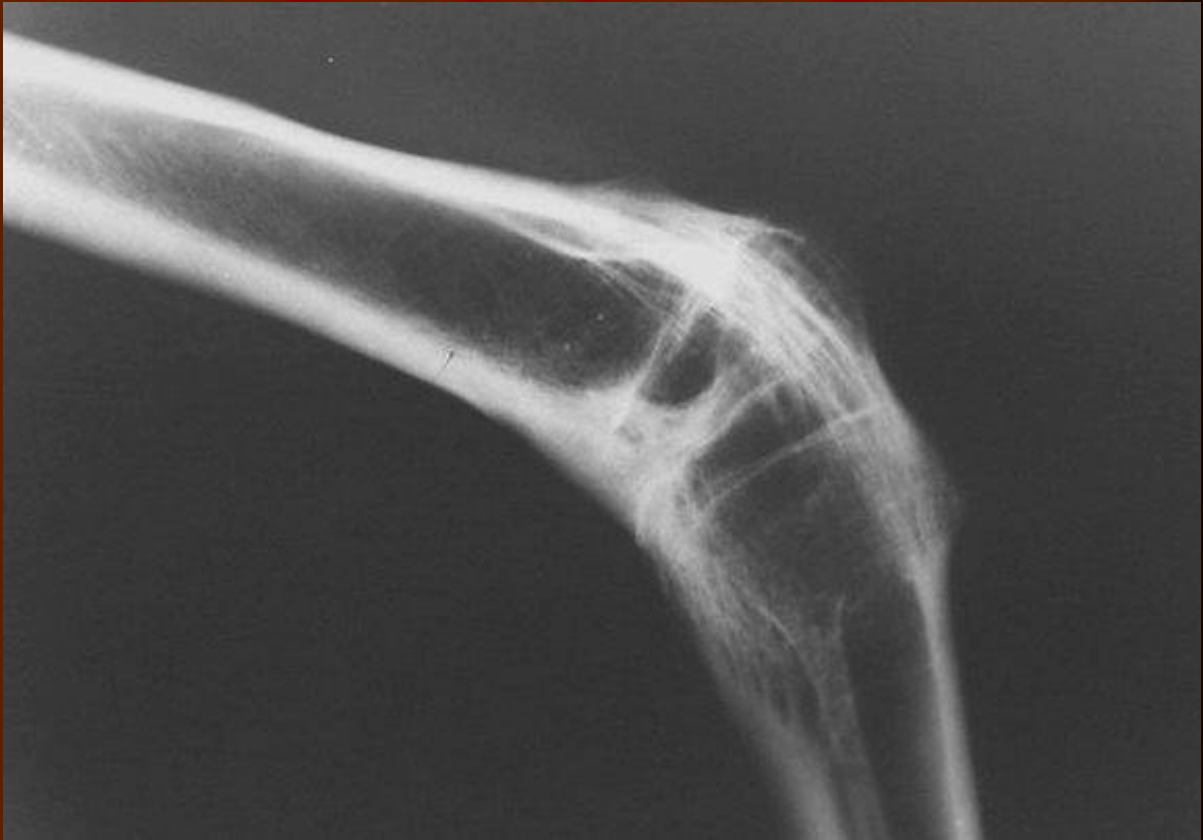Osteomieliță



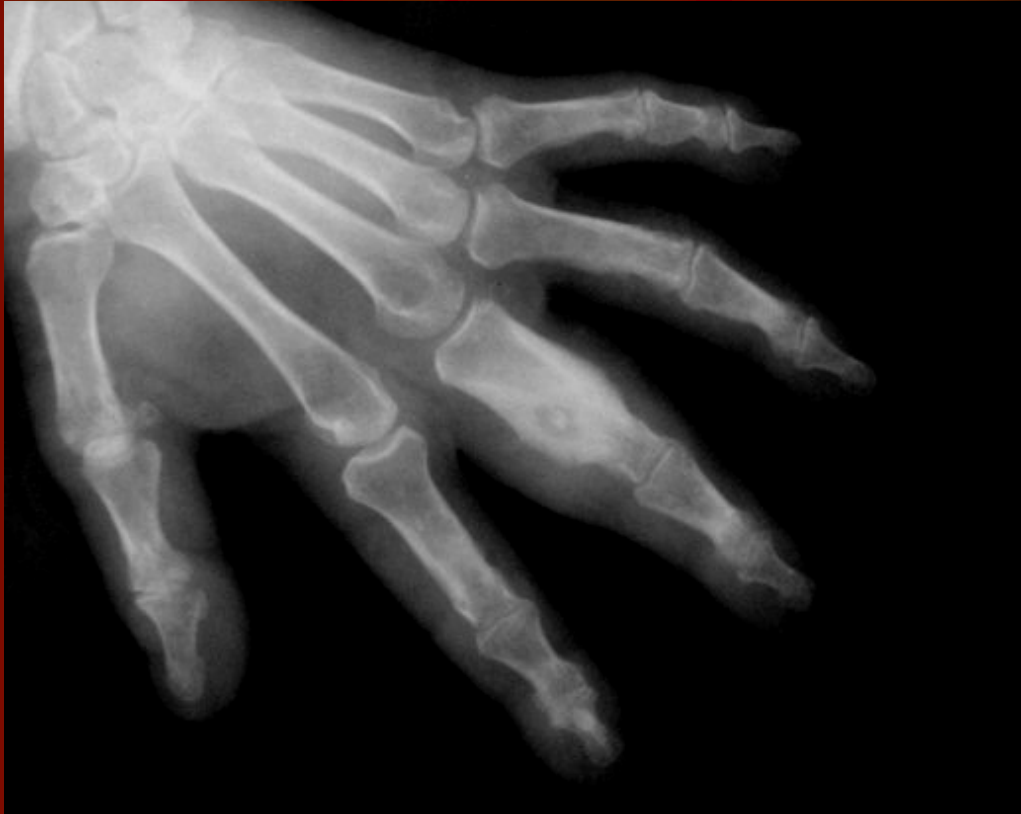Tasarea corpilor vertebrali



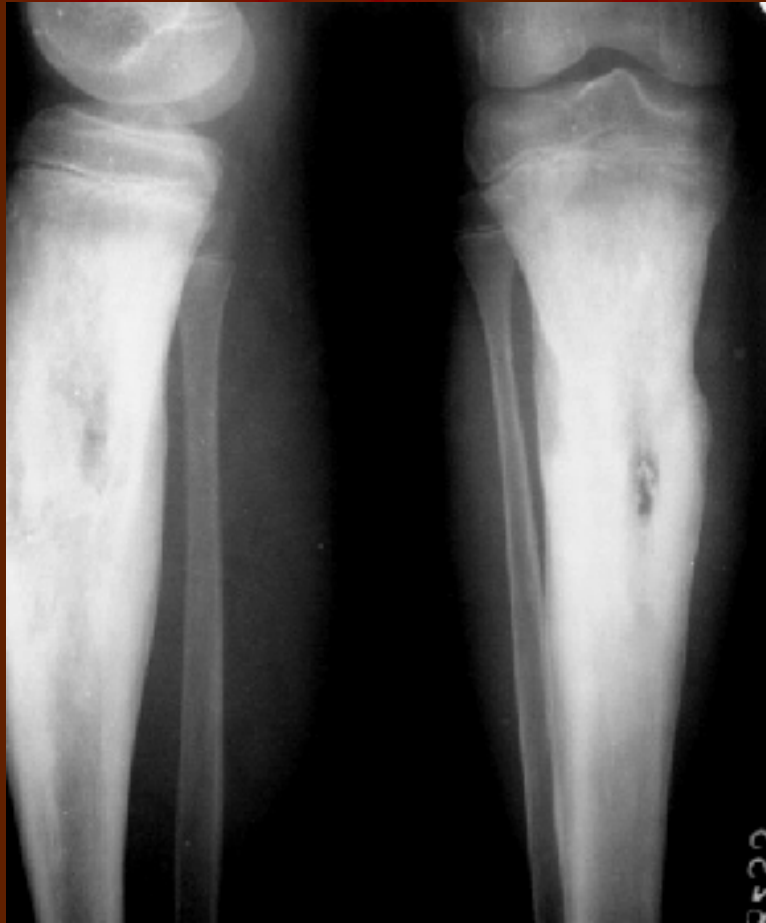Coxalgia



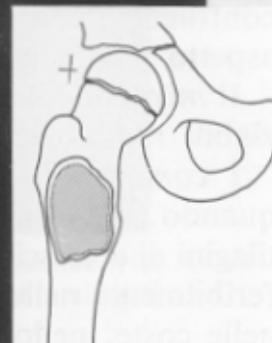
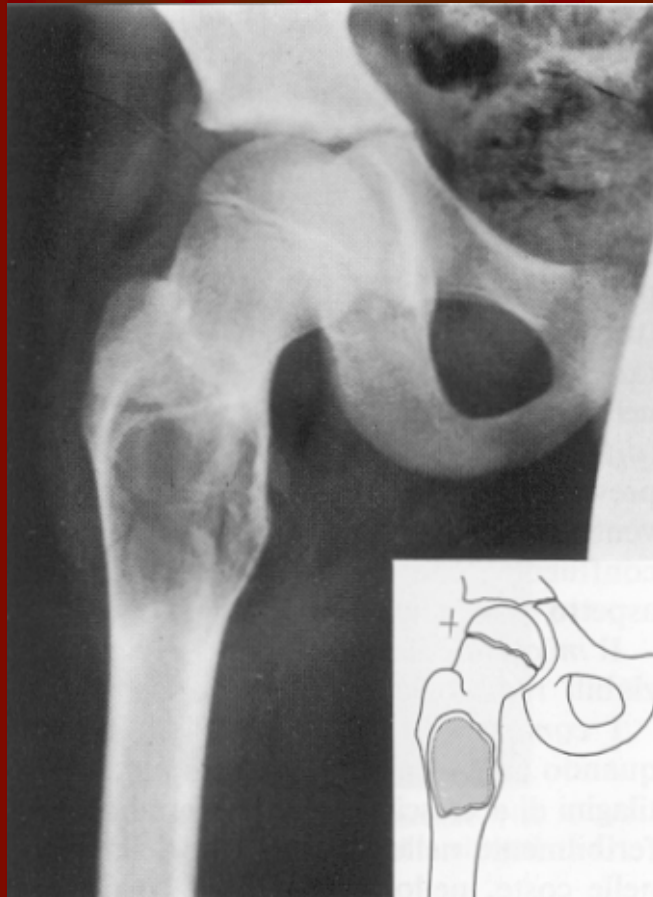TB genunchi



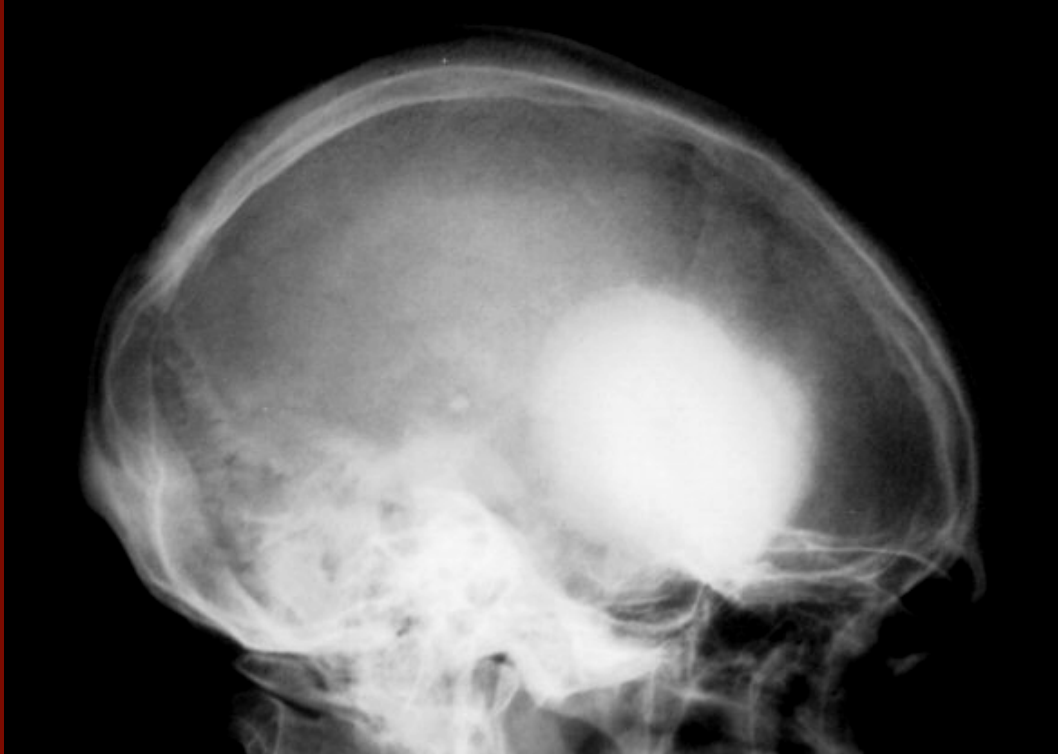
Spina ventosa



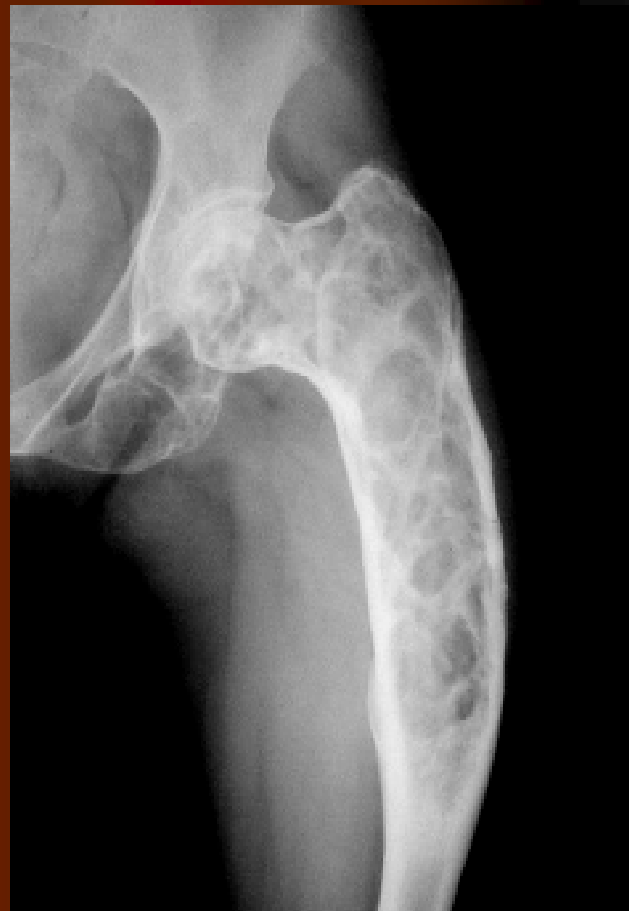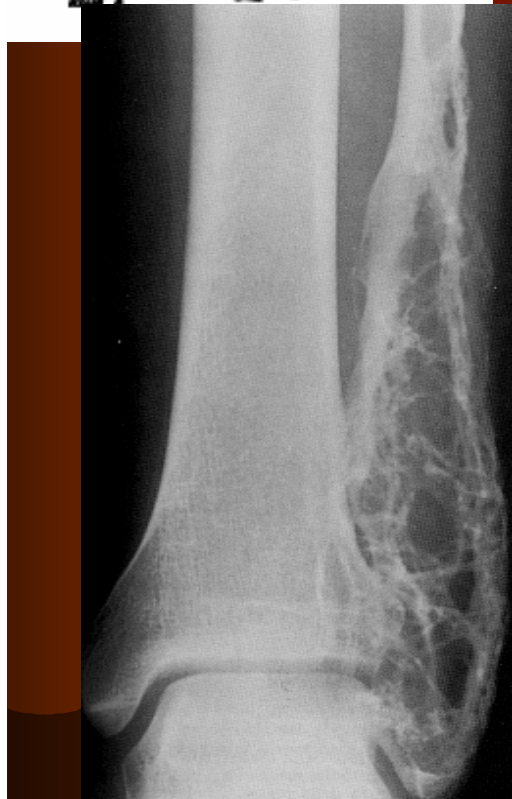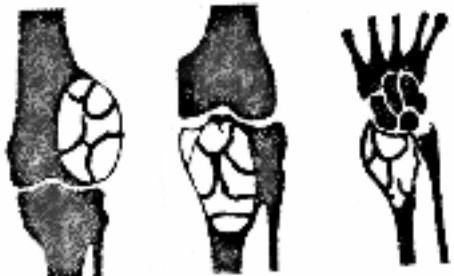Osteomieliita luetică



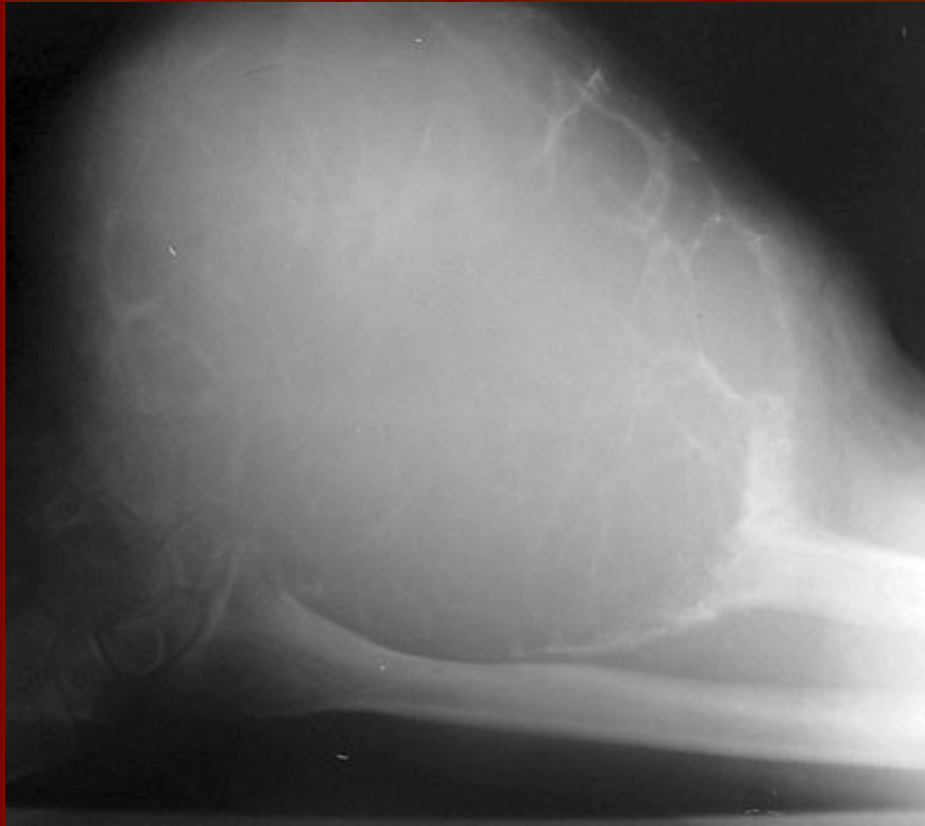Chistul osos



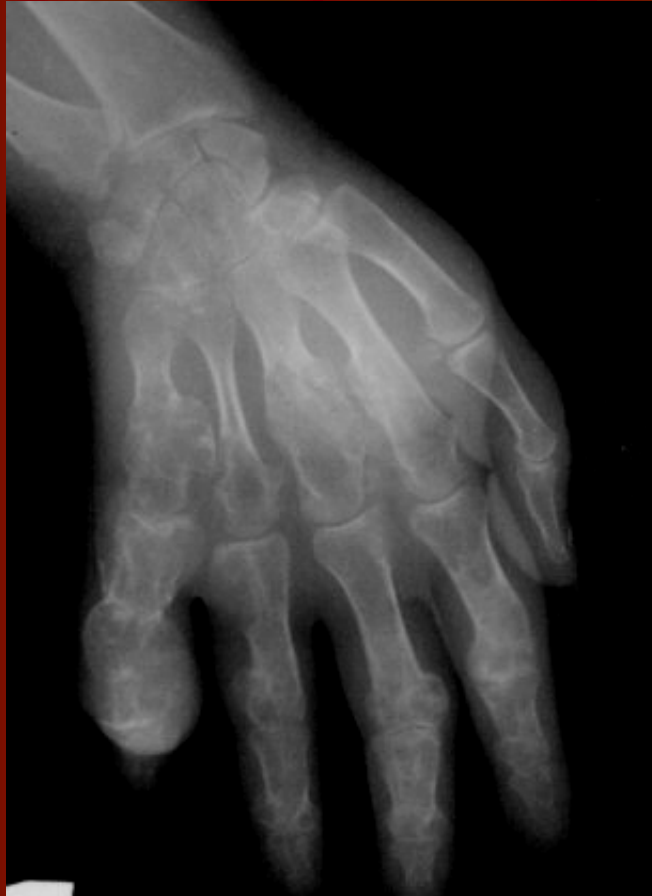Osteom cranian



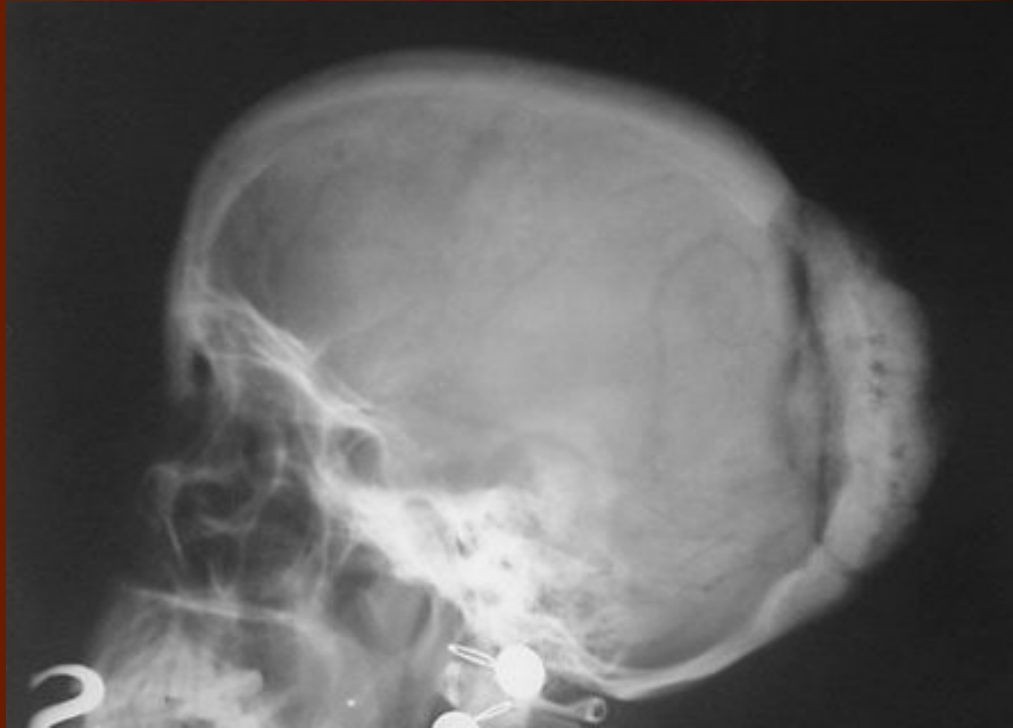Tumora cu mieloplaxe



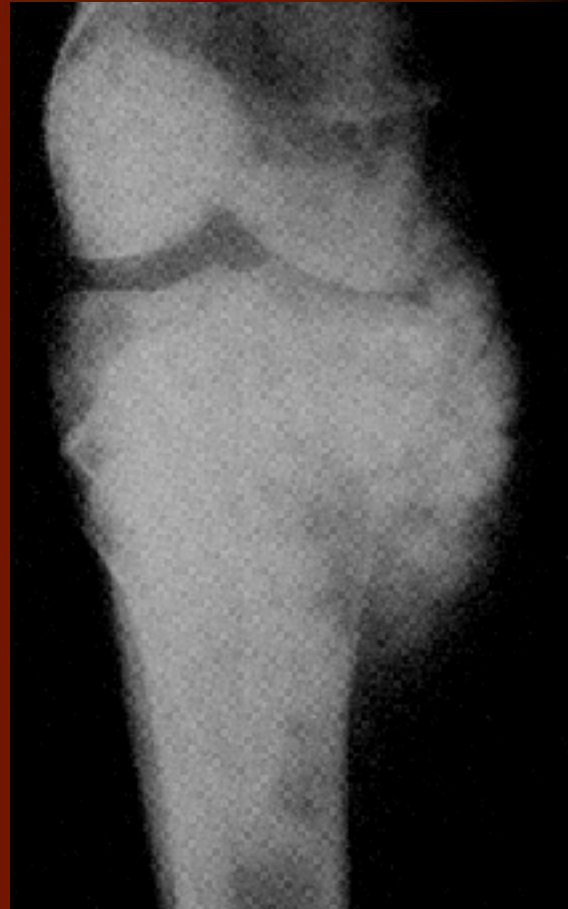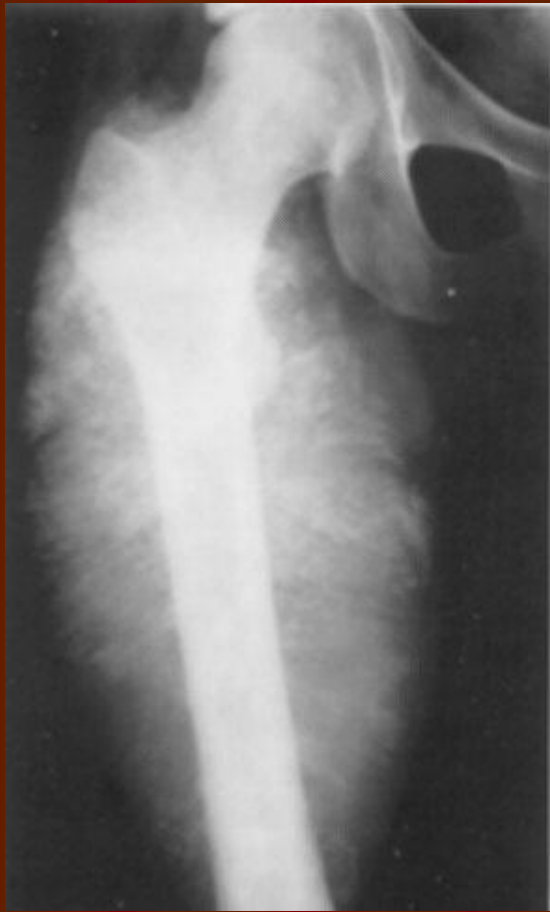Tumora cu mieloplaxe



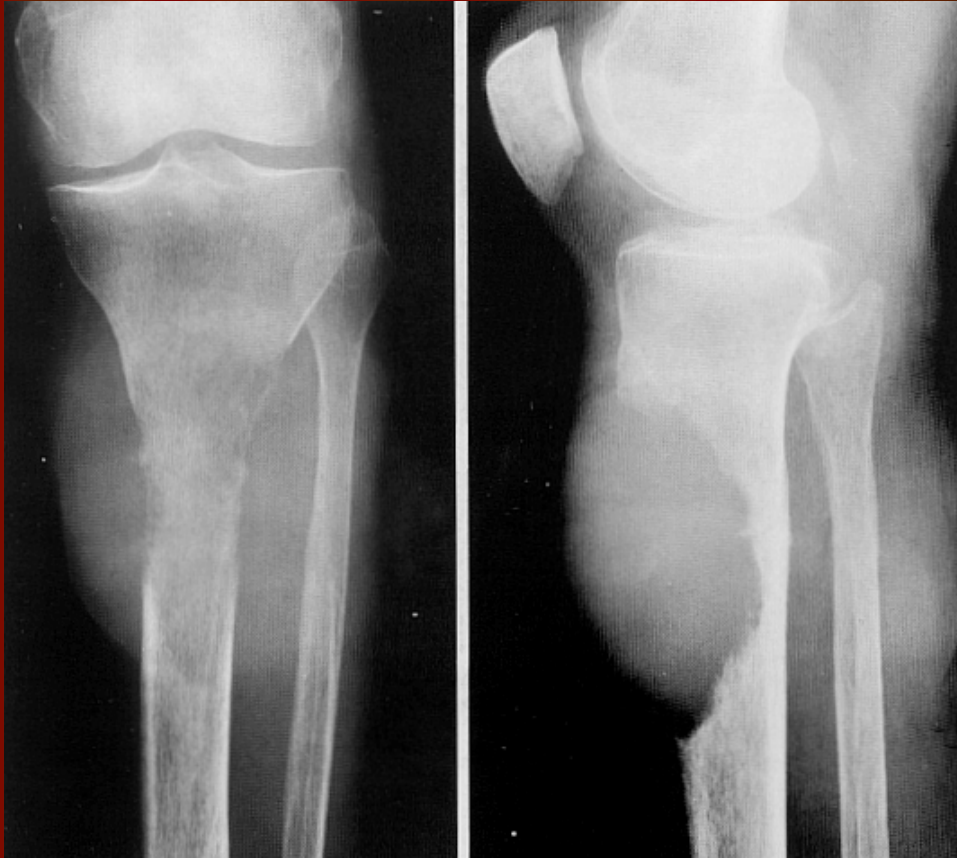Encondromul



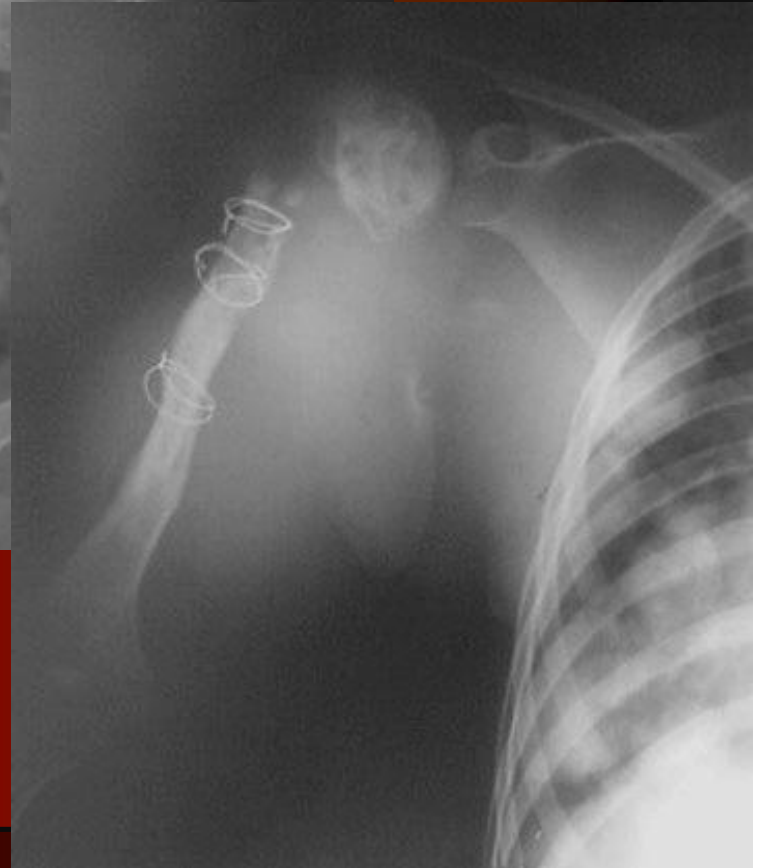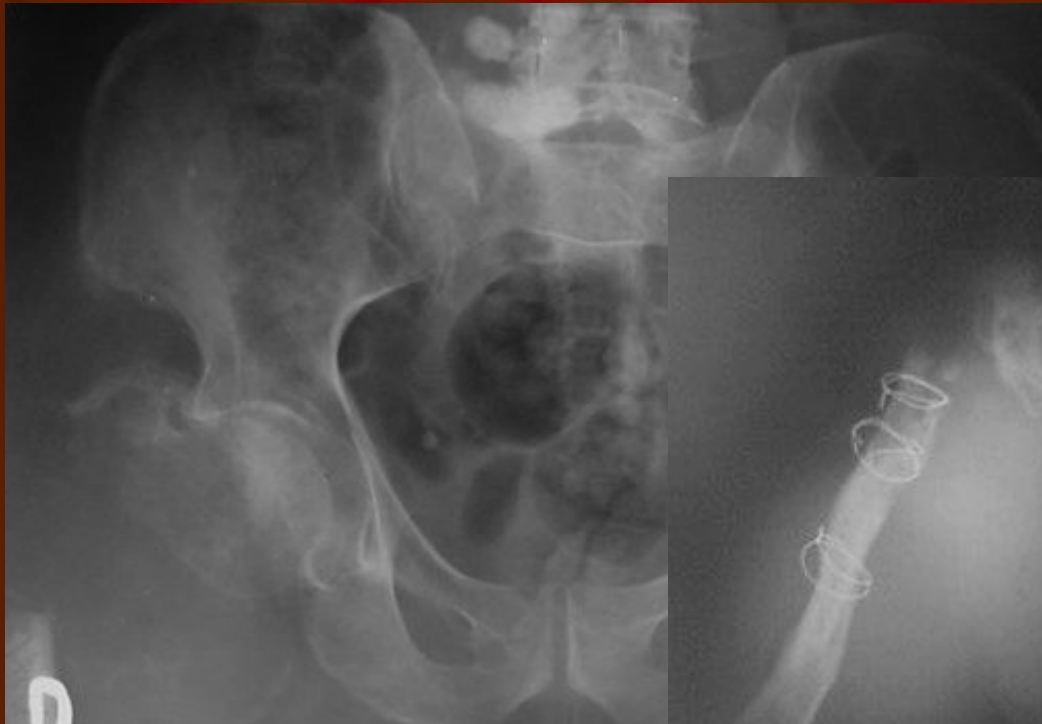Sarcomul osteogenetic



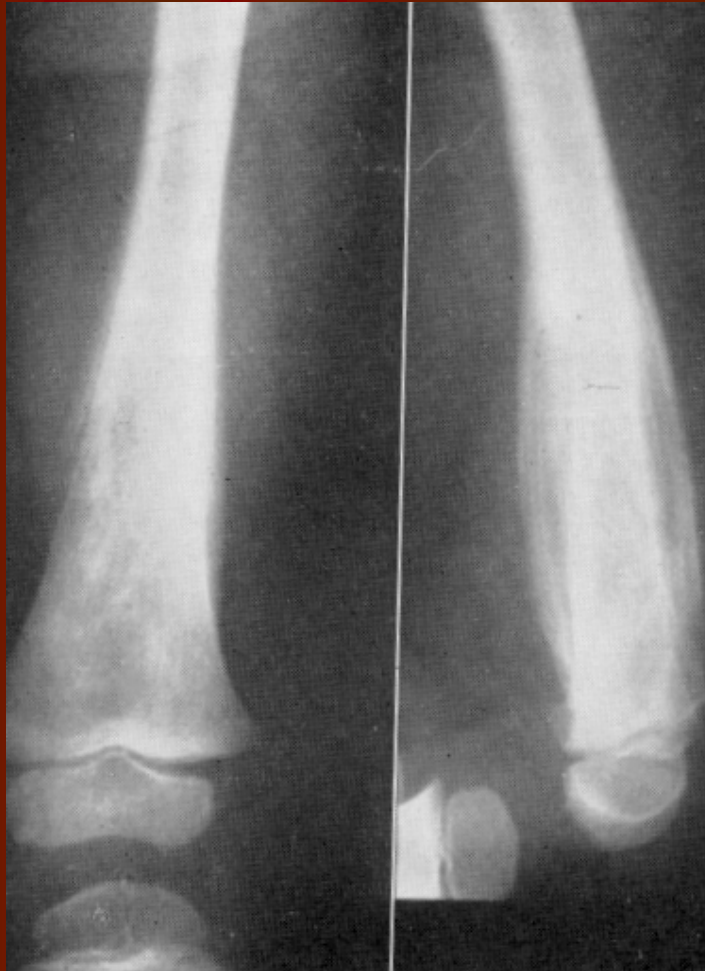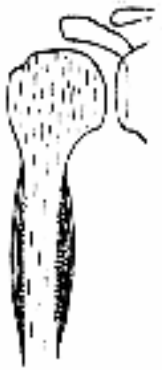Sarcomul osteogenetic



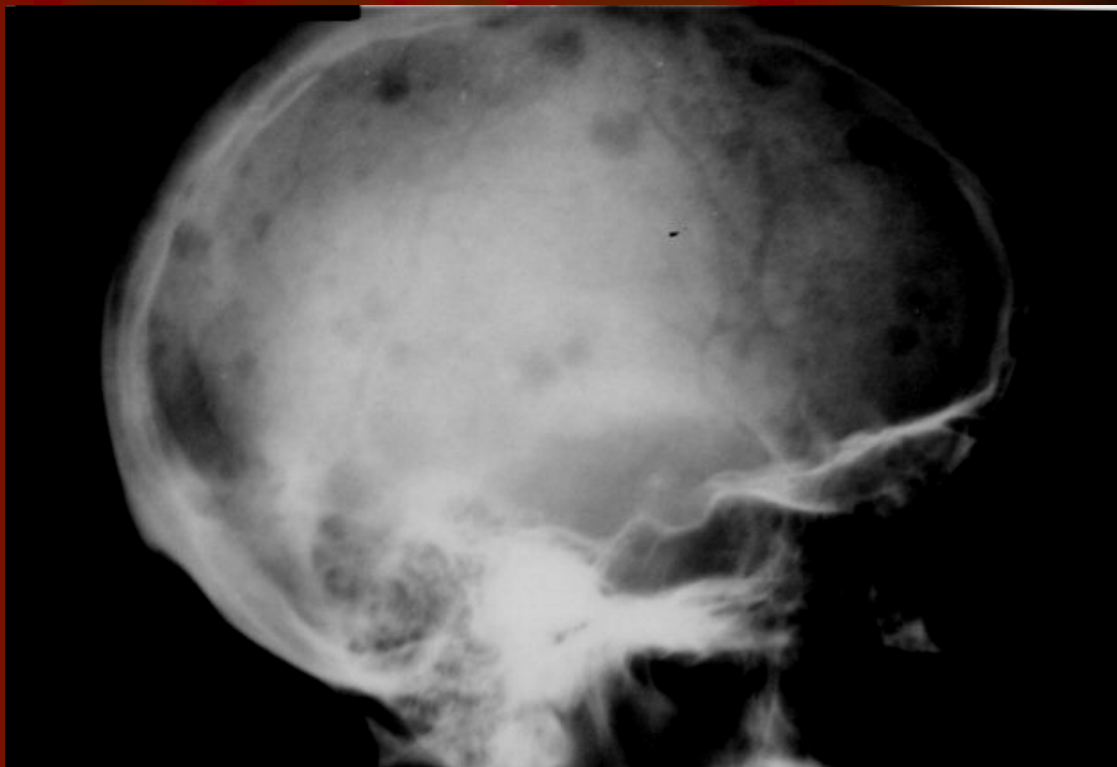
Osteosarcomul osteolitic



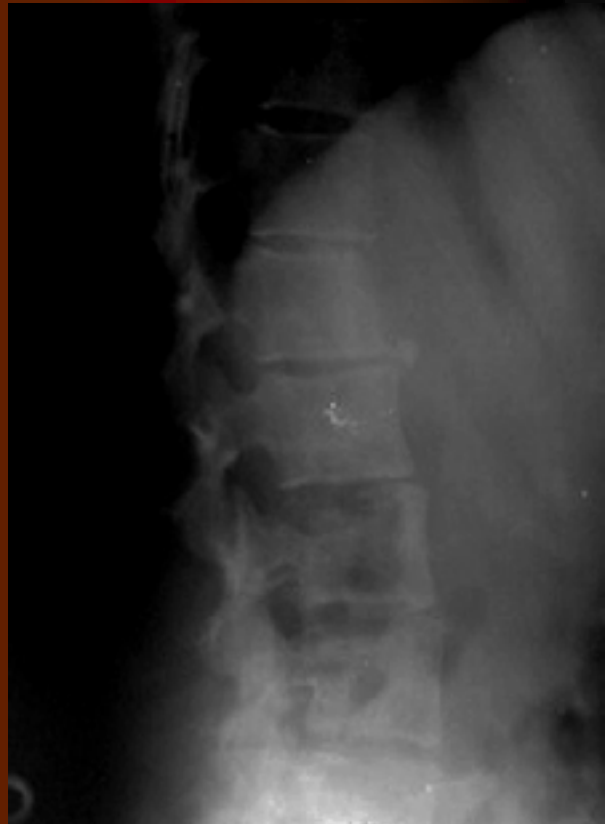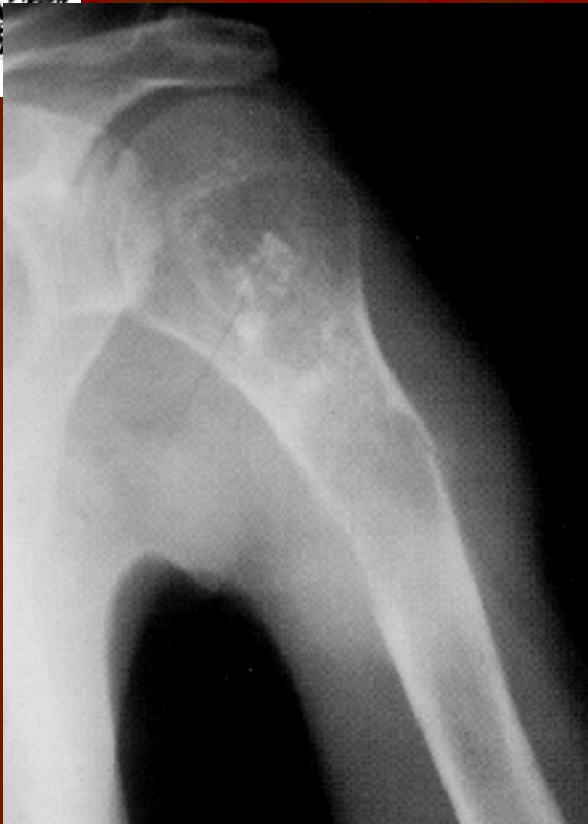Osteosarcomul osteolitic



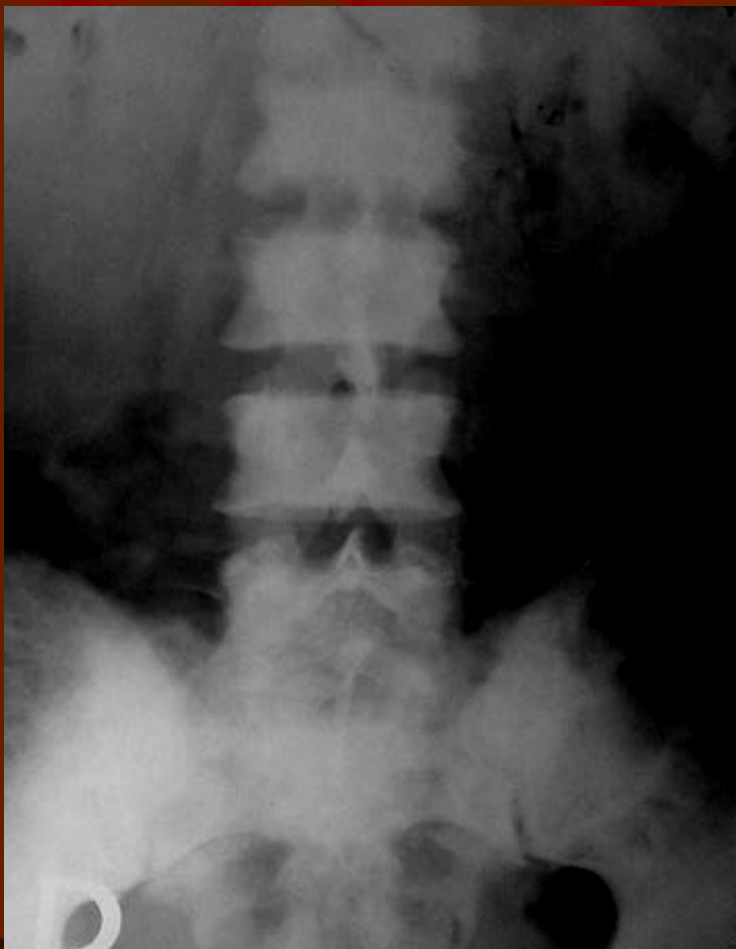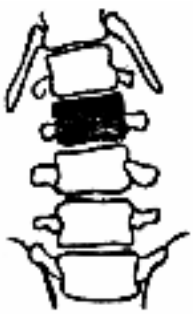Sarcomul Ewing



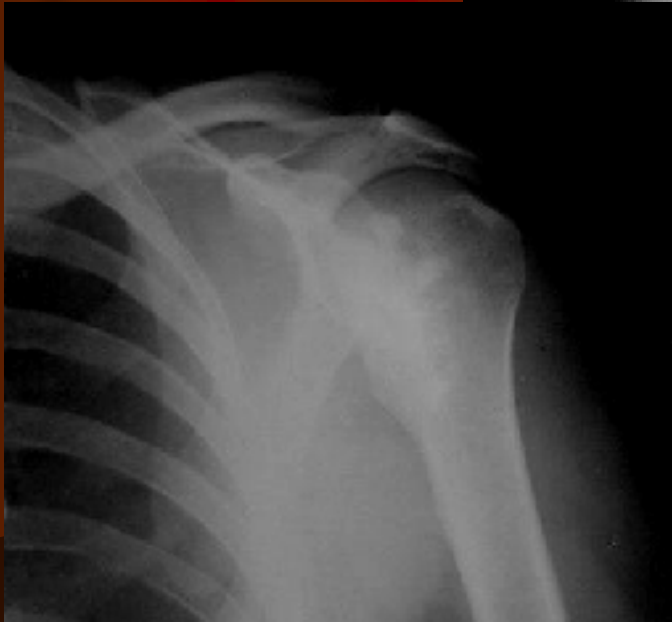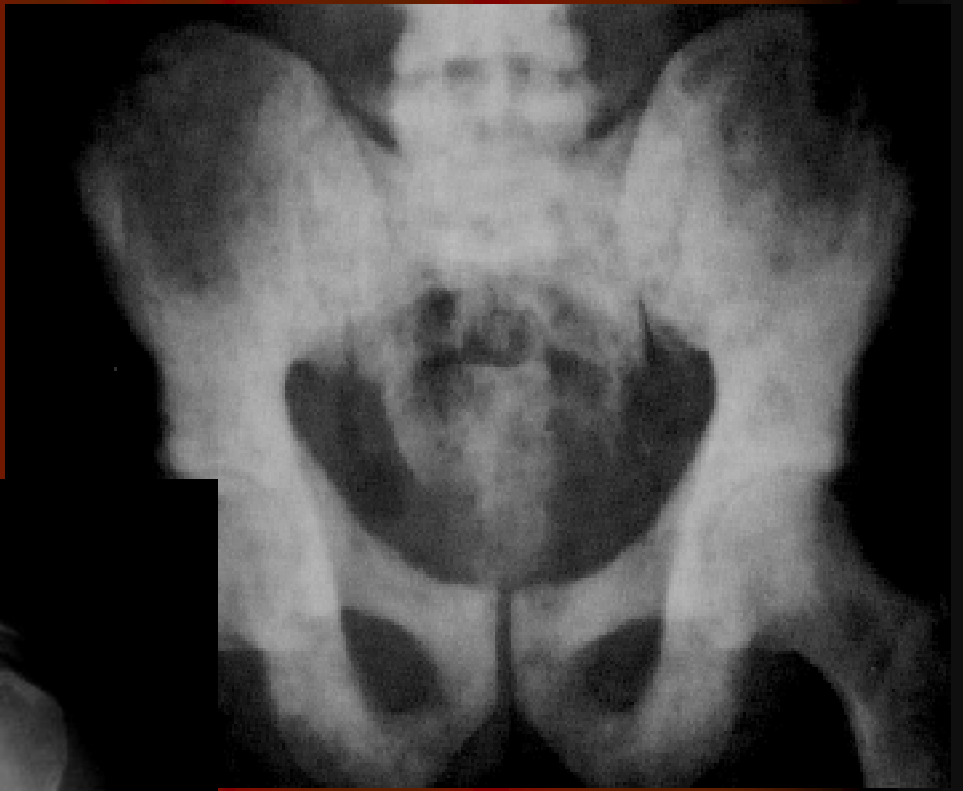Mielomul multiplu



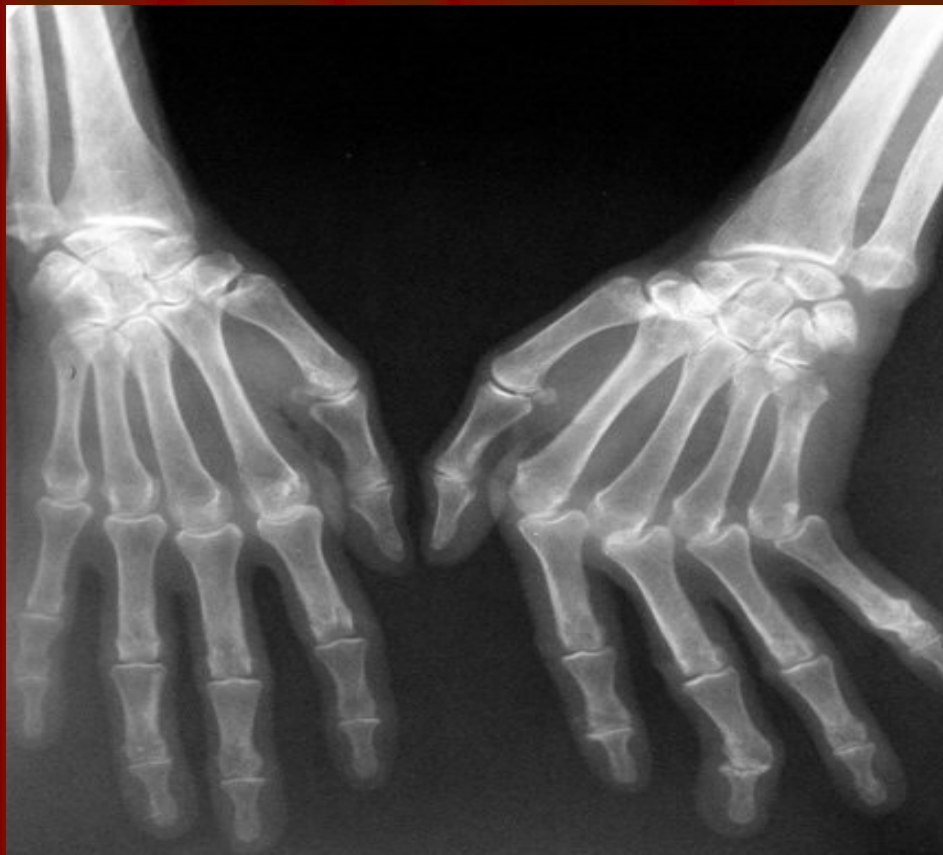Metastaze osteolitice



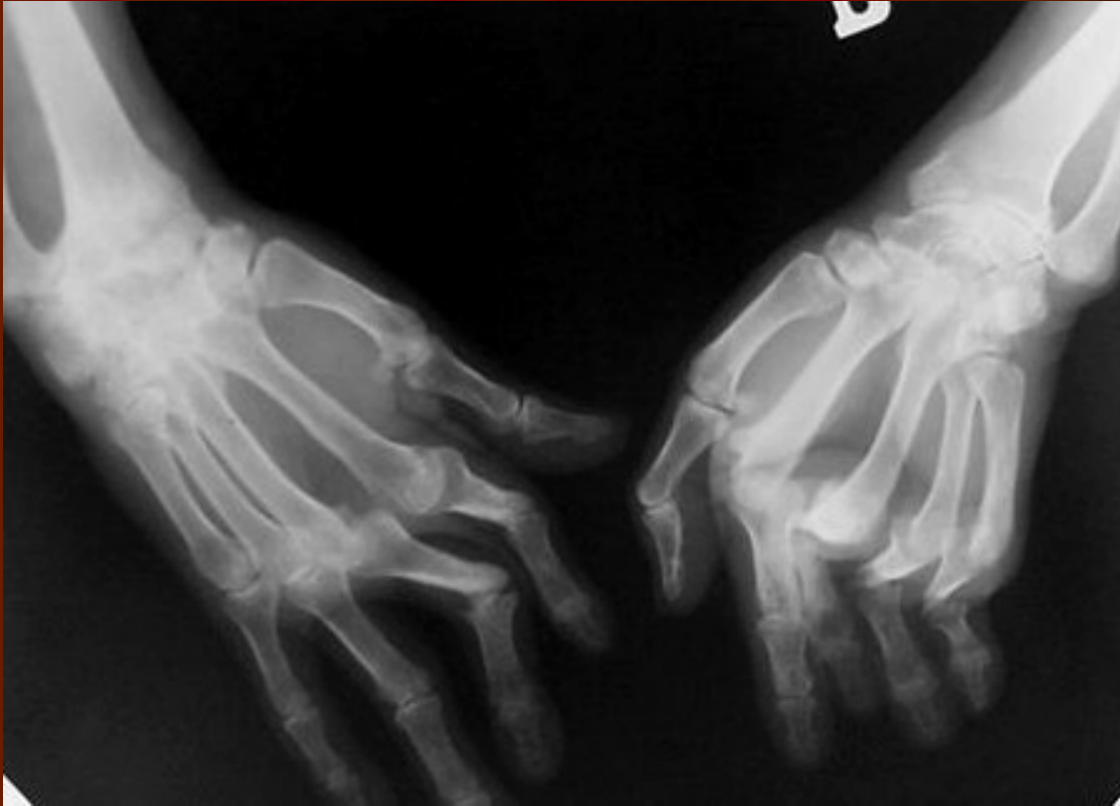Metastaze blastice



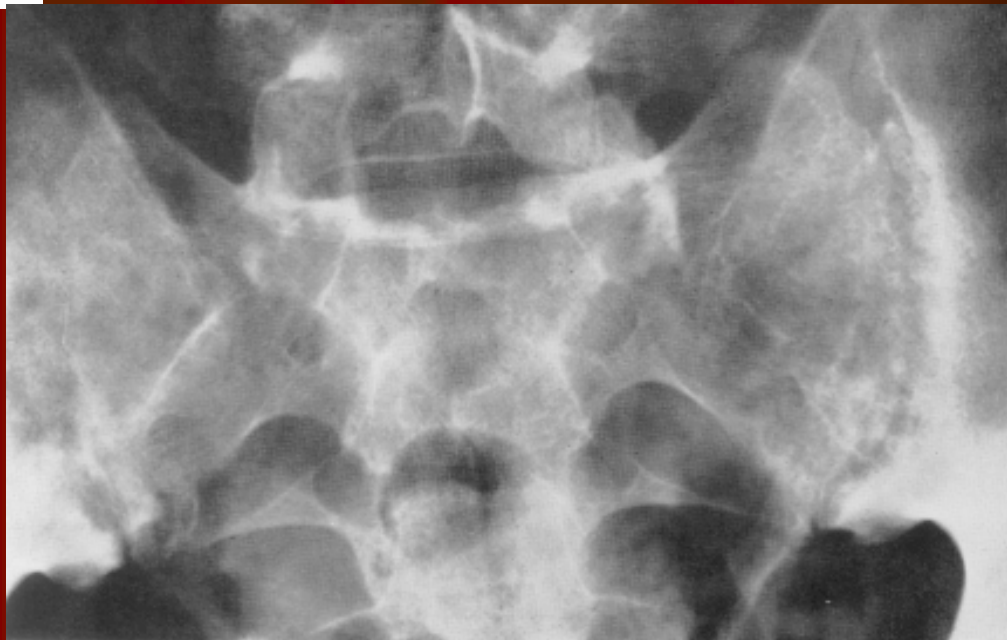Metastaze blastice



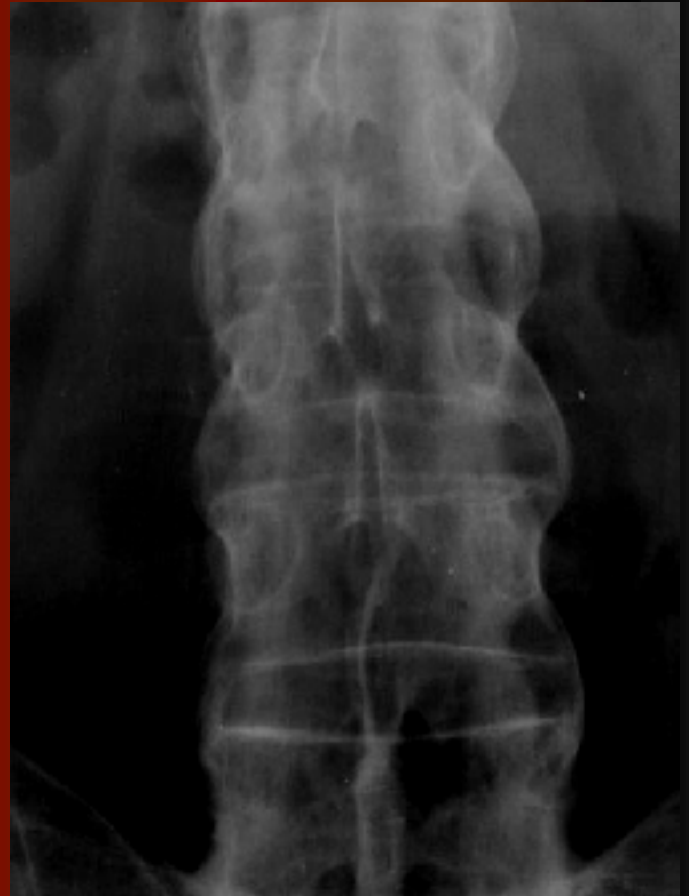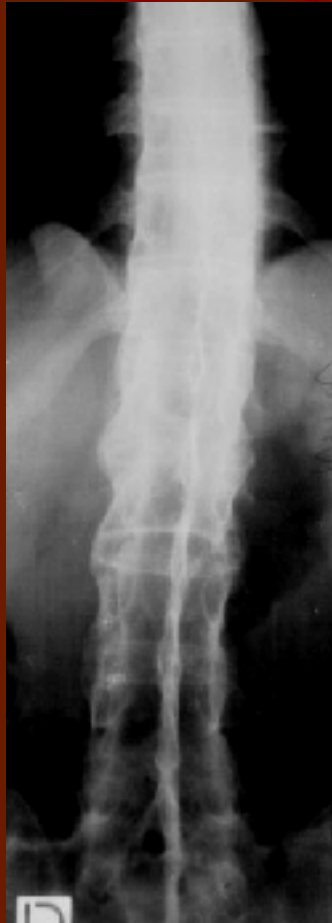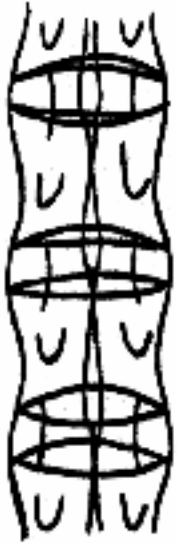
Modificările în poliartrita reumatoidă



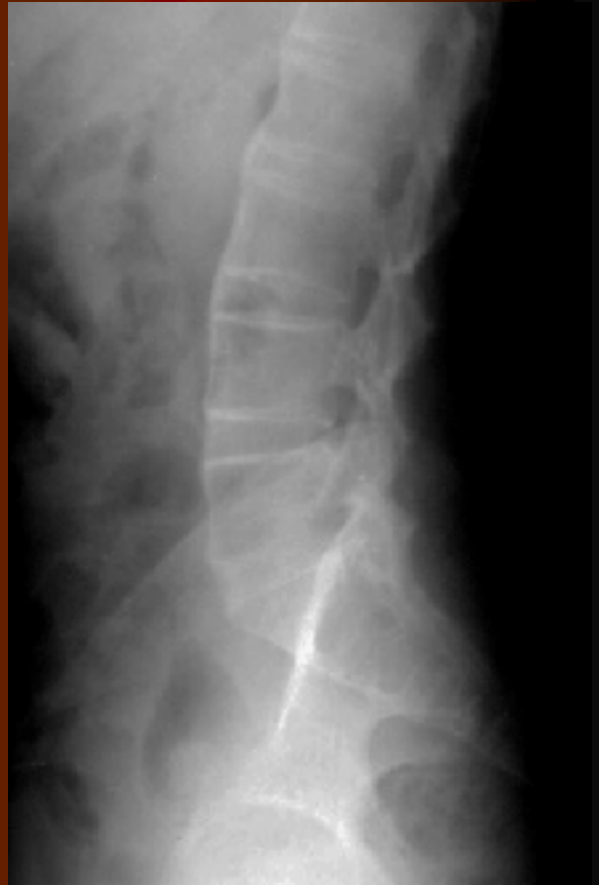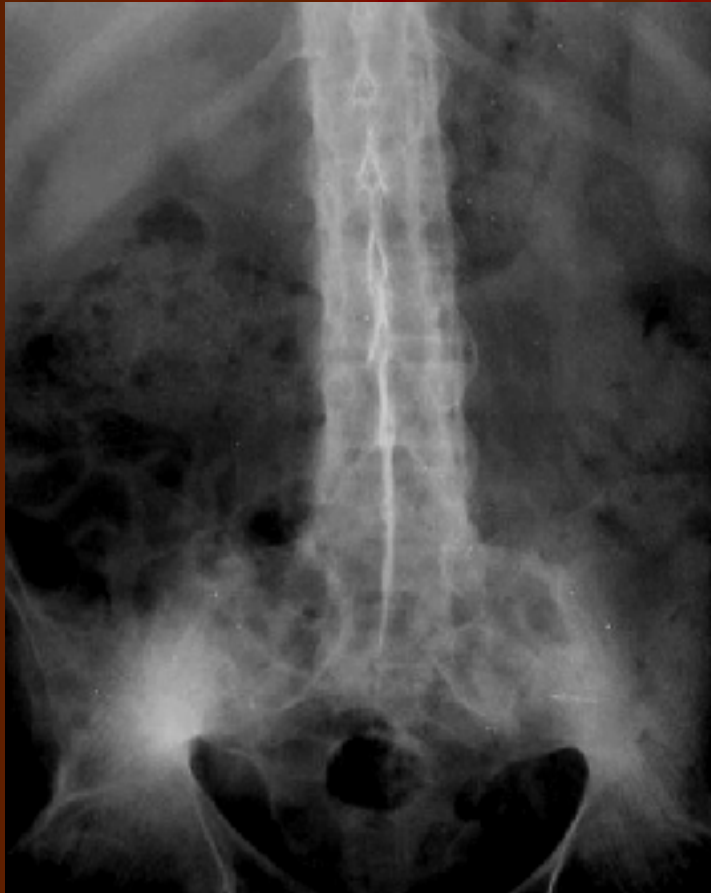Modificările în poliartrita reumatoidă



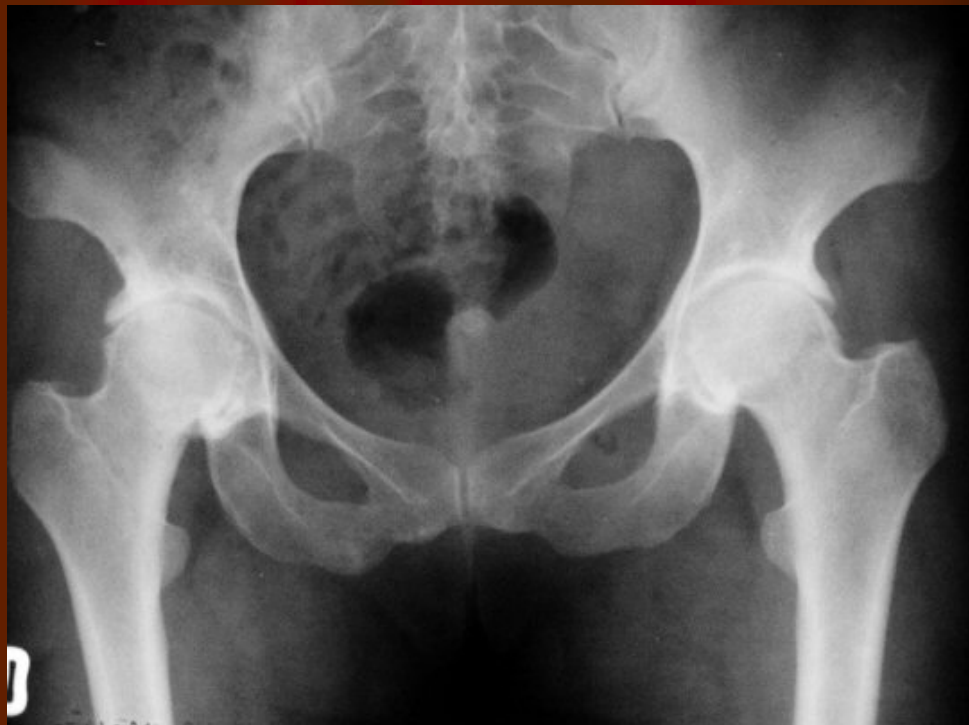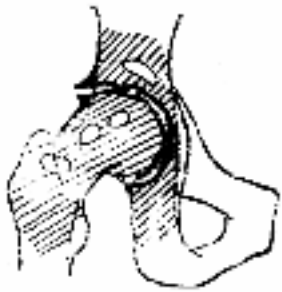
Spondilita anchilopoetică



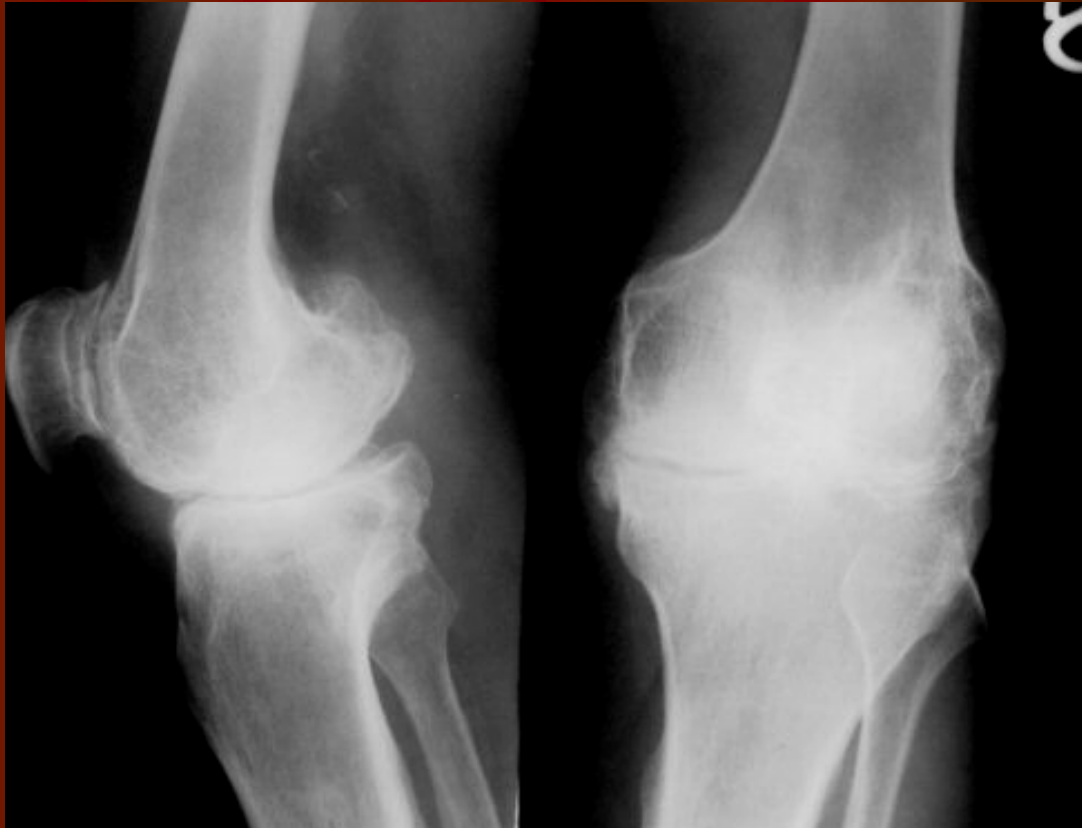
Coloana de bambus



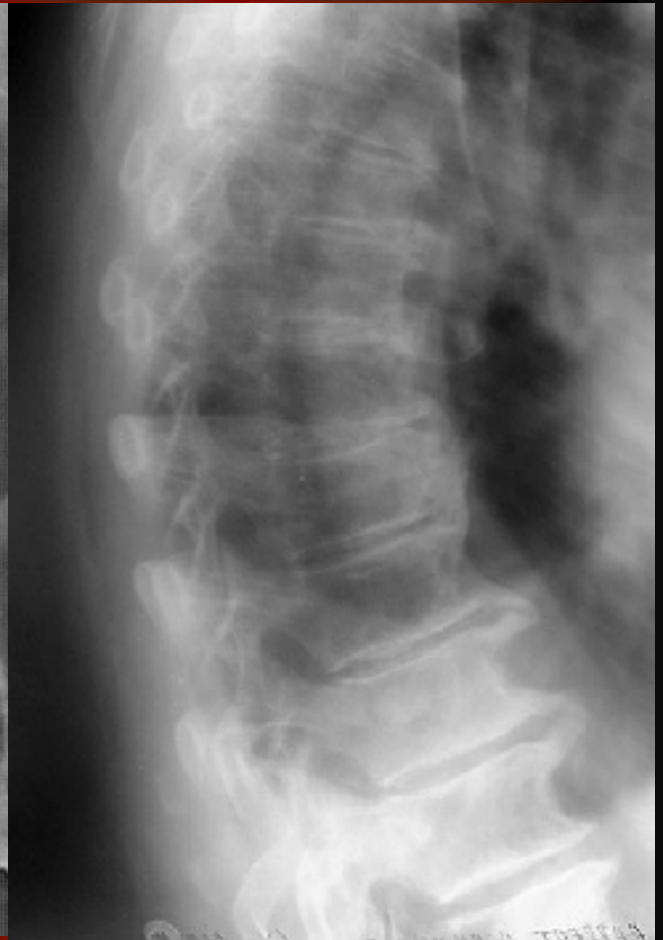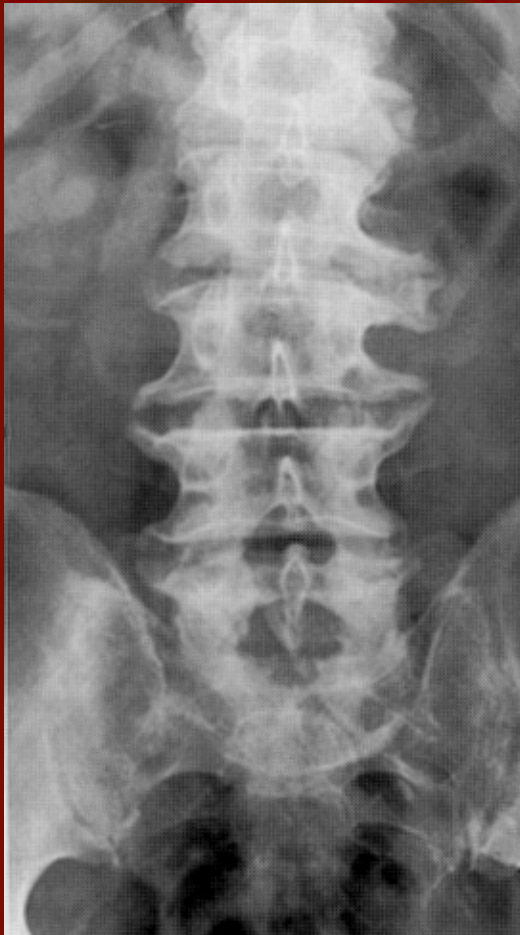Spondilită



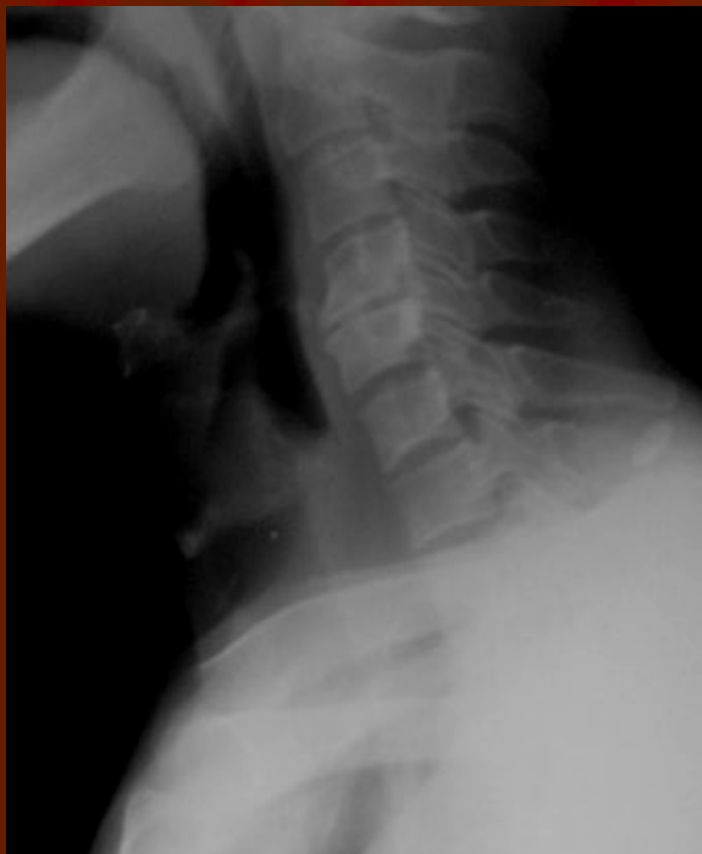Coxartroza



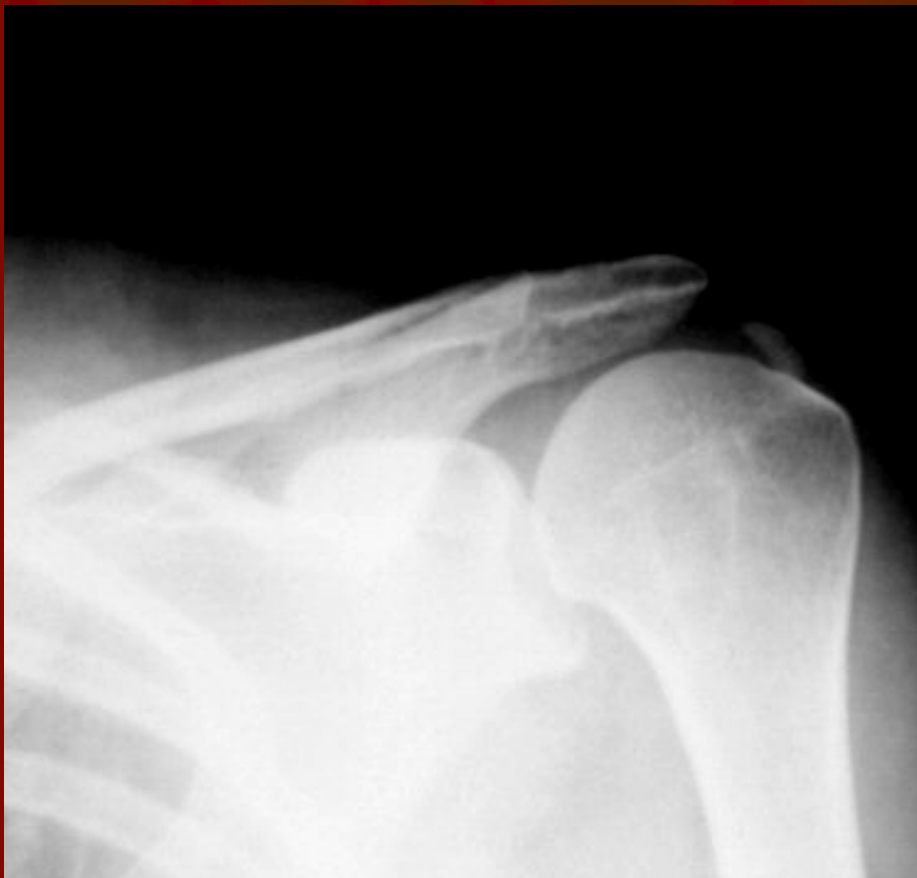Gonartroza



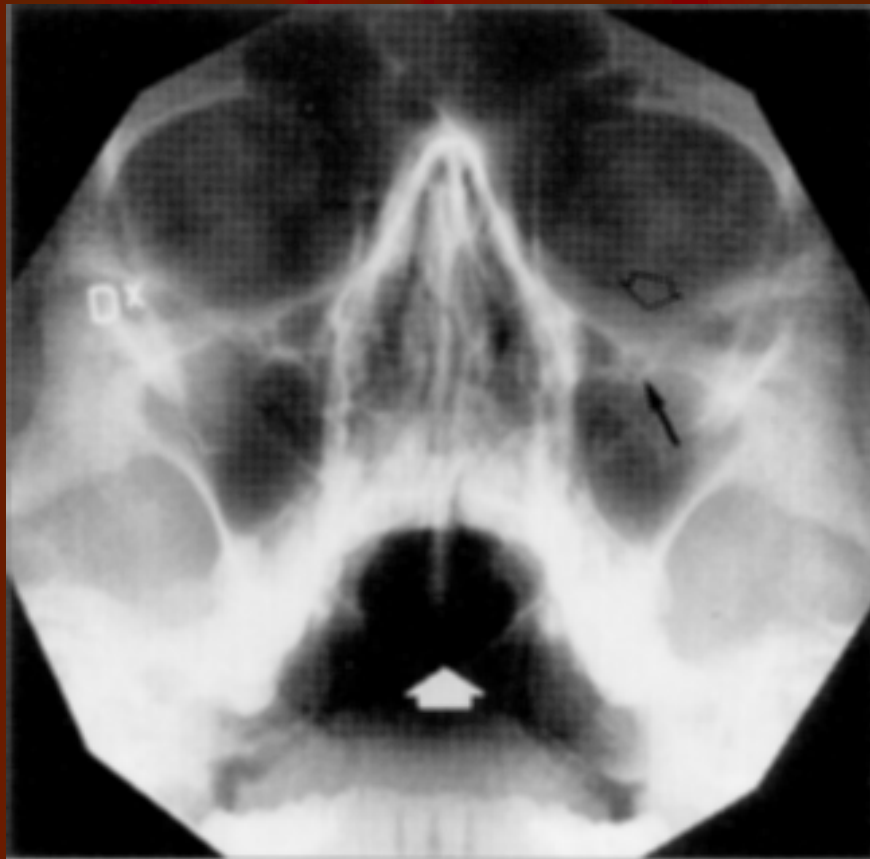Spondiloza



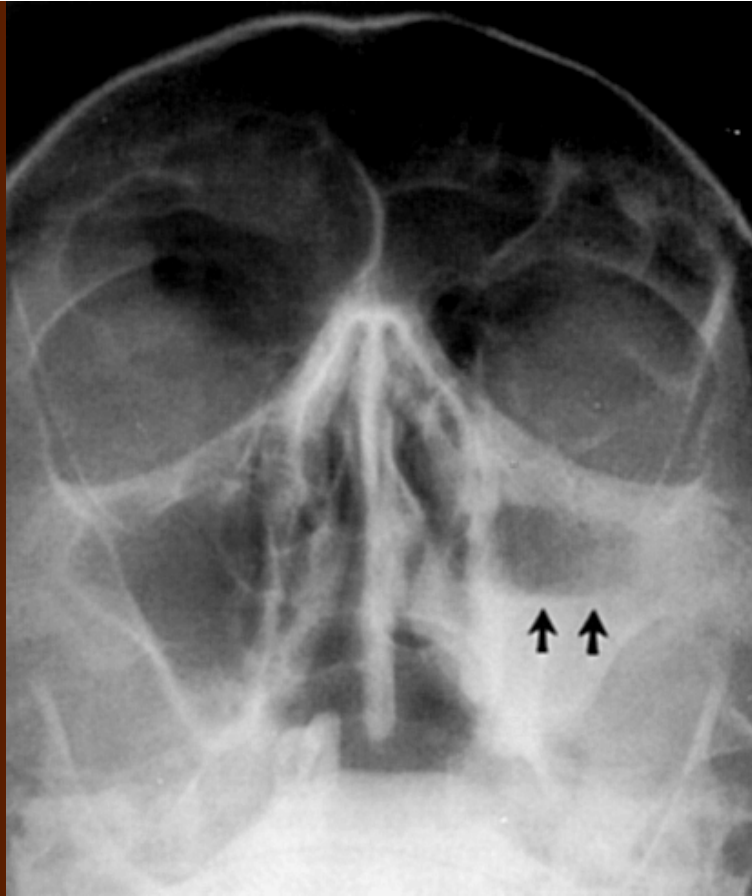Cervicartroză



Periartrita scapulo-humerală

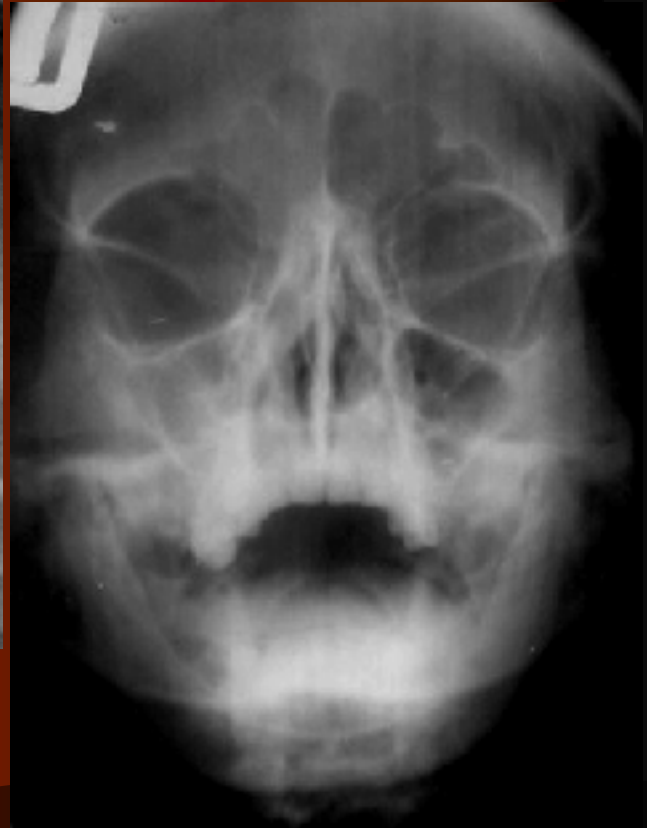


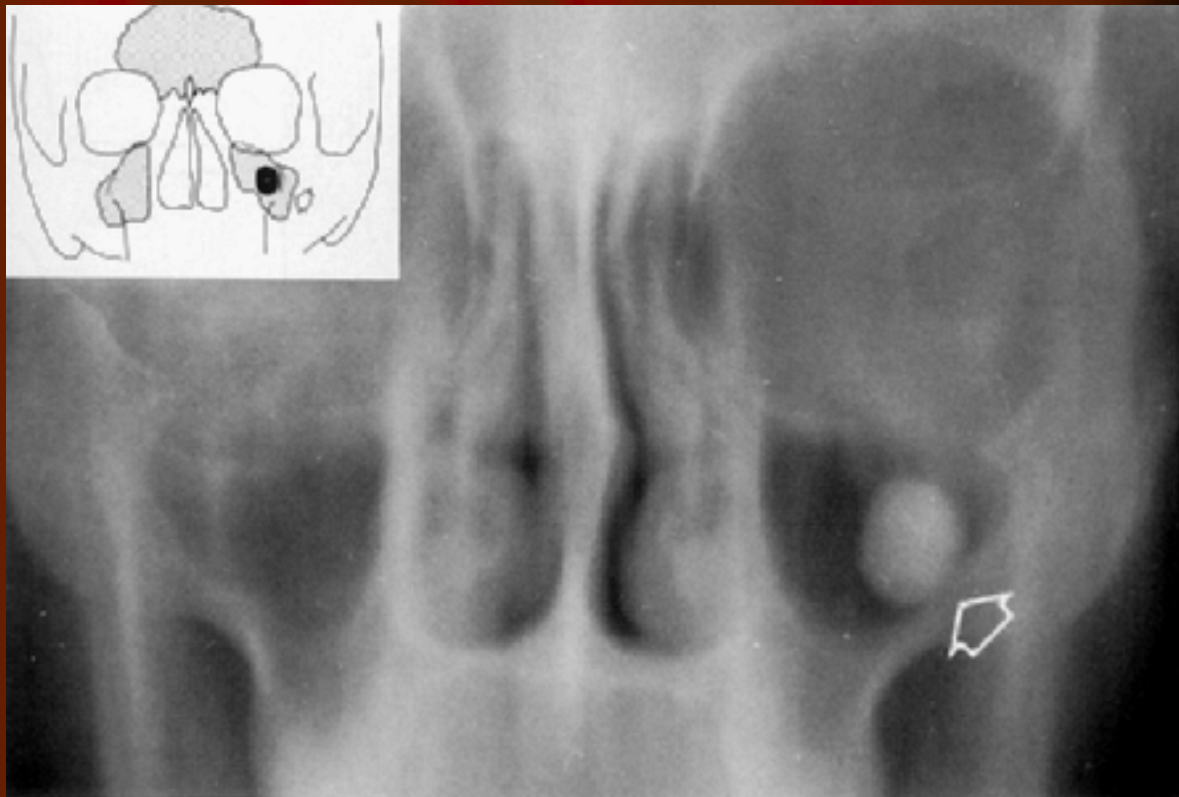
Aspectul normal al sinusurilor frontale



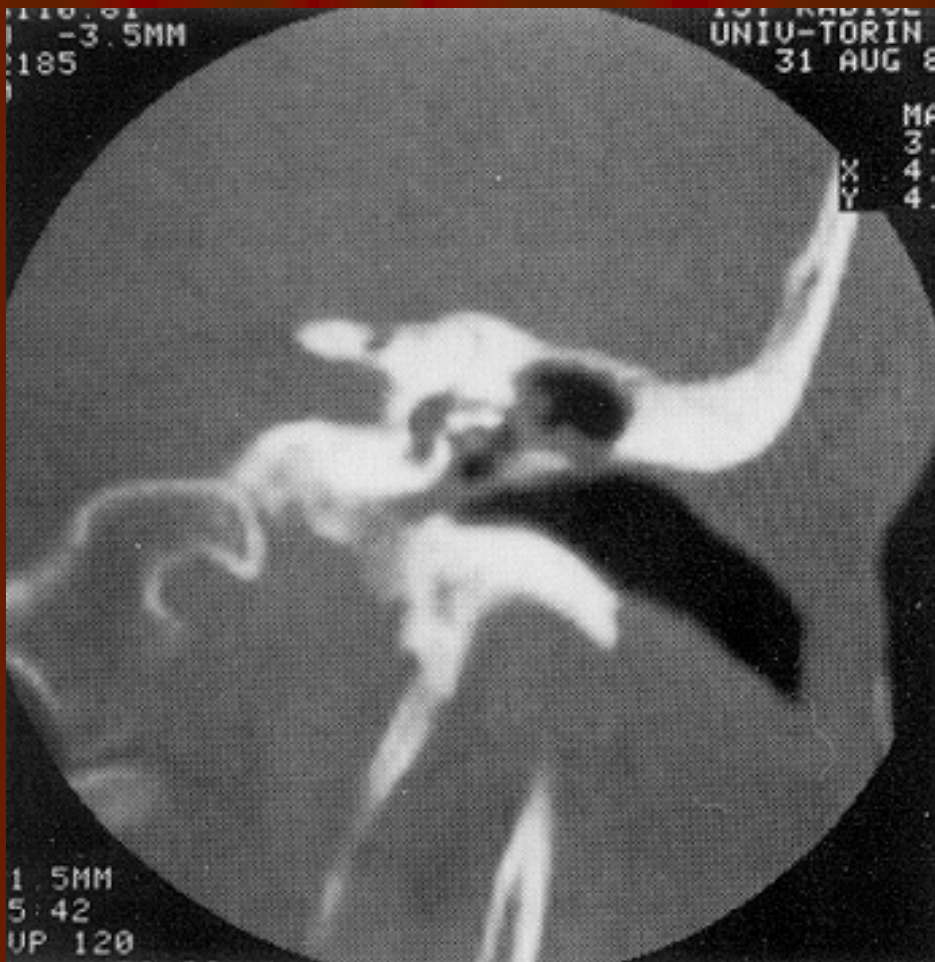Sinuzită maxilară

Sinuzită fronto - maxilară

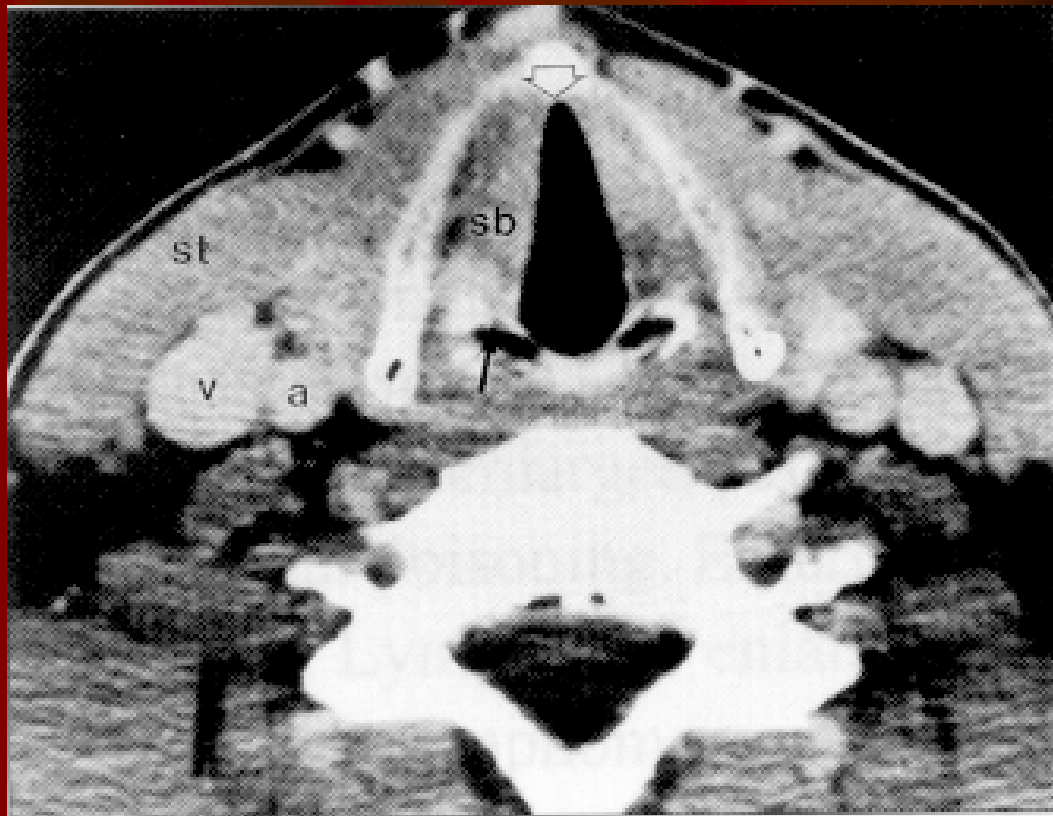




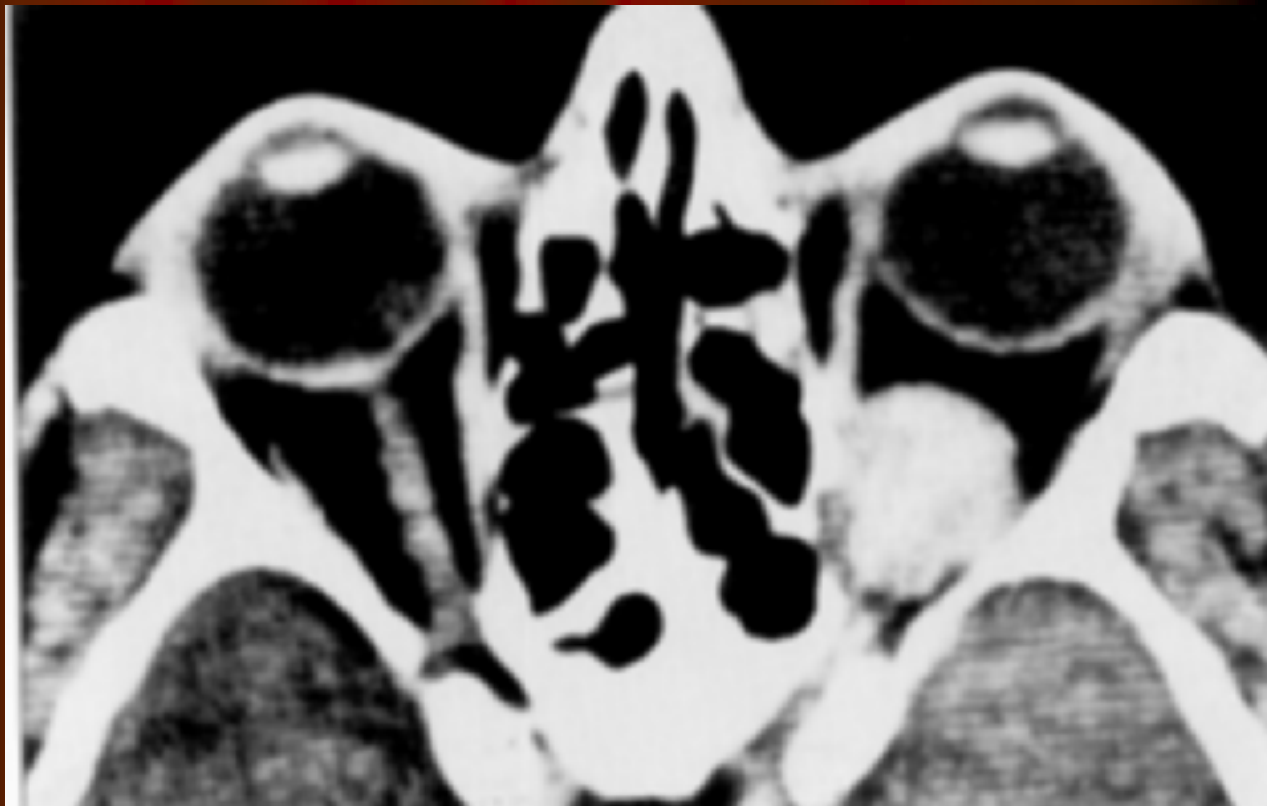
Tomografie plană - Osteom maxilar stâng



CT - Colesteatomul

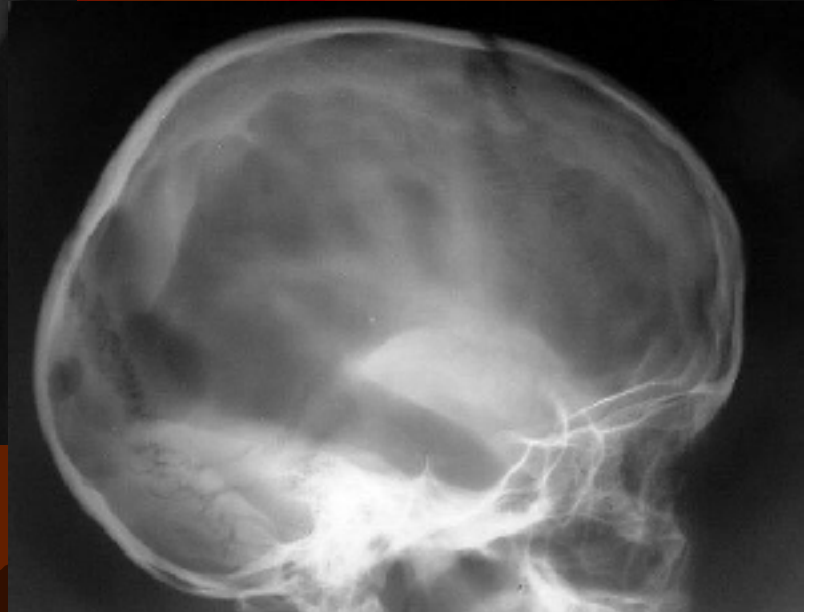
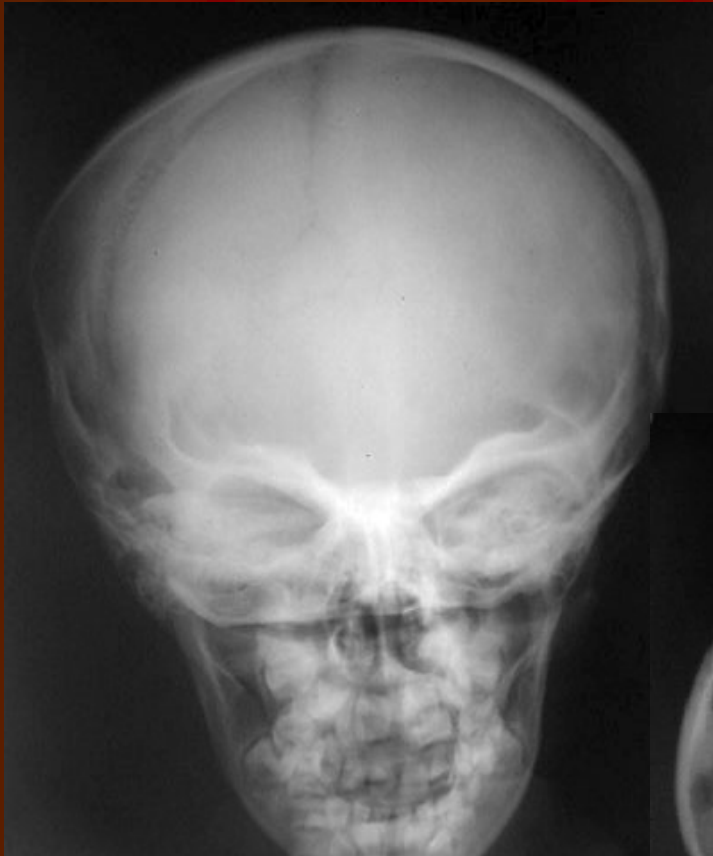
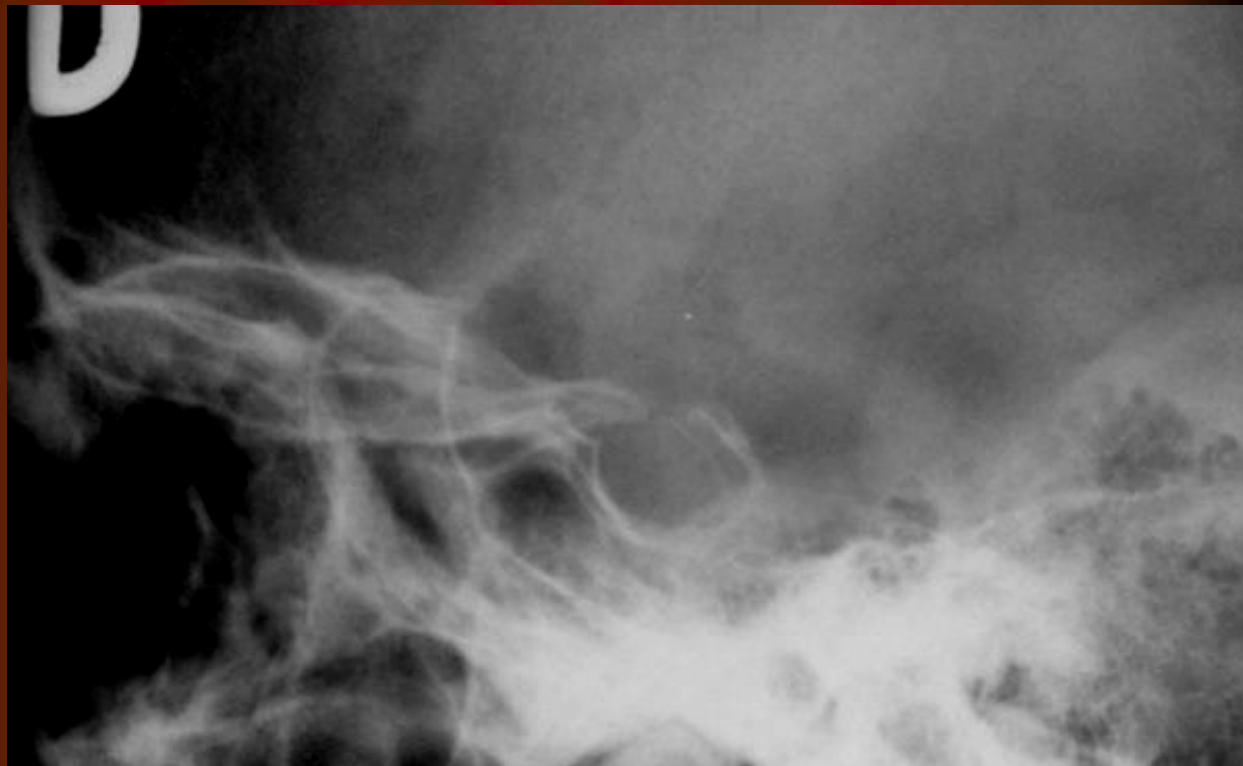Laringele examinare CT



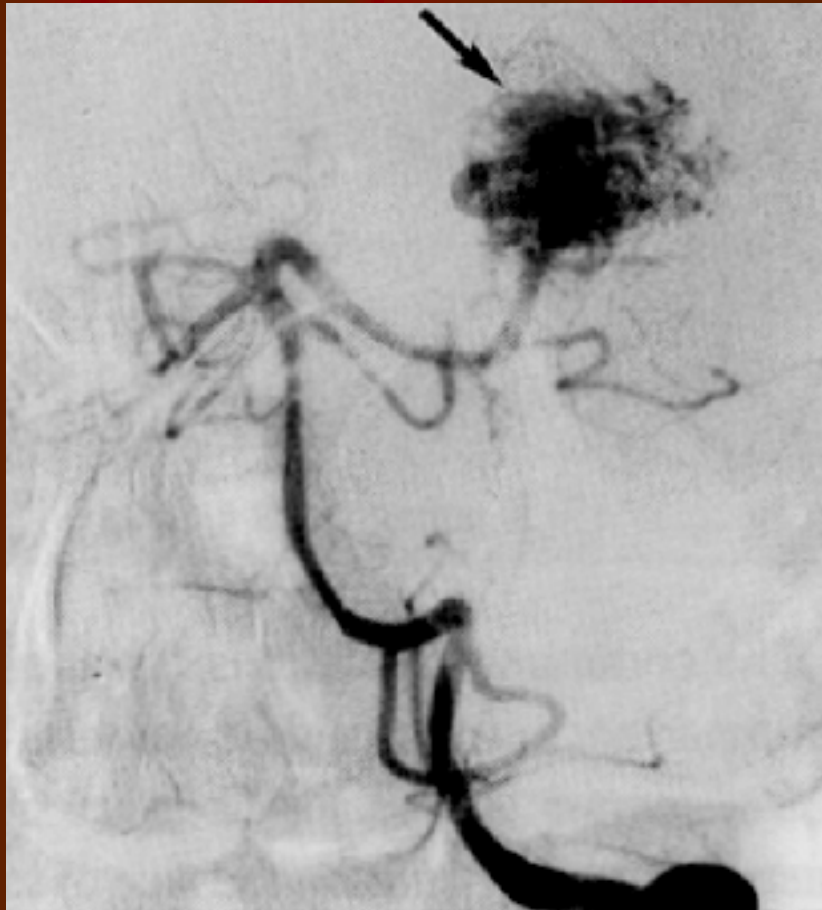CT - Tumoră orbitală stângă

Hidrocefalie – Rgr. Craniu + PEG

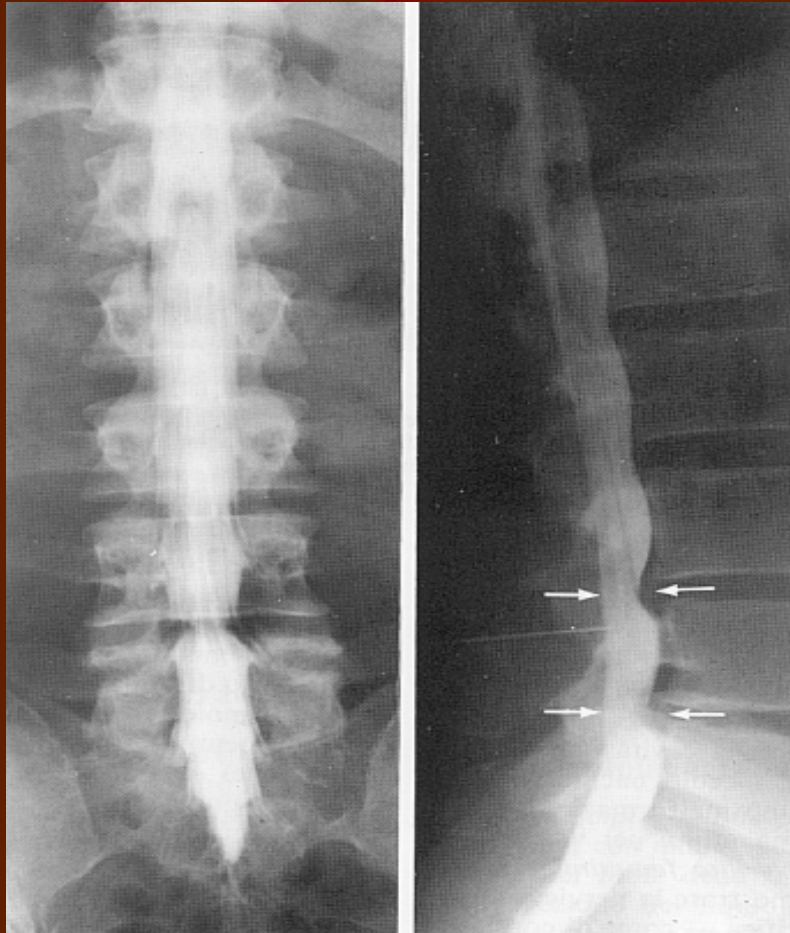




Șa balonizată – tumoră de hipofiză

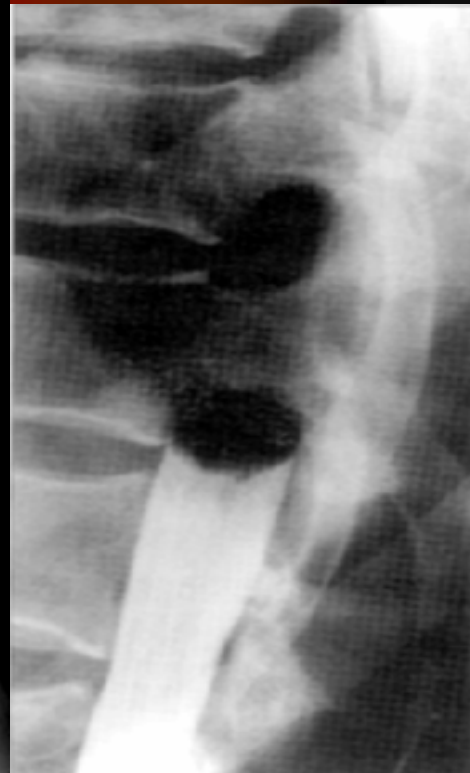
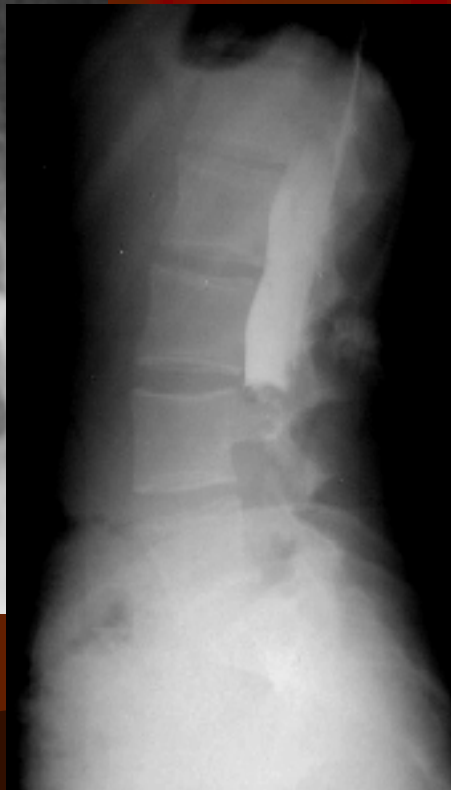
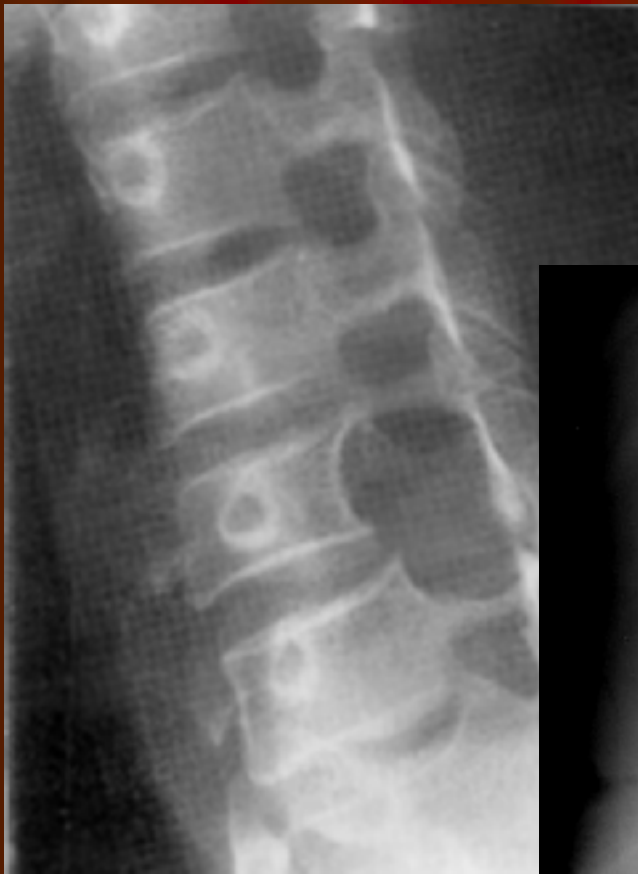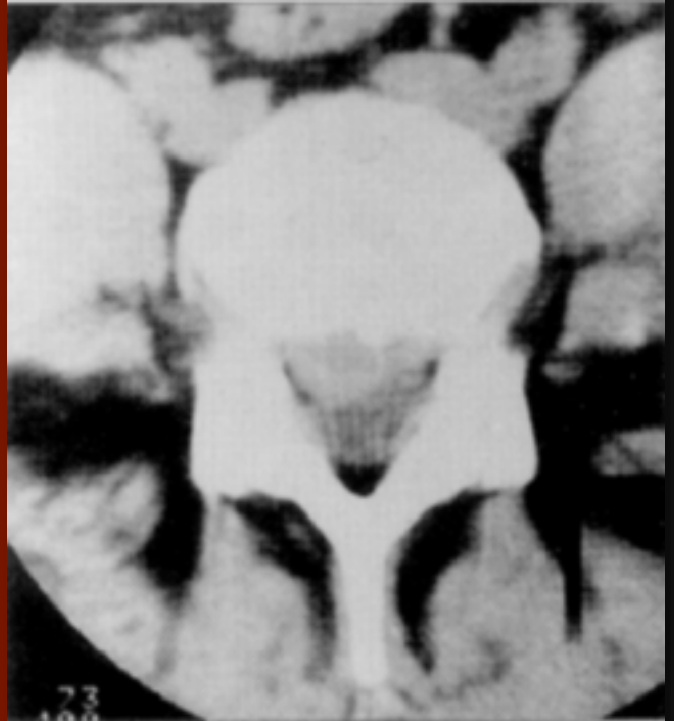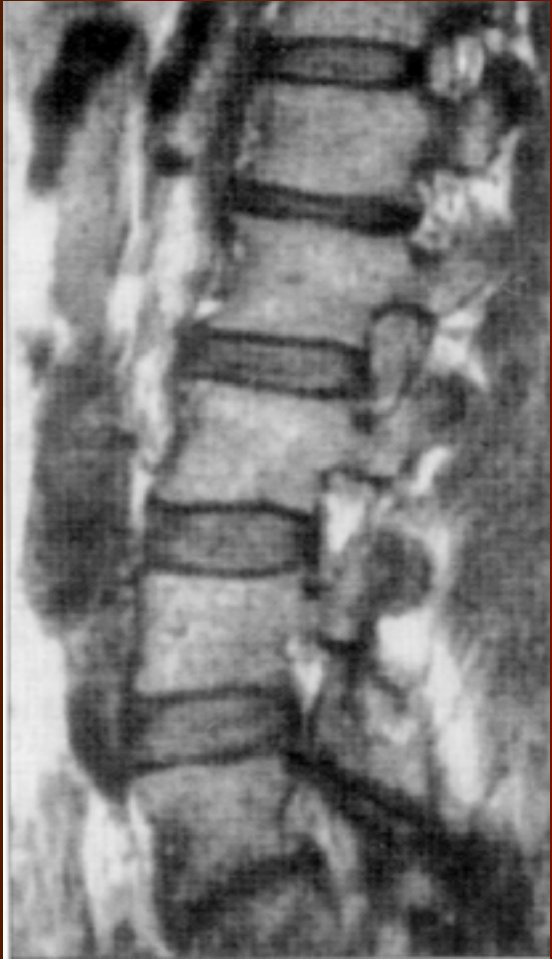Angiografie cerebrală-malformație arterio-venoasă



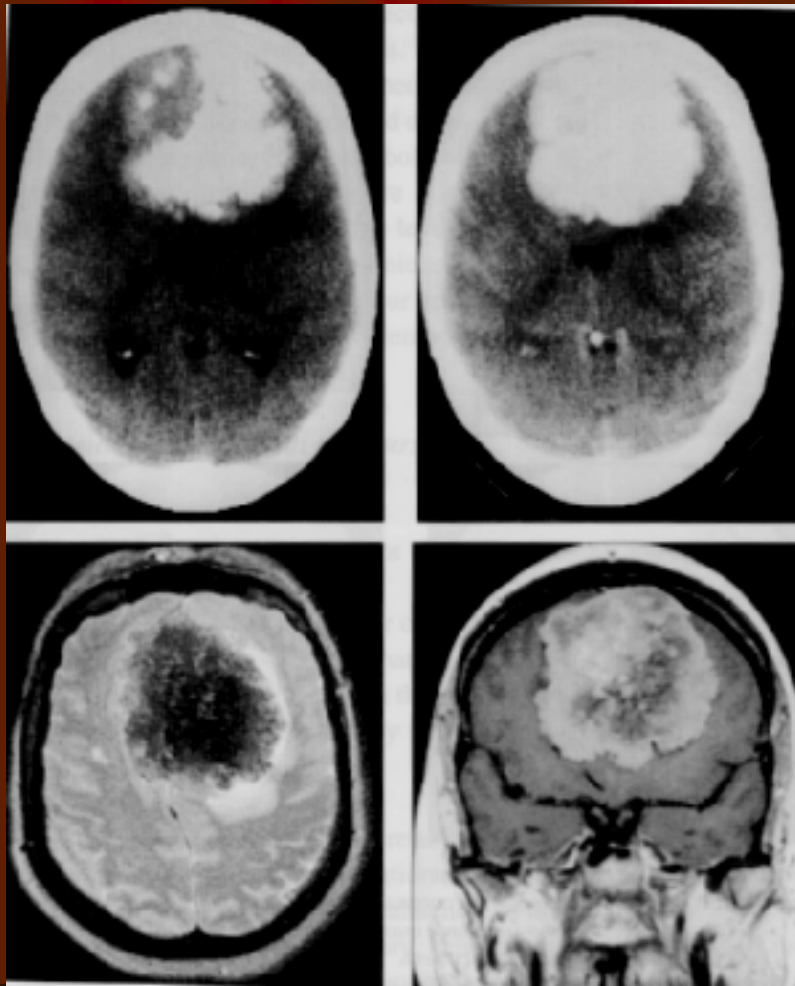
Hernie de disc -mielografie

Tumoră medulară

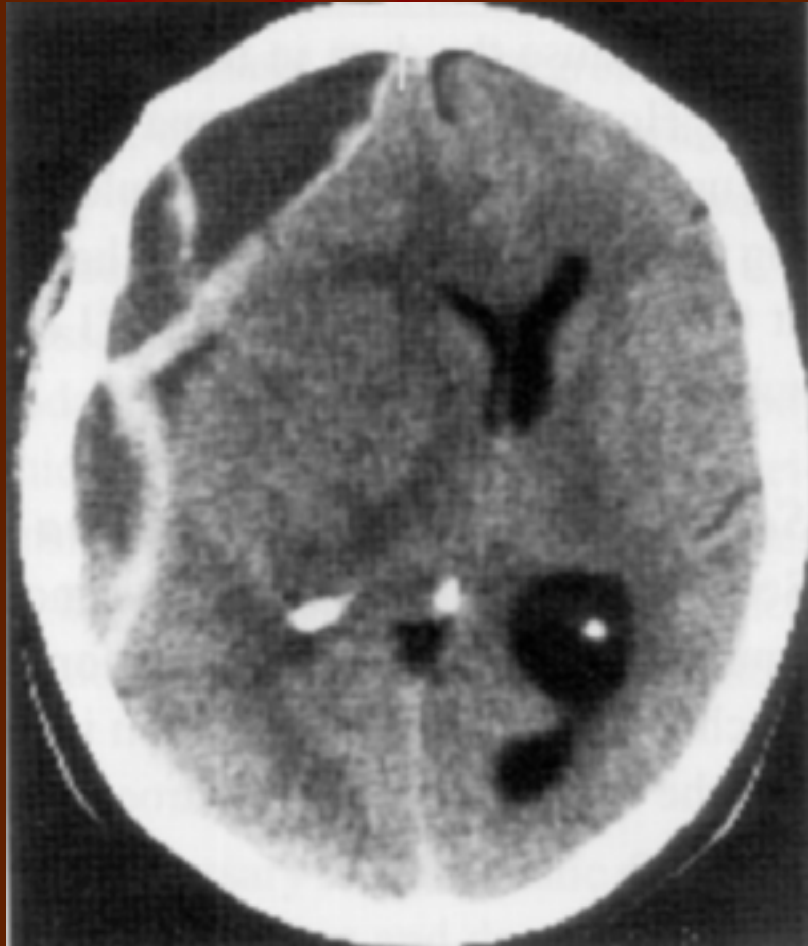



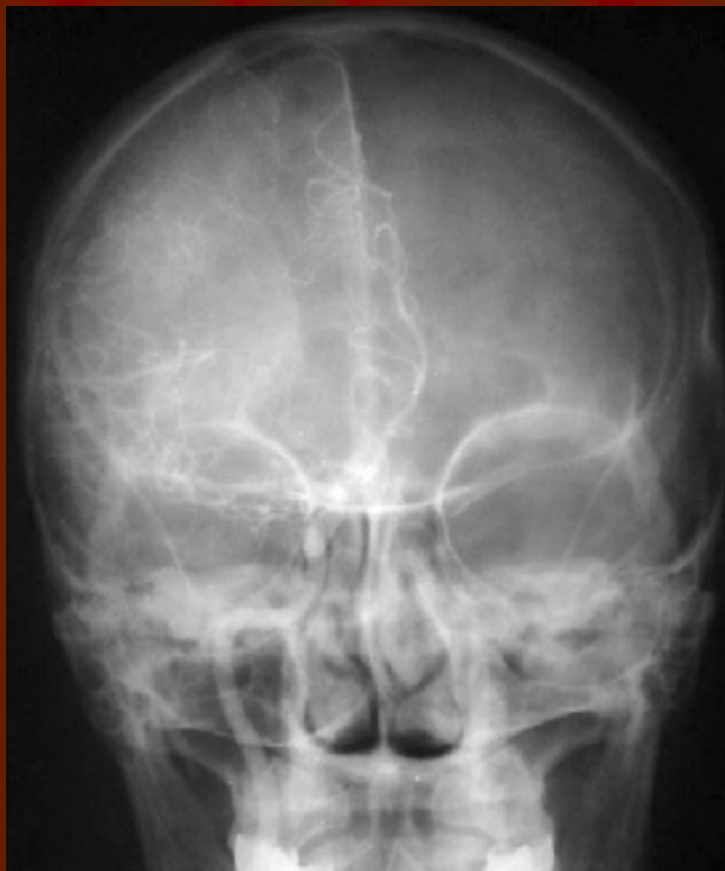Hernie de disc-IRM respectiv CT



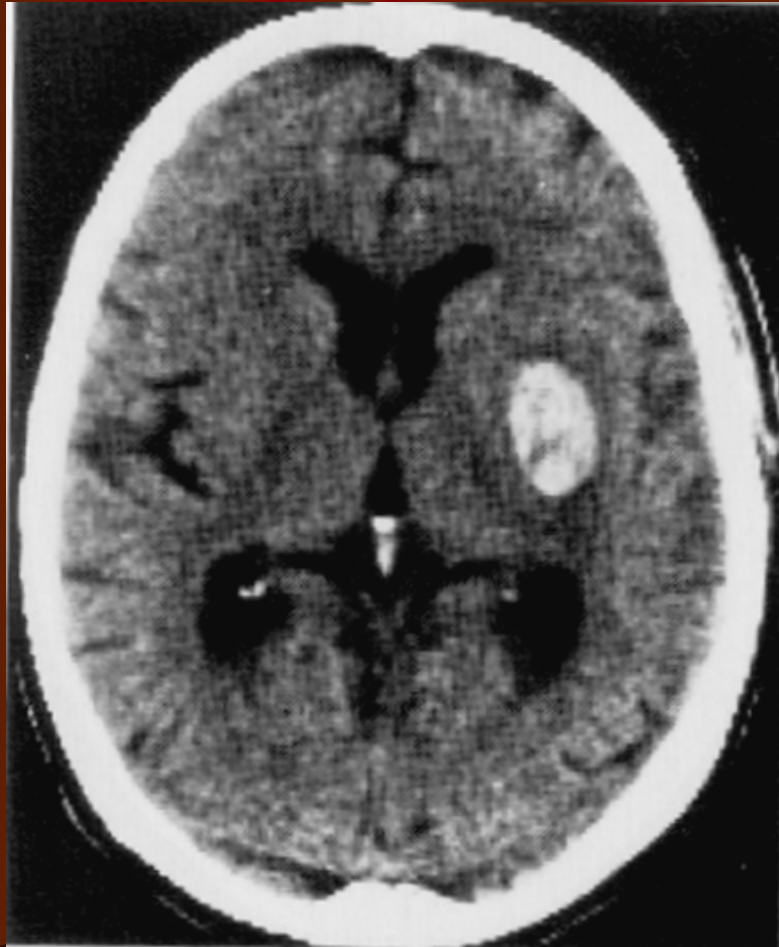Tumori cerebrale



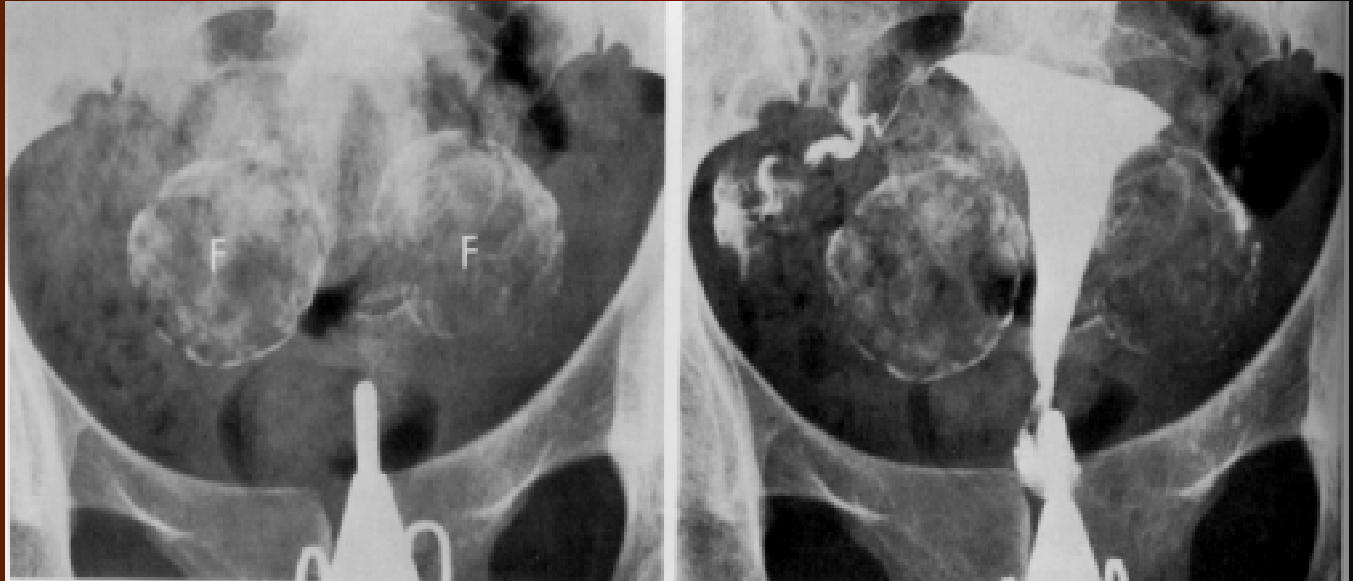CT - Hematom epidural



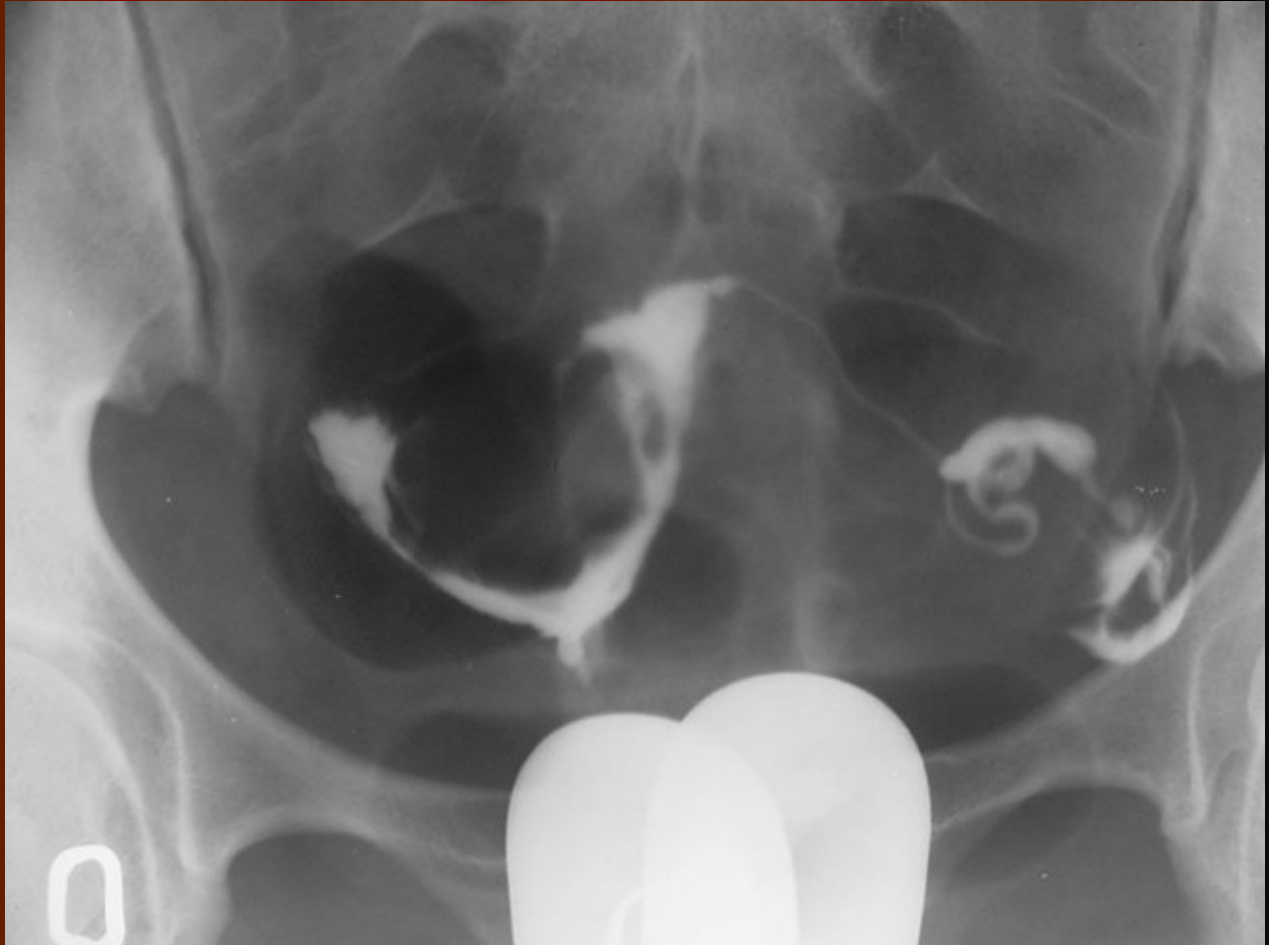
Ateriografie carotidiană dr – hematom subdural



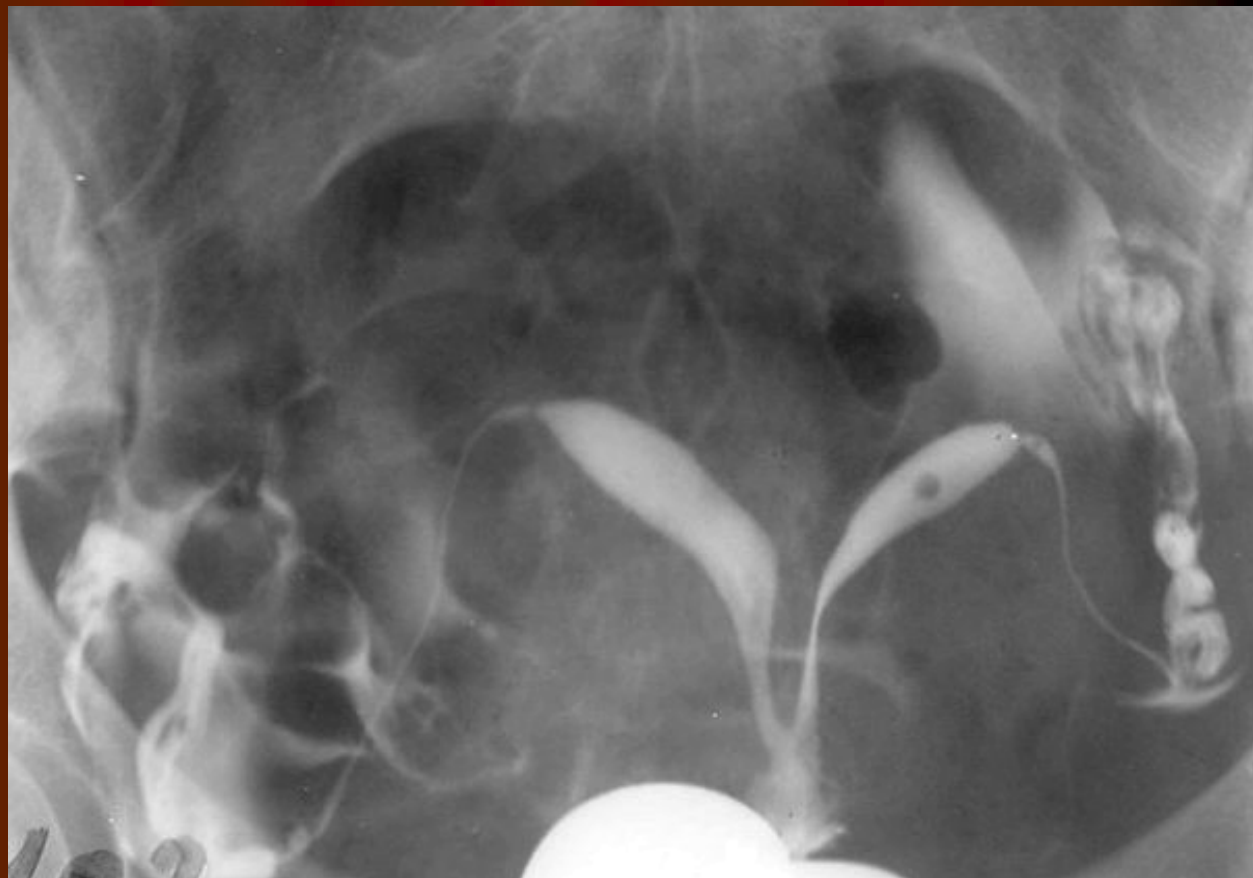CT - Hematom intracerebral



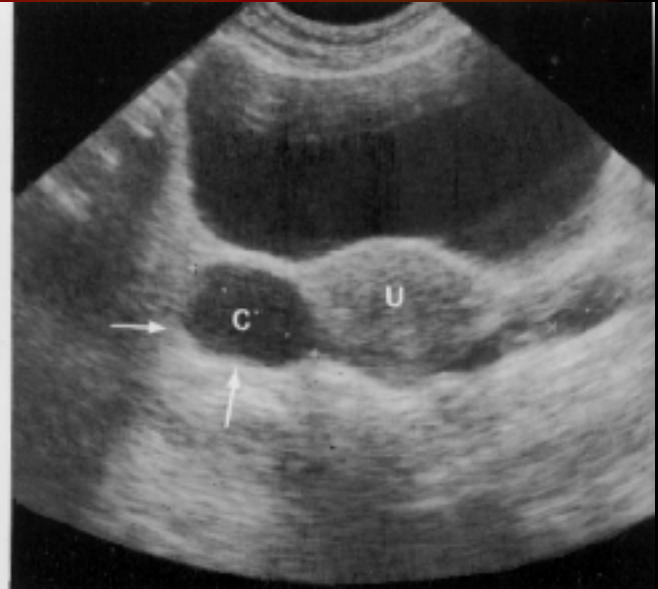
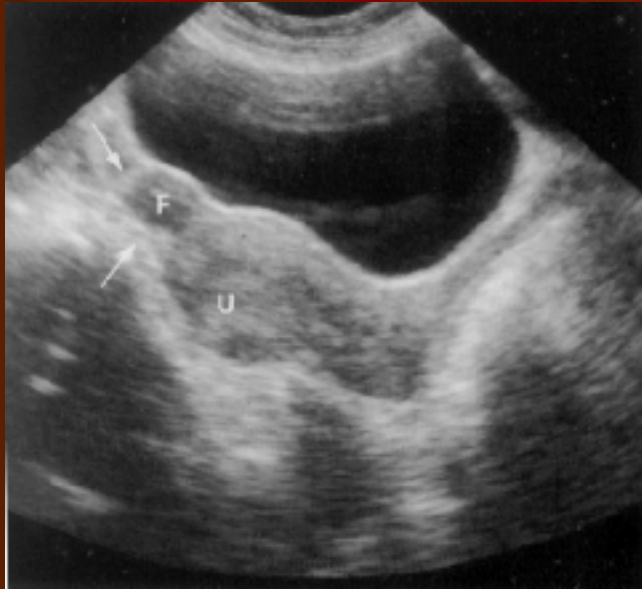
Leifibromioame uterine calcificate
Radiografie simplă + HSG



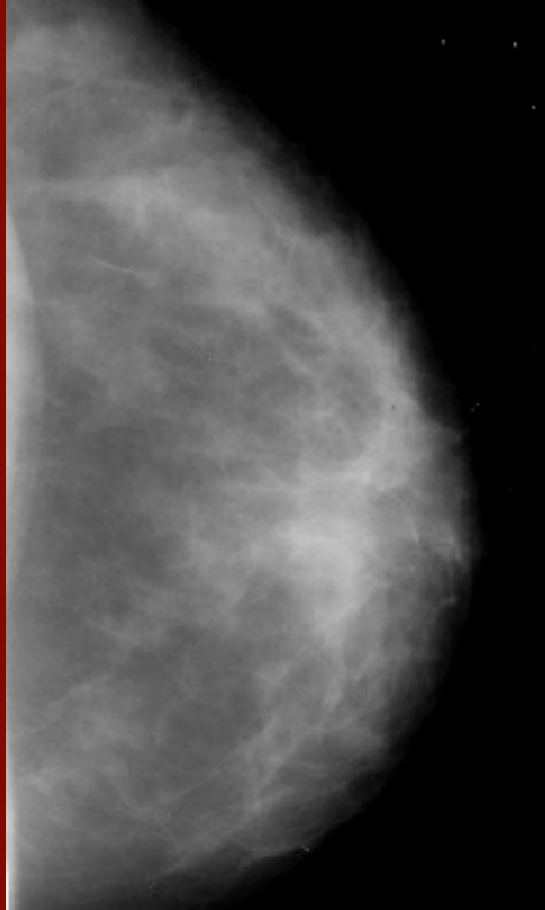
HSG – Fimrom endoluminal



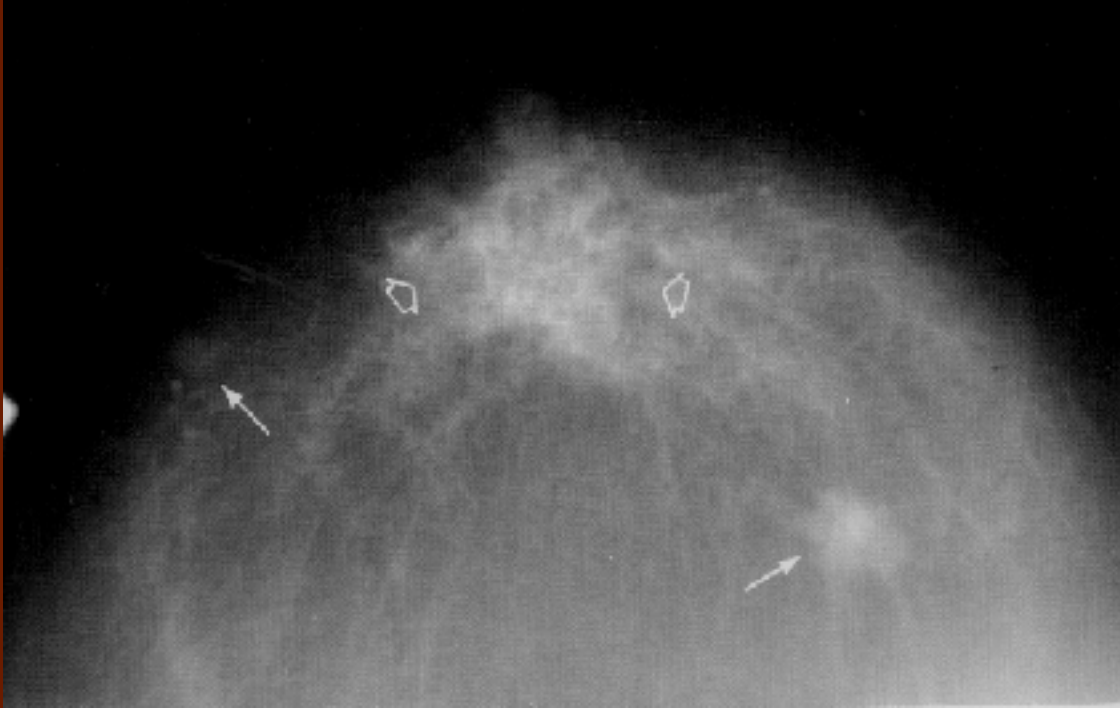HSG – Uter bicorn



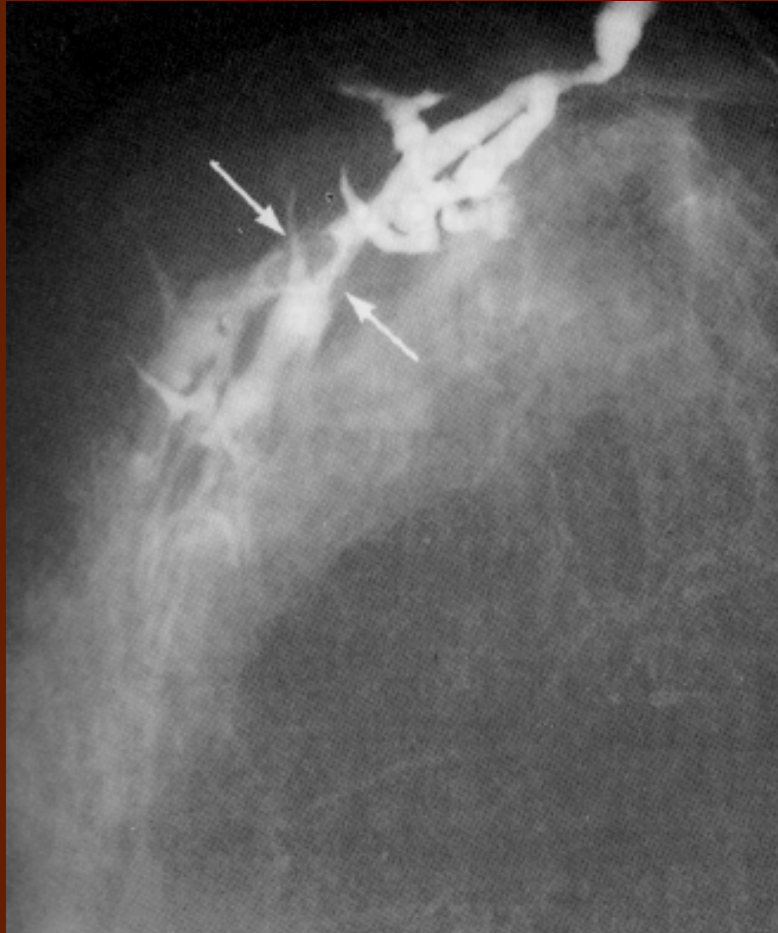
Ecografie - Chiste ovariene



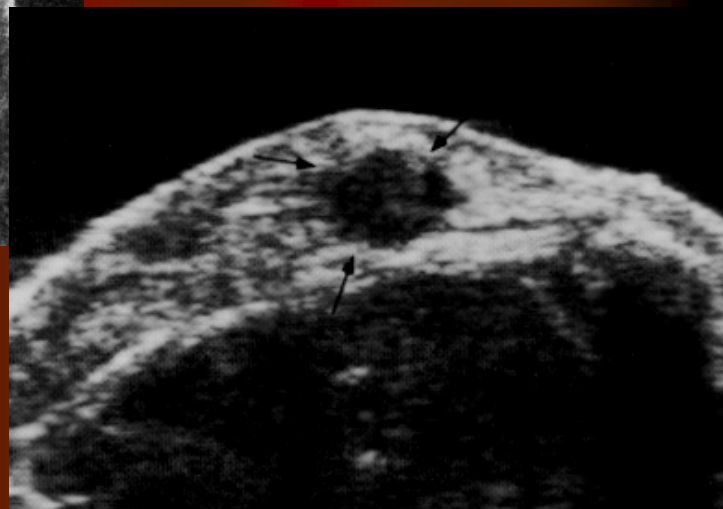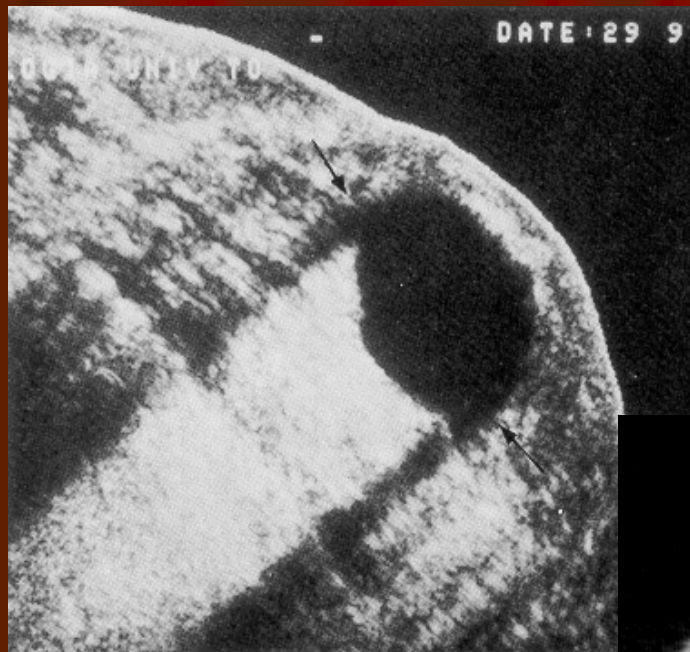Mamografie normală



Mamografie - cancer mamar



Galactografie – Papilom intraductal



Ecografia mamară

