

UMF TIMIȘOARA

*LUCRARI PRACTICE  
STUDENTI*

CONF. DR. MAGDA PĂSCUȚ  
2005

# *COLABORATORI*

PROF. DR. MARIA MOGOȘEANU

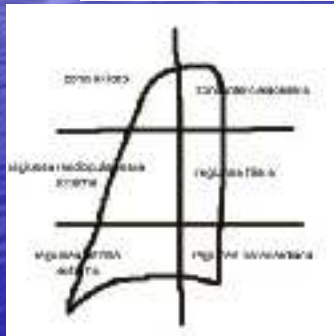
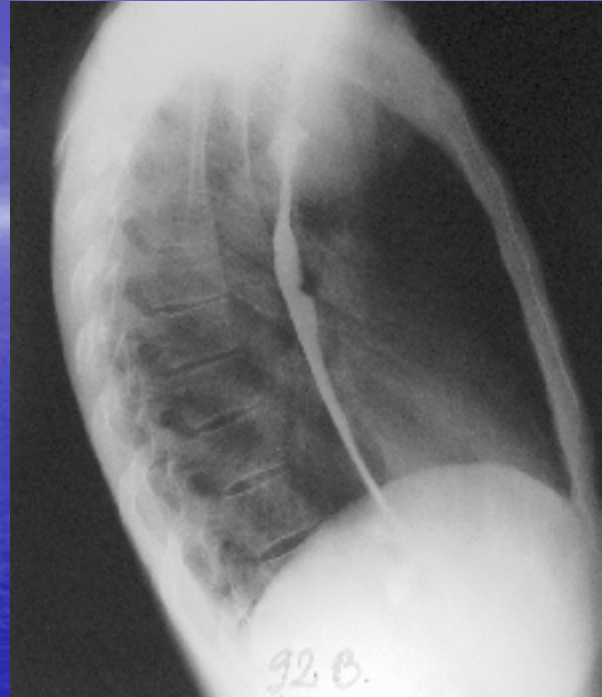
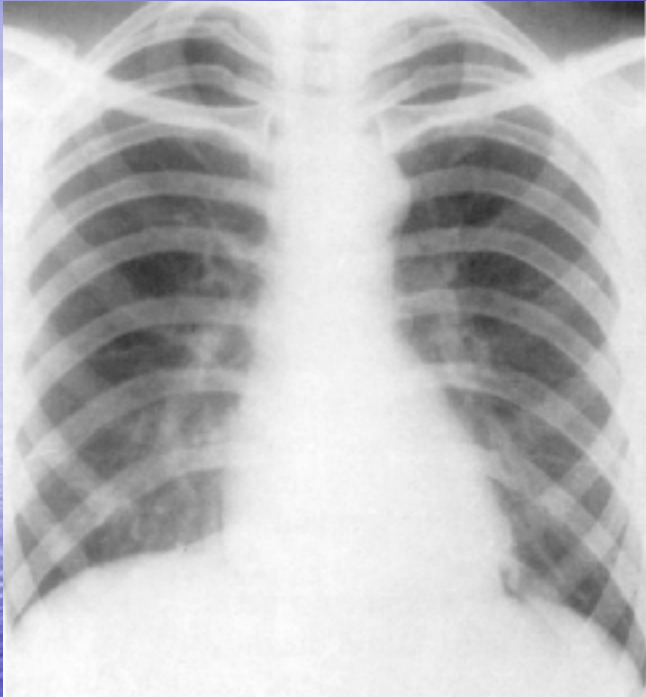
Ș.L. VESA ANA MARIA

DR. SOCOLIUC CRISTIAN

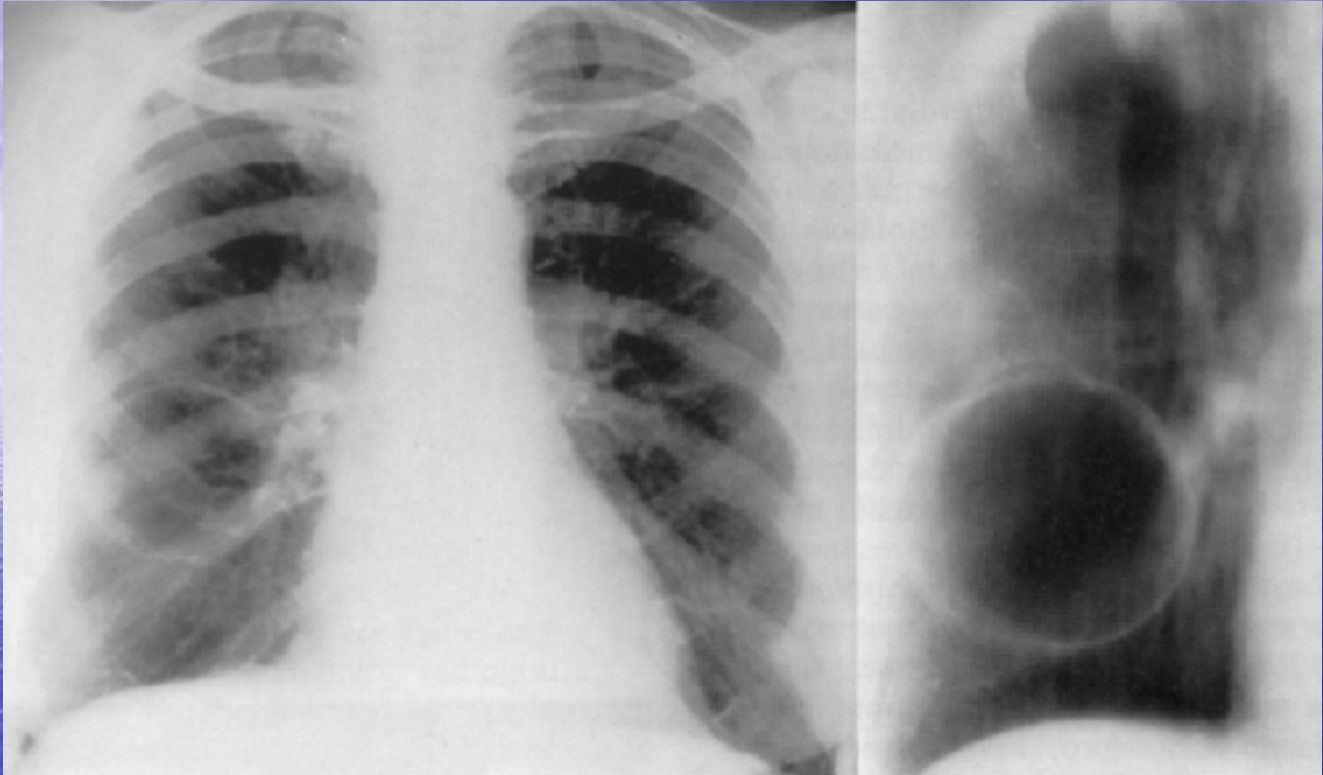
DR. MOTOI SORIN

DR. MAXIM ANA MARIA

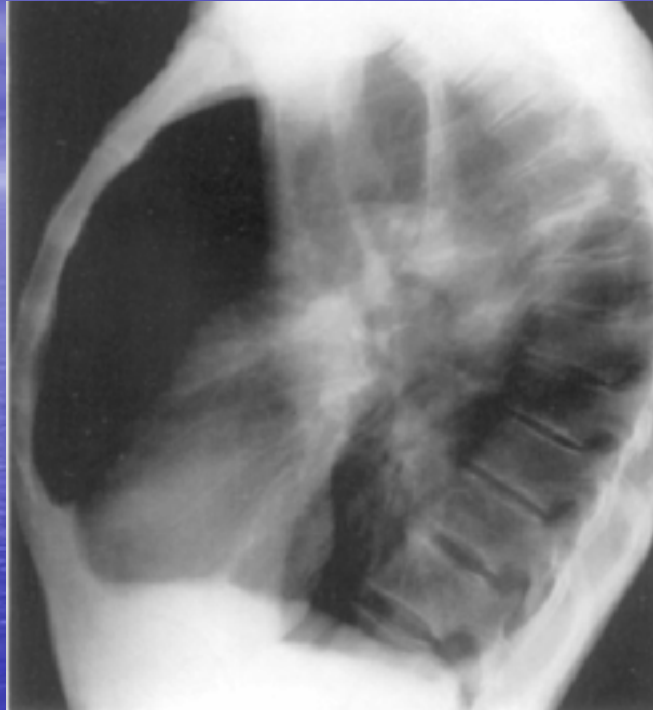
2005



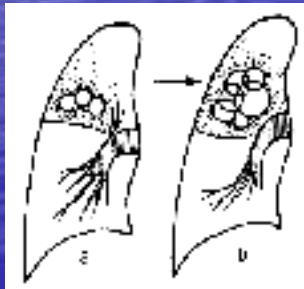
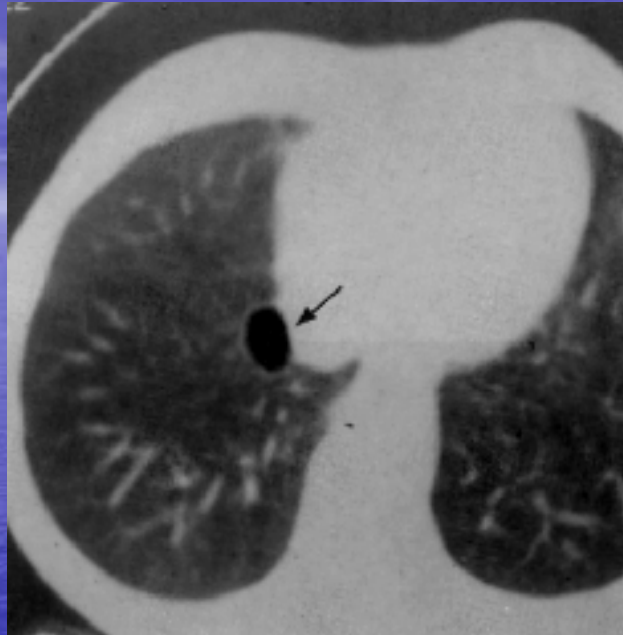Imagine toracica normala-față si profil drept



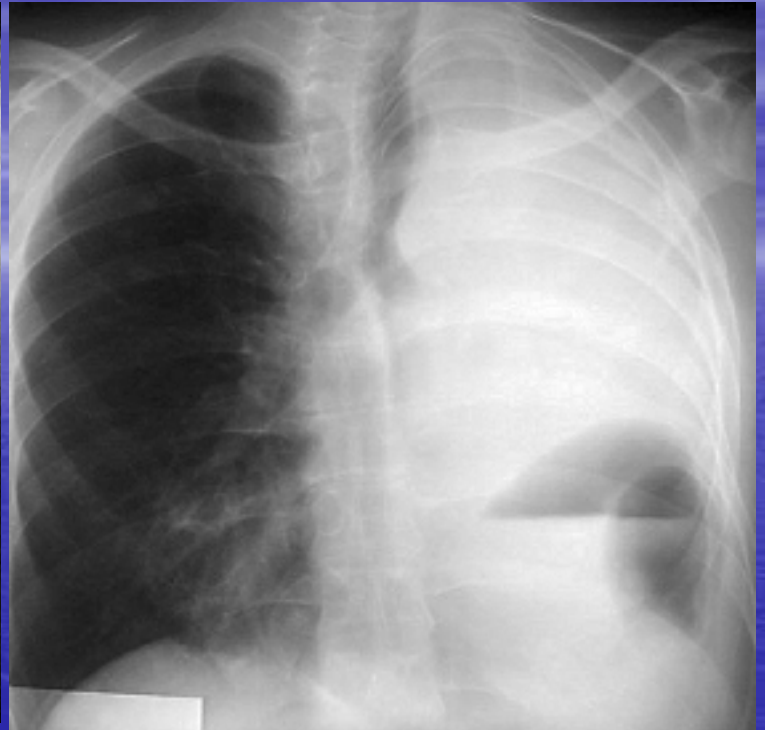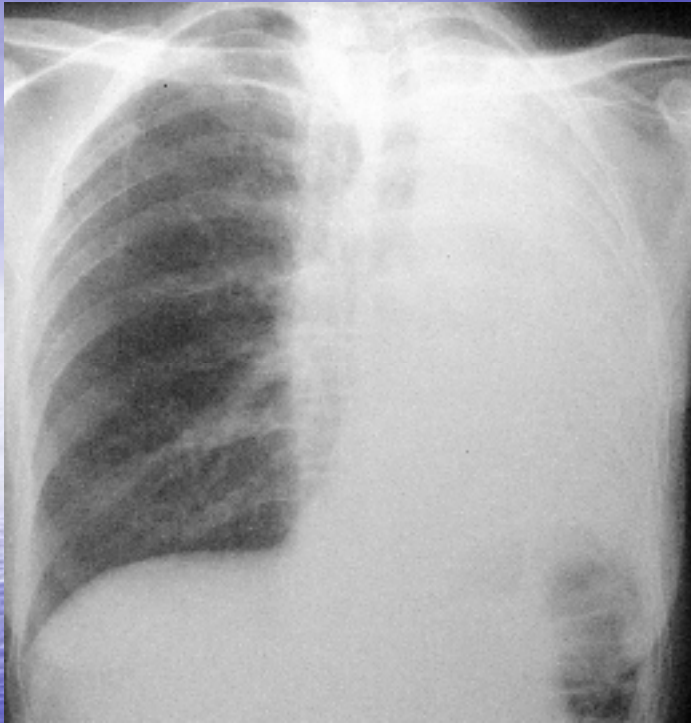
Chist aeric gigant, dreapta tomografie liniară



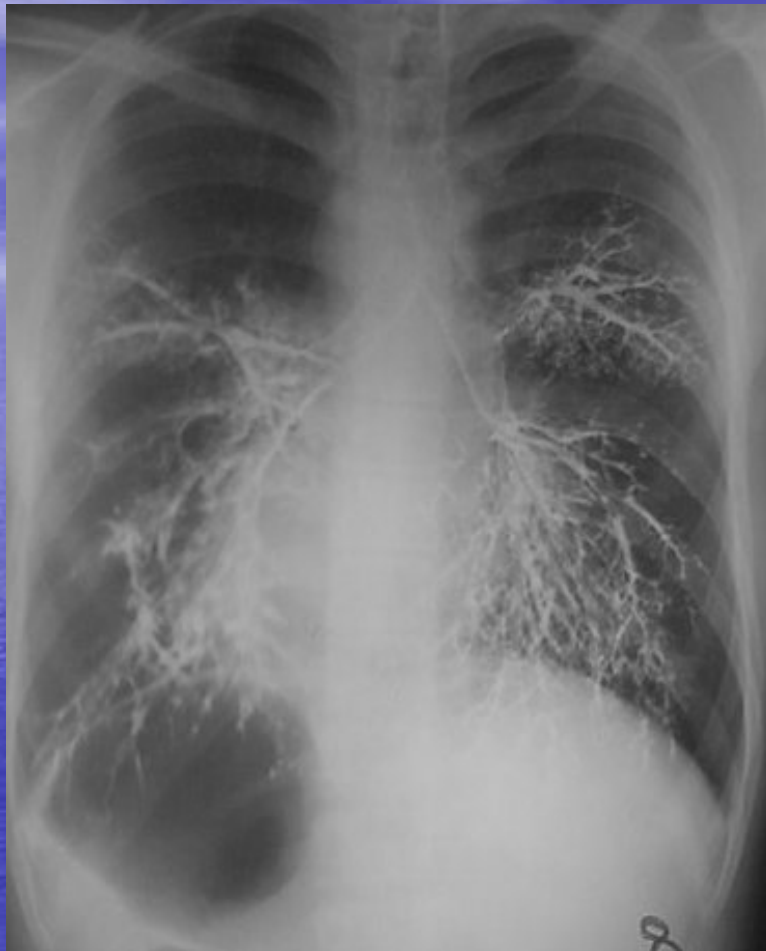Emfizemul pulmonar




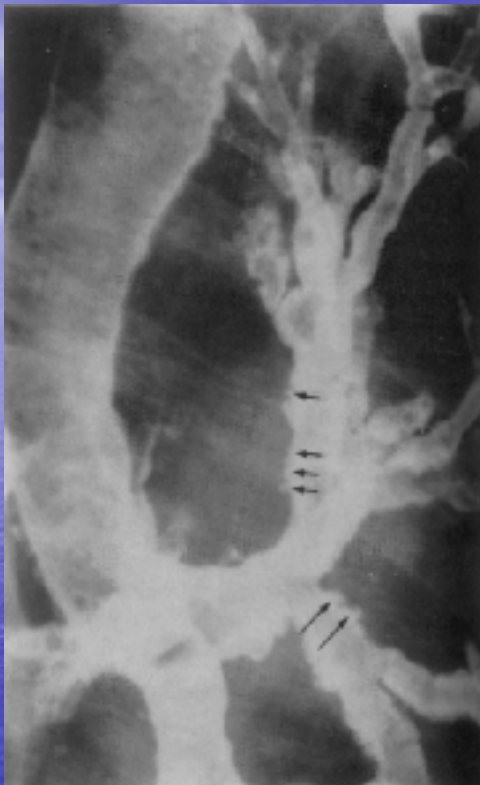
Emfizemul bulos, dreapta bulă de emfizem evidențiată CT



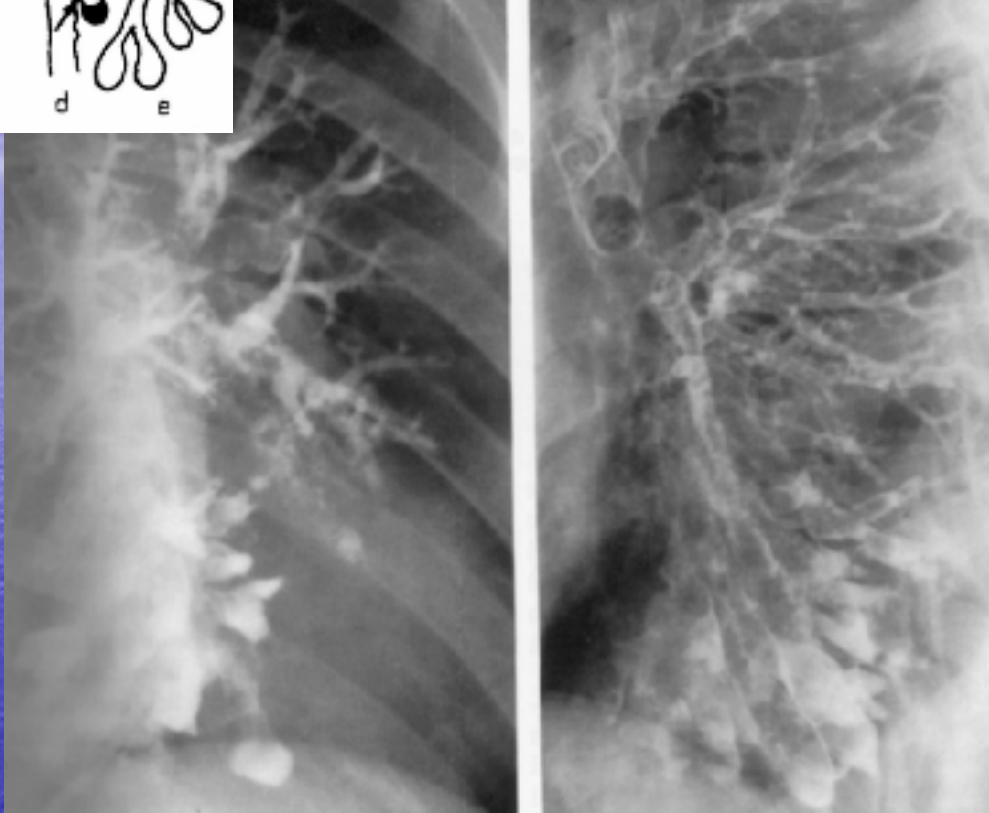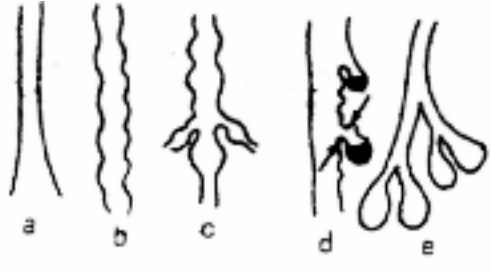
Atelectazia pulmonară



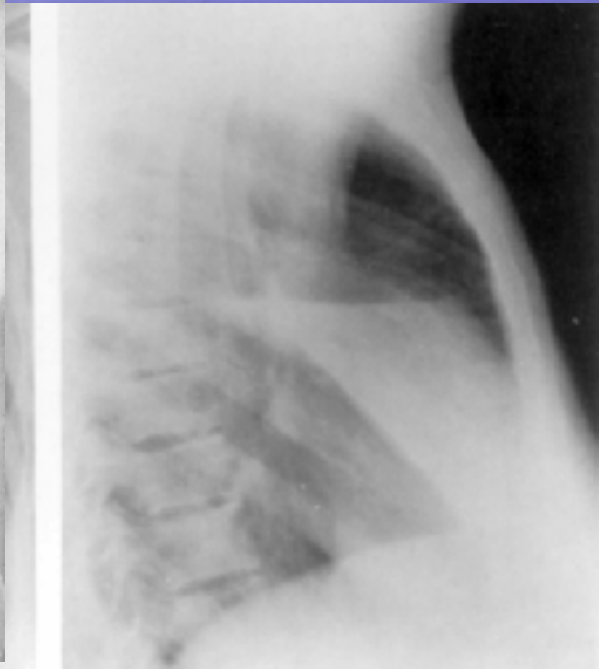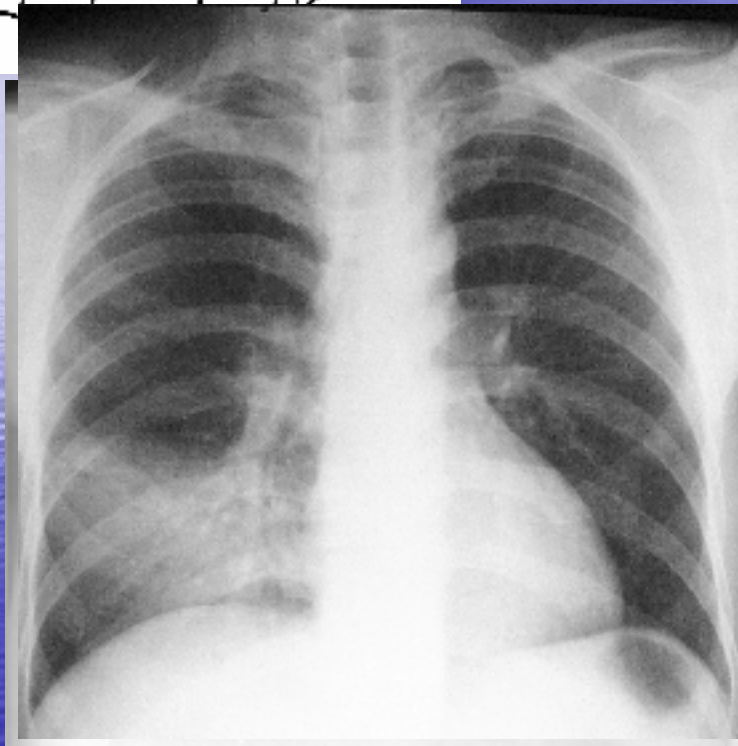
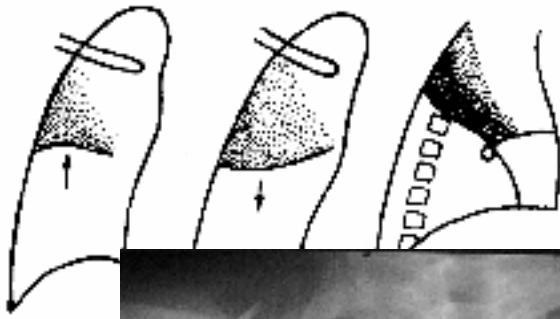




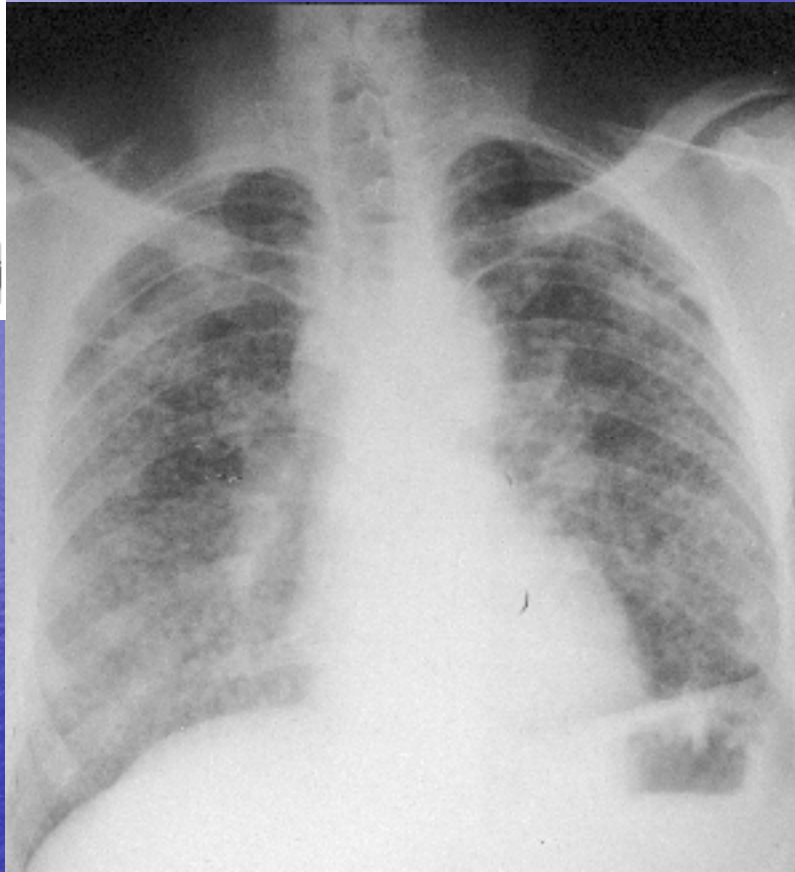
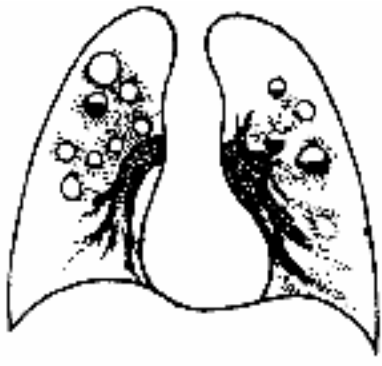Modificări de bronșită cronică



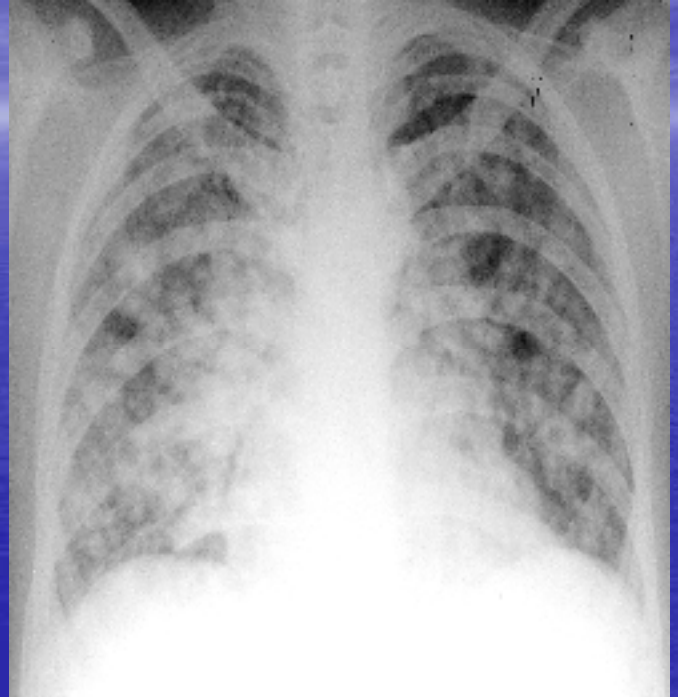
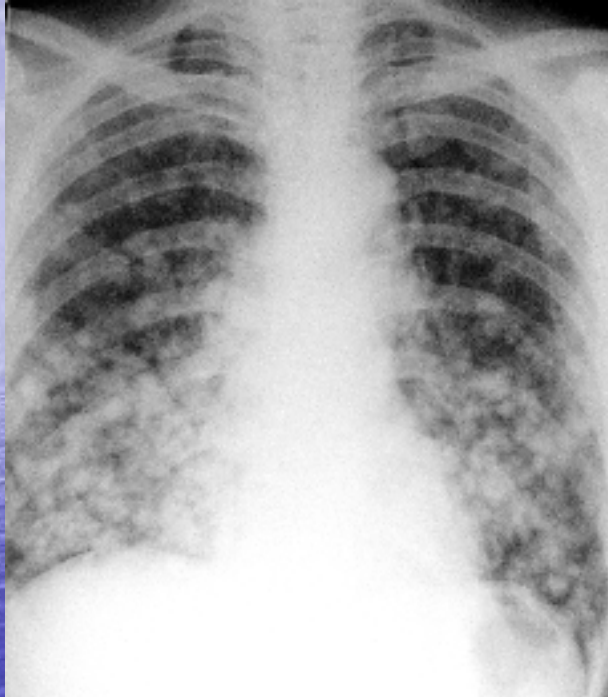Bronhografie cu modificări de bronșiectazii ampulare și sacciforme



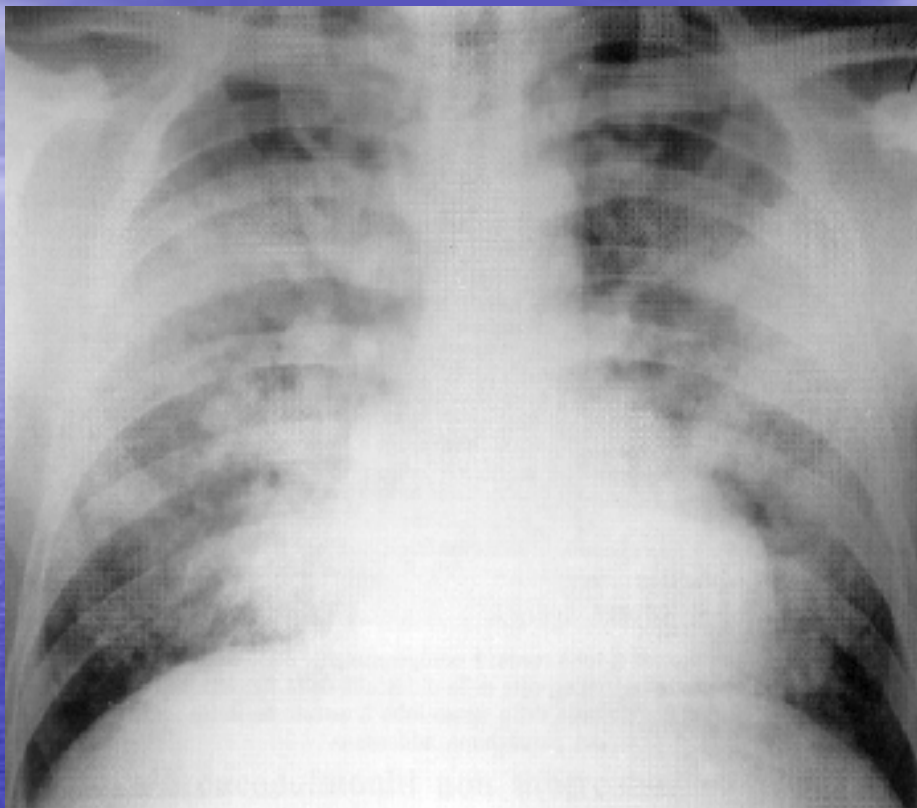
Pneumonie lobara medie dreaptă



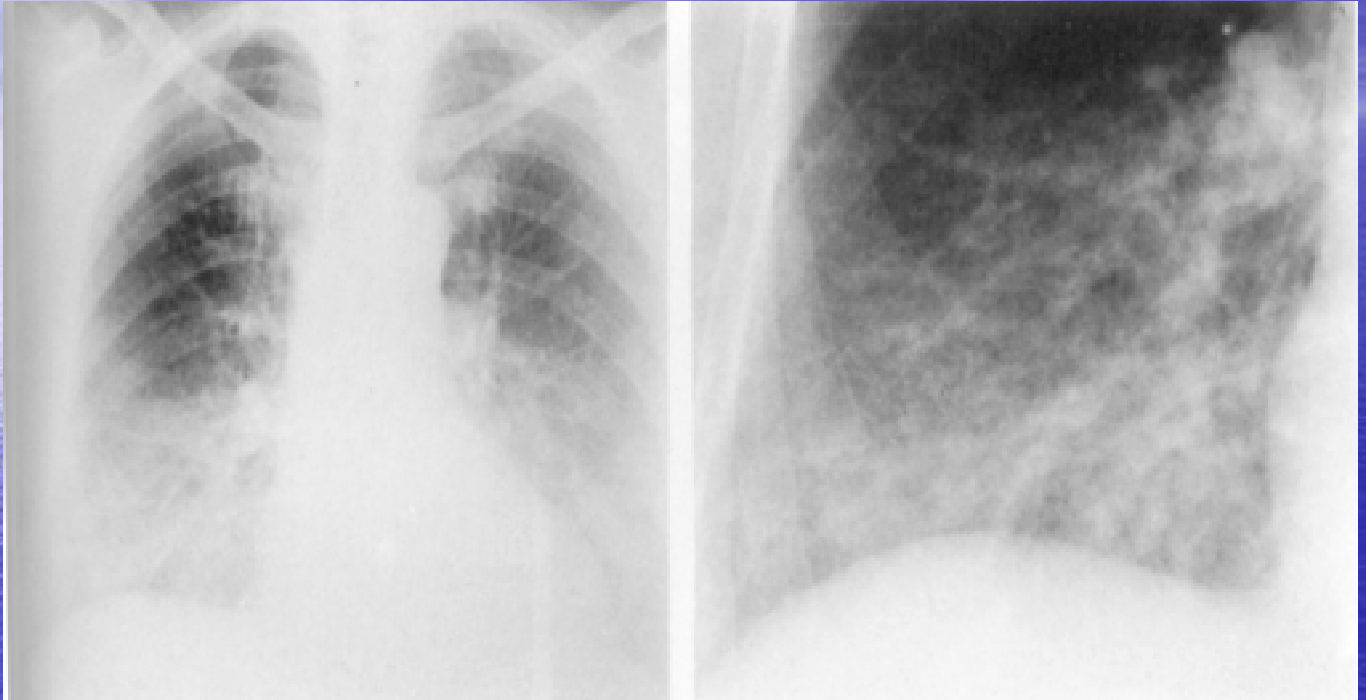
Pneumonia stafilococică



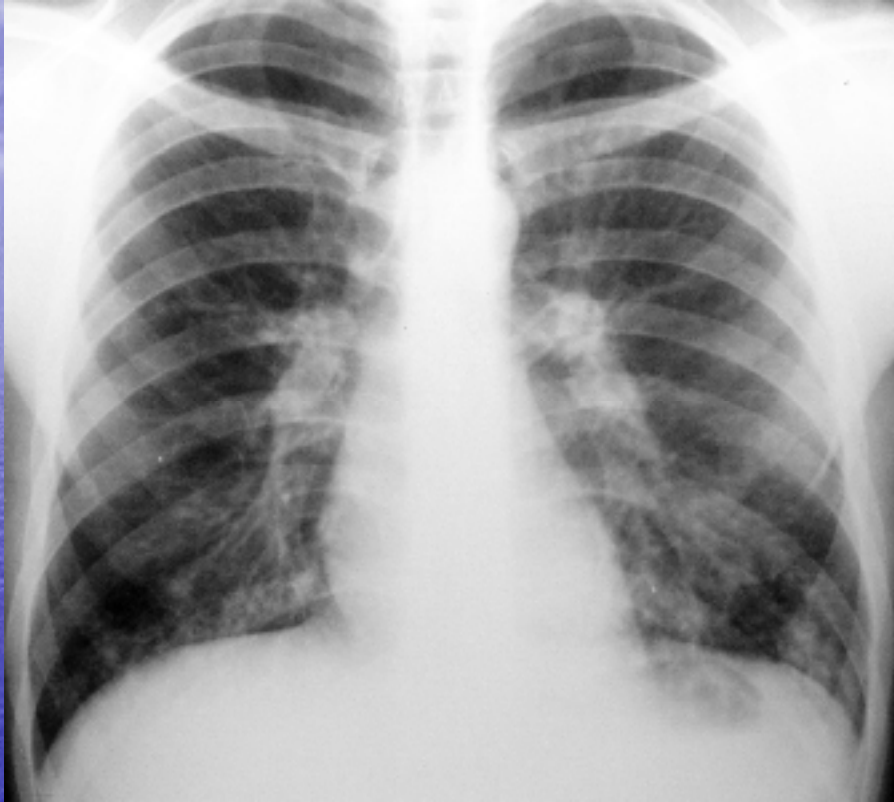Bronhopneumonia nodulară



Bronhopneumonia pseudolobară

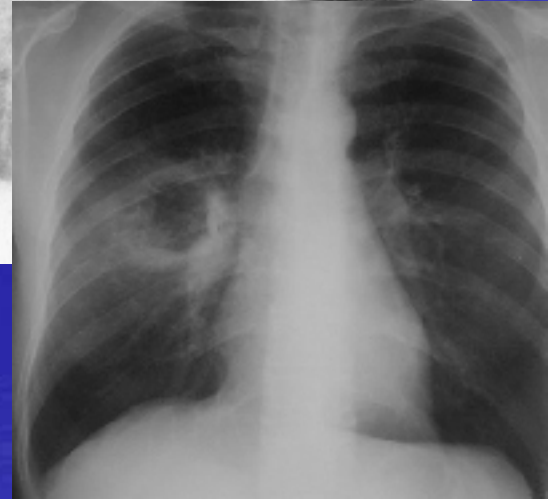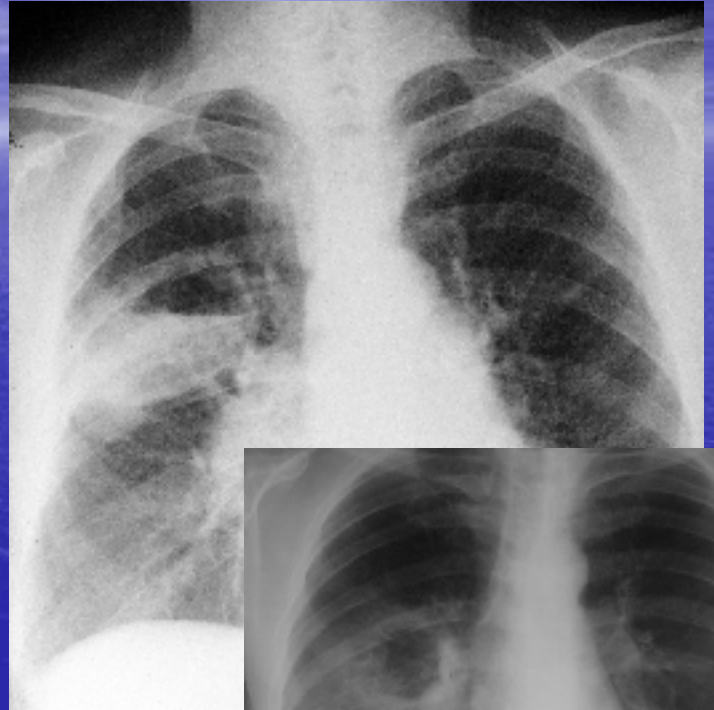

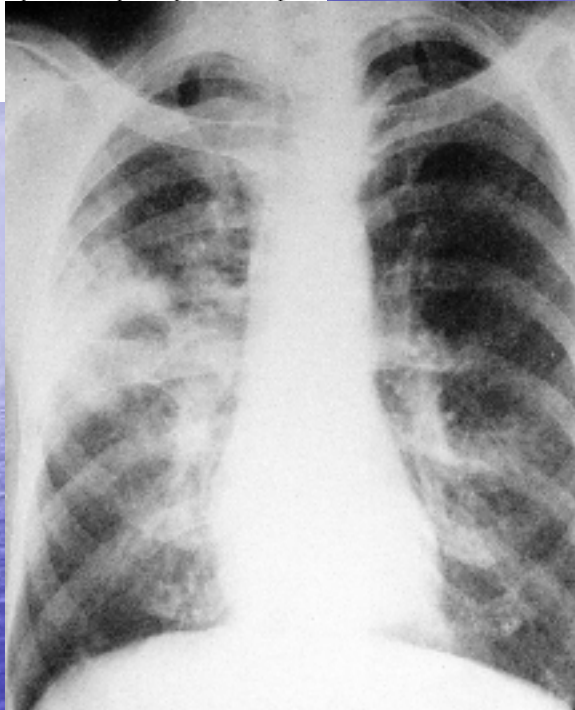
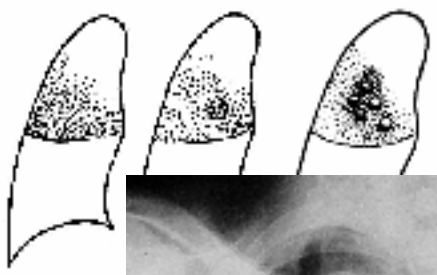Pneumonie interstițială de tip hilar

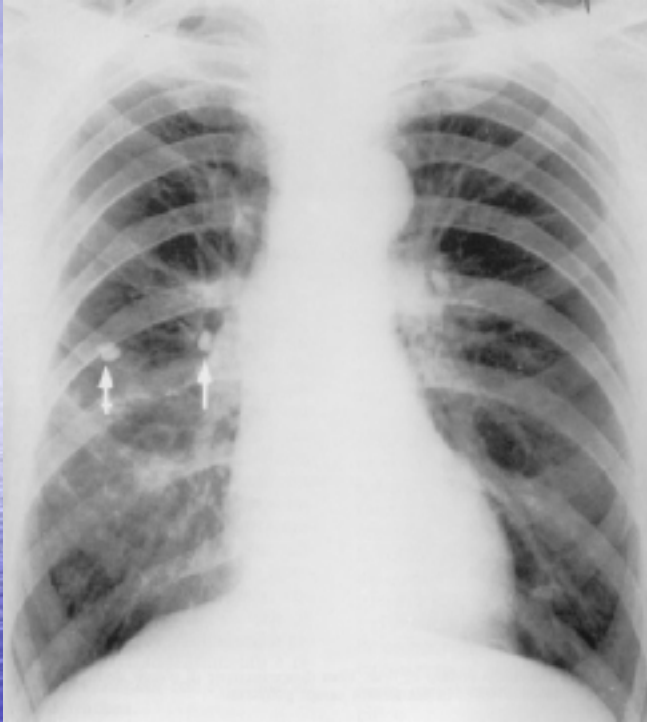

Pneumonie interstițială de tip macronodular

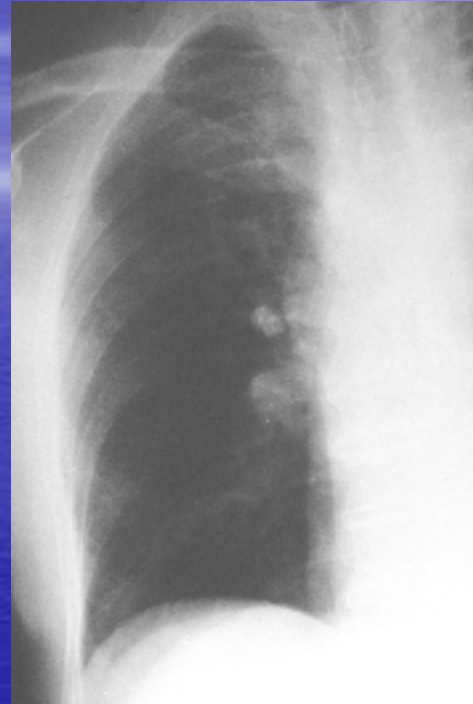




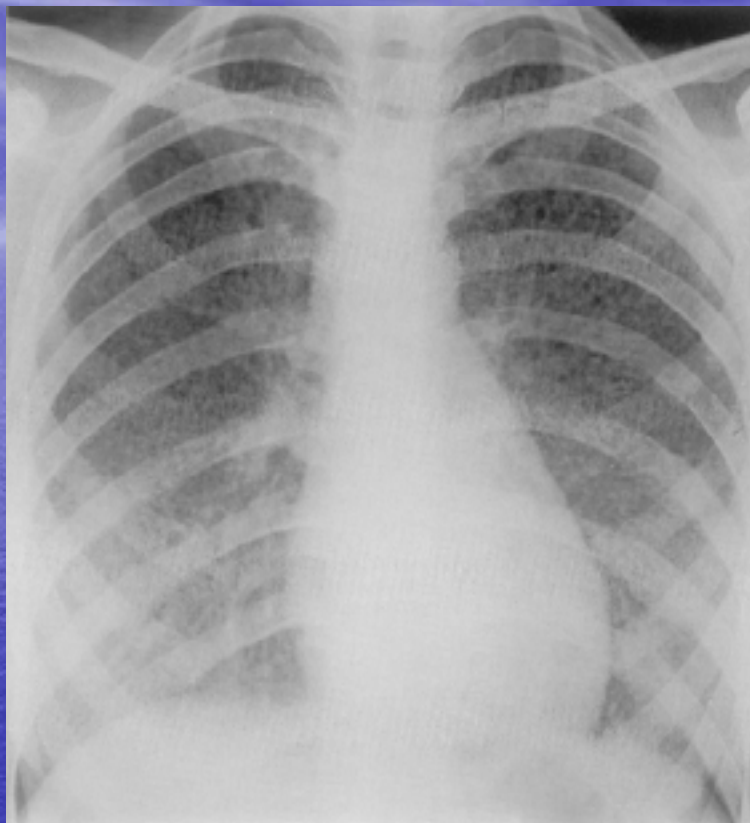
Abces pulmonar drept



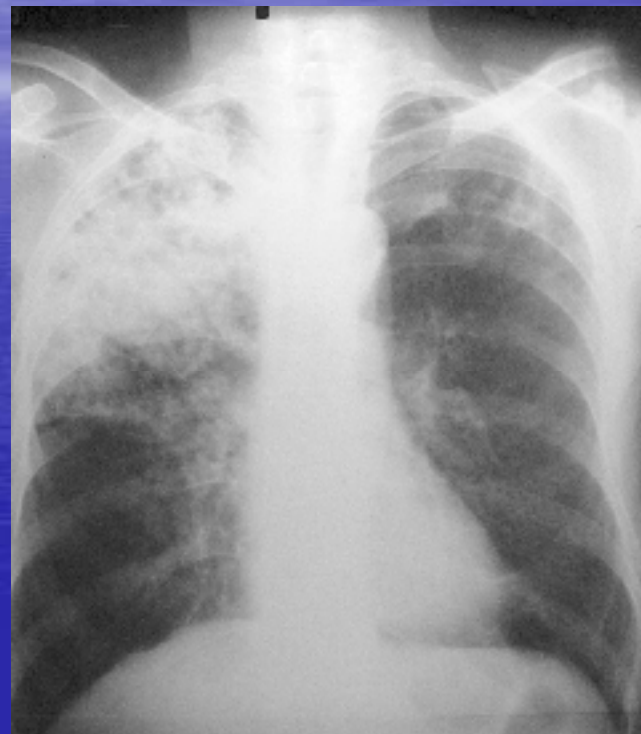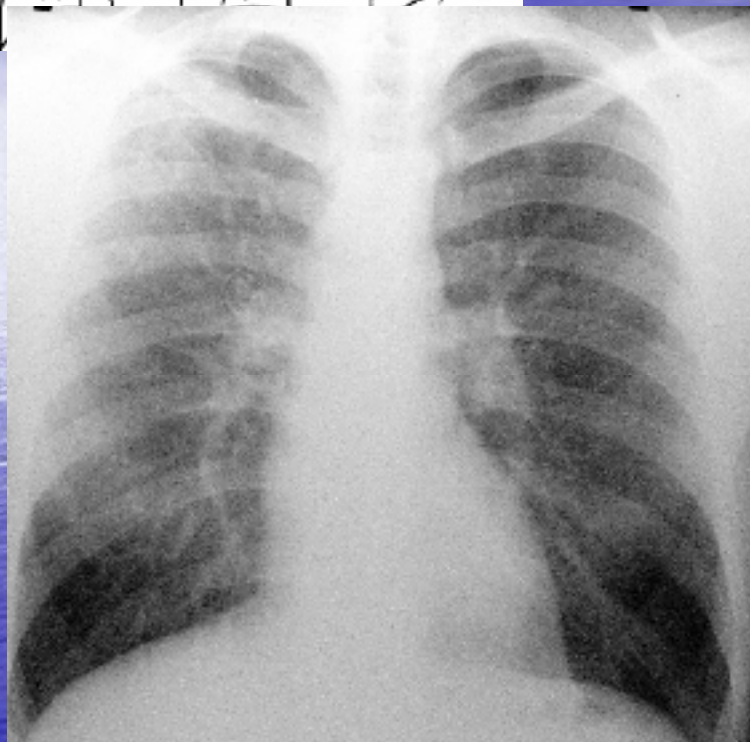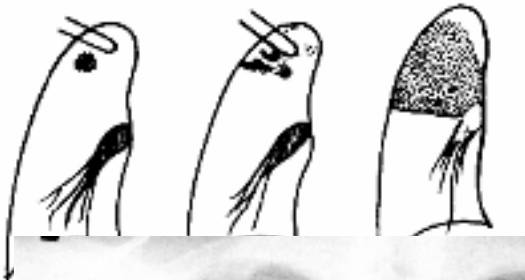afect primar calcificat



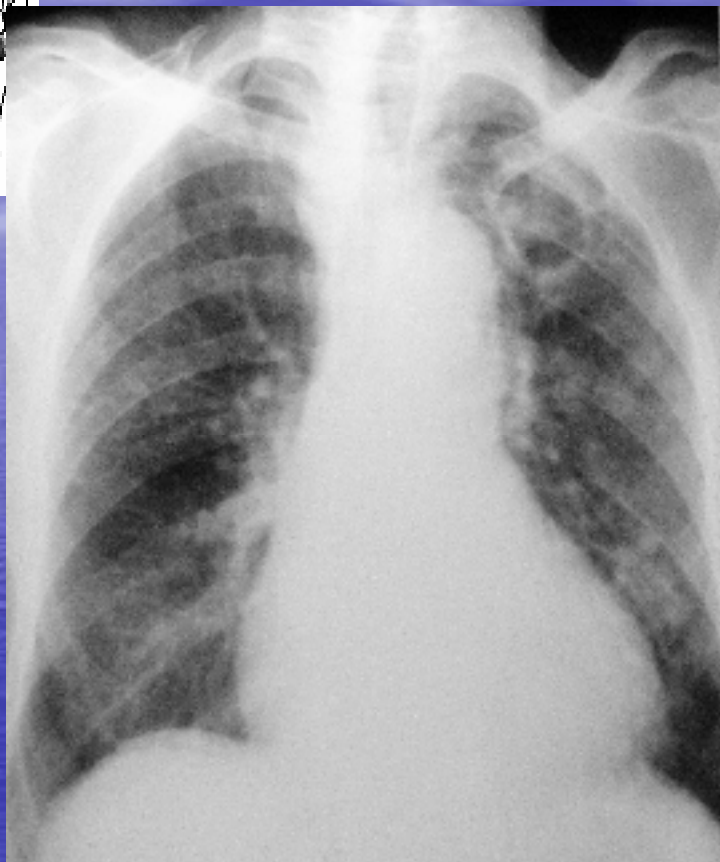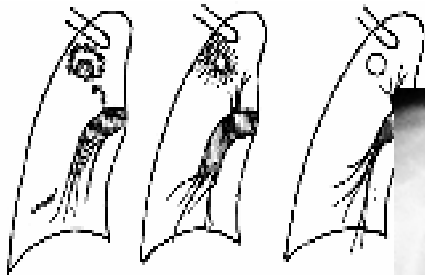
Calcificări ganglionare hilare



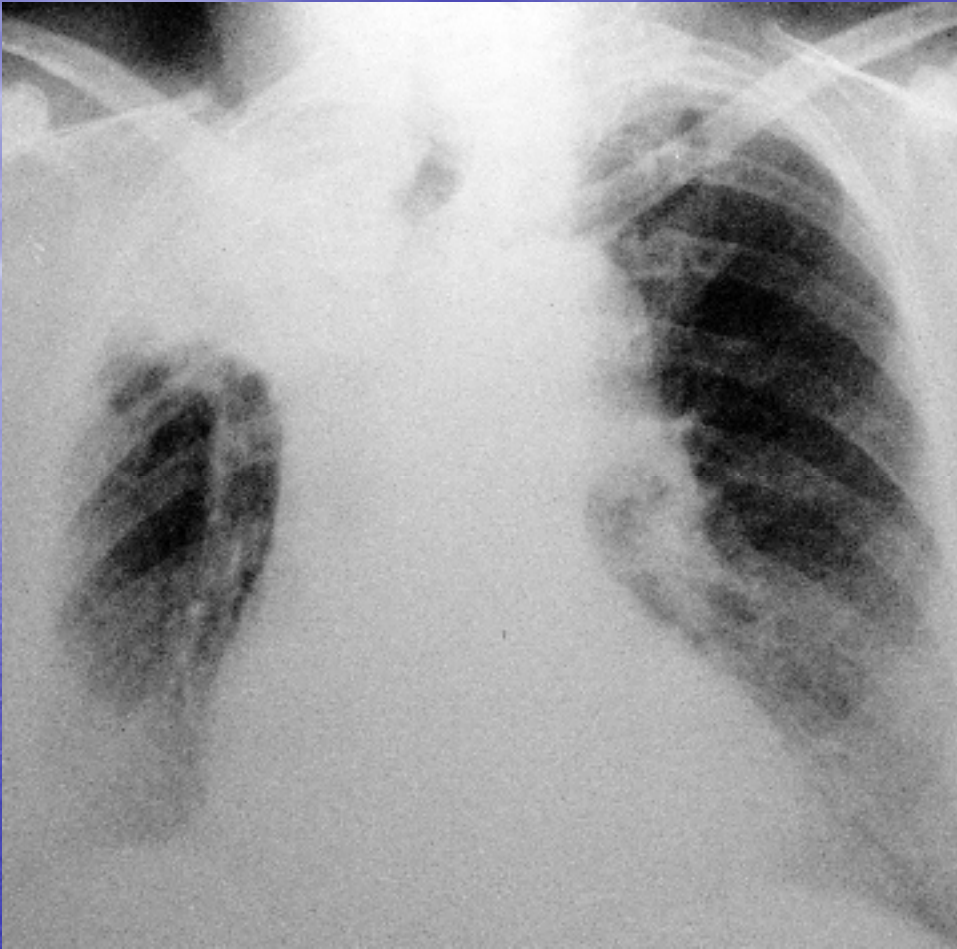
Bronhopneumonie miliară TBC



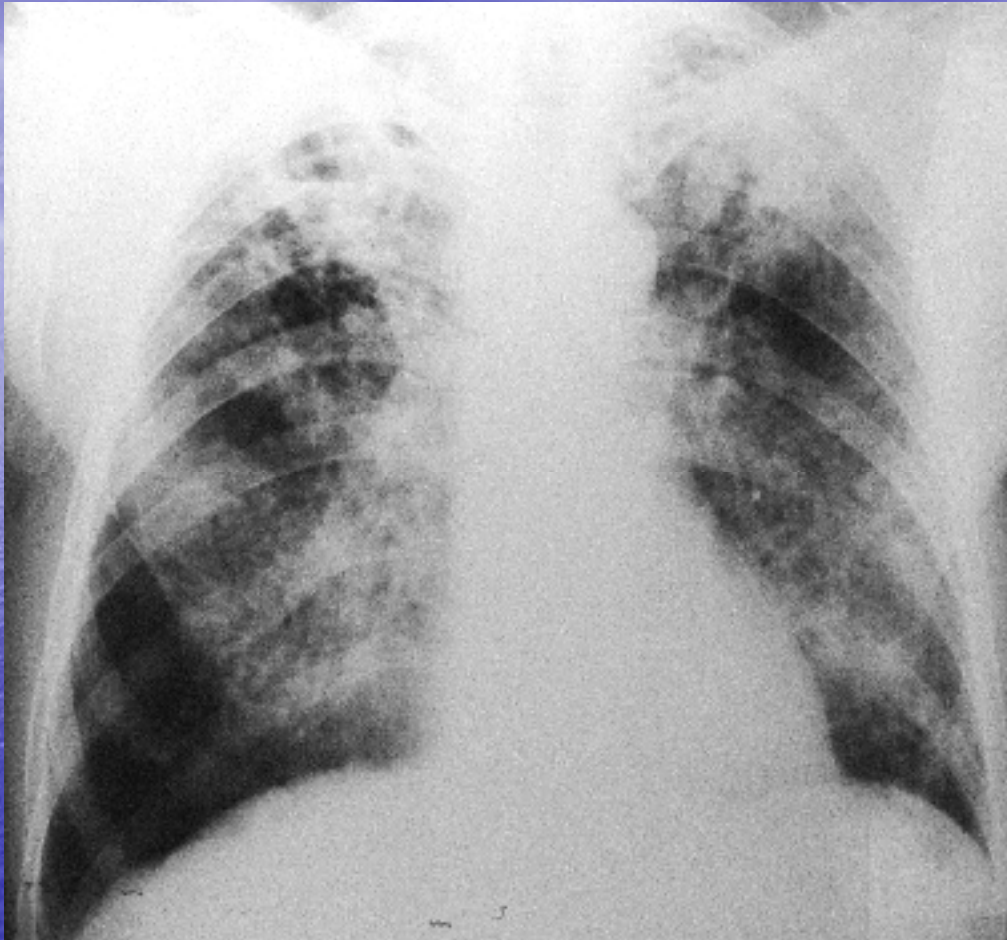
Infiltrat tuberculos subclavicular dreapta



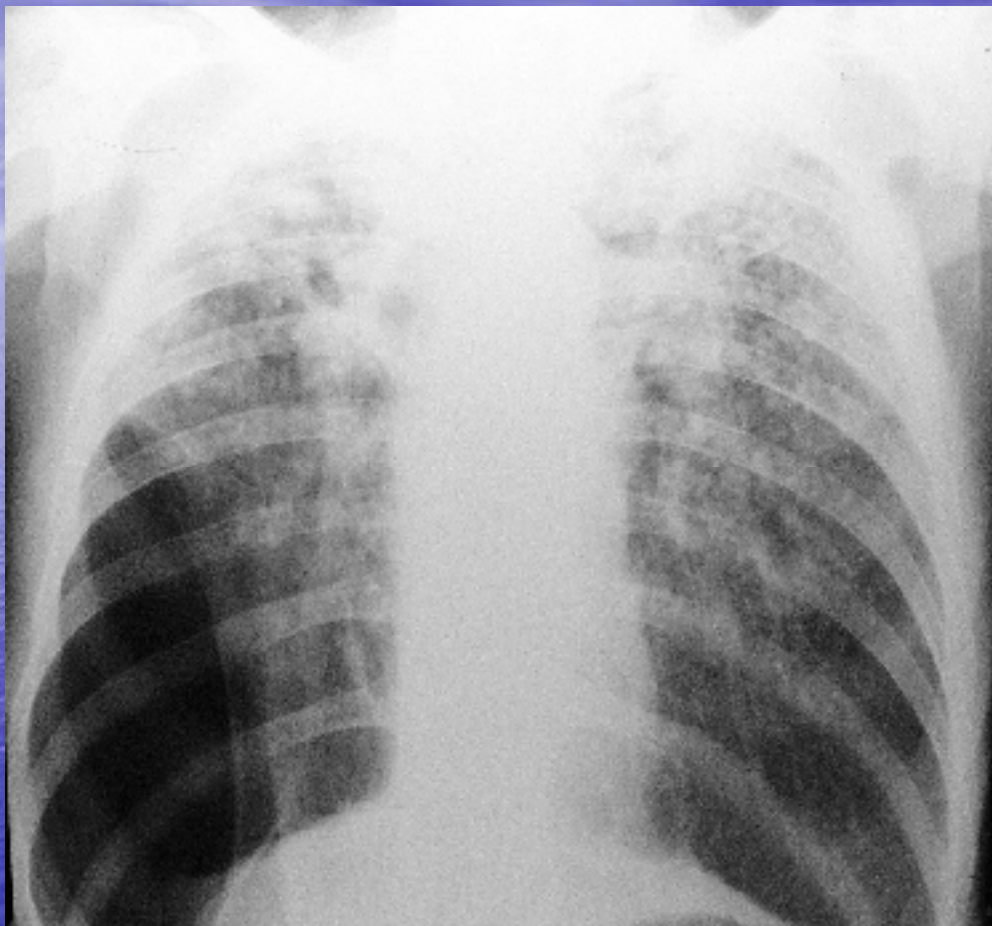
Cavernă TBC subclaviculară stângă



Tuberculoză fibroasă apicală dreapta

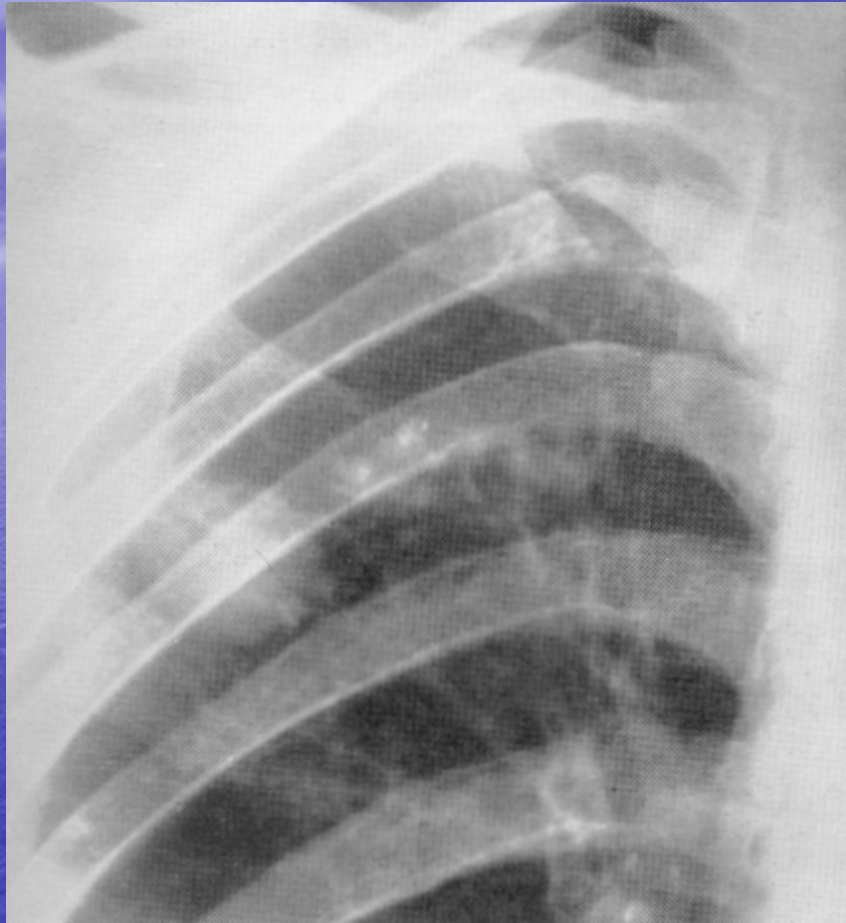

Leziuni fibrocavitare diseminate bilateral

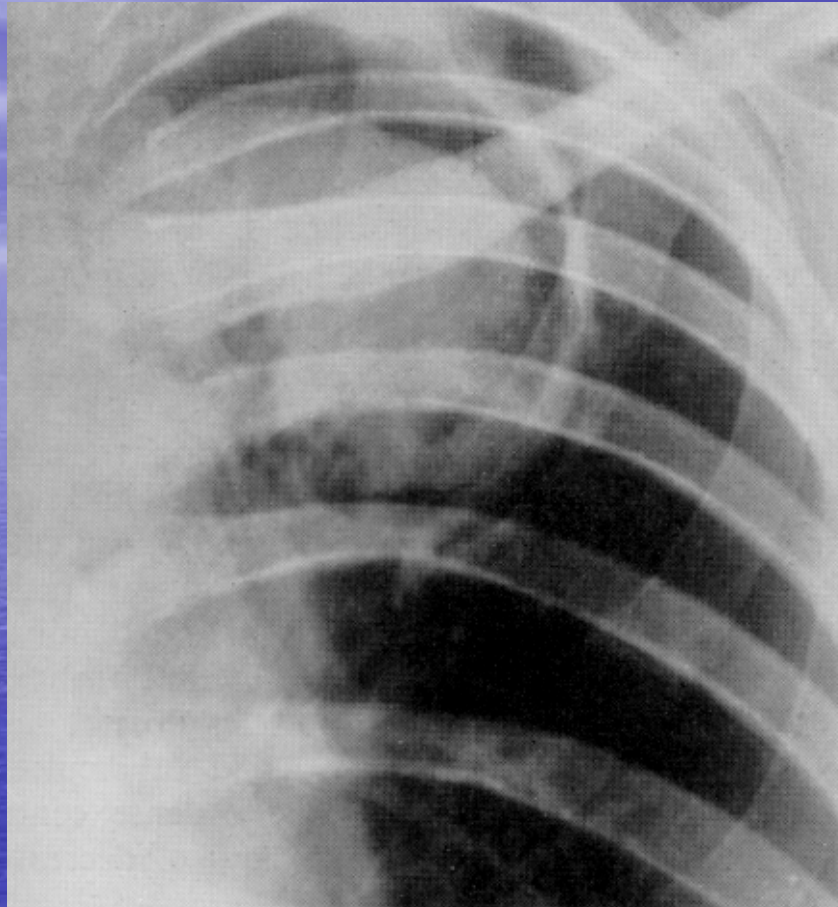


Fibrotorax posttuberculos cu pneumotorax închistat bazal dreapta

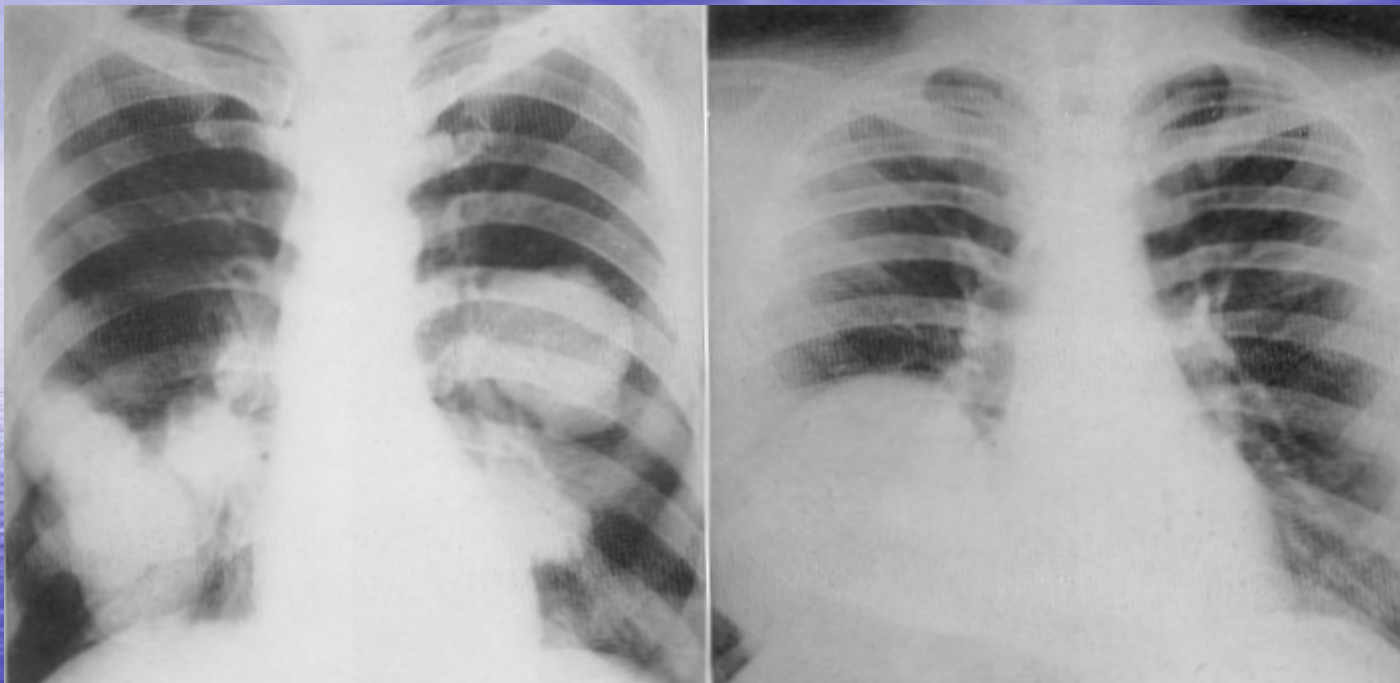




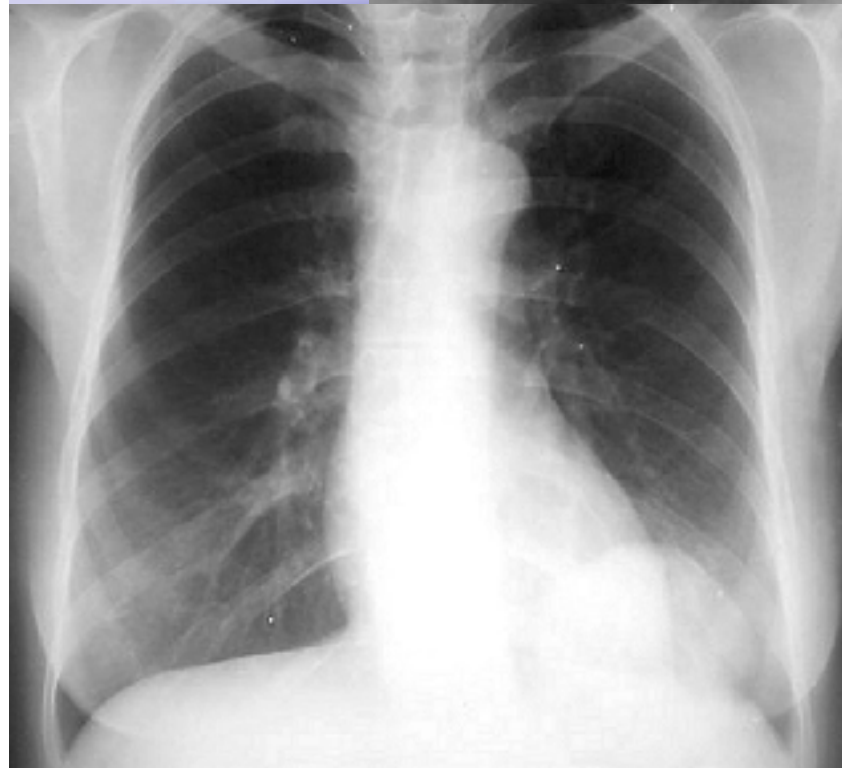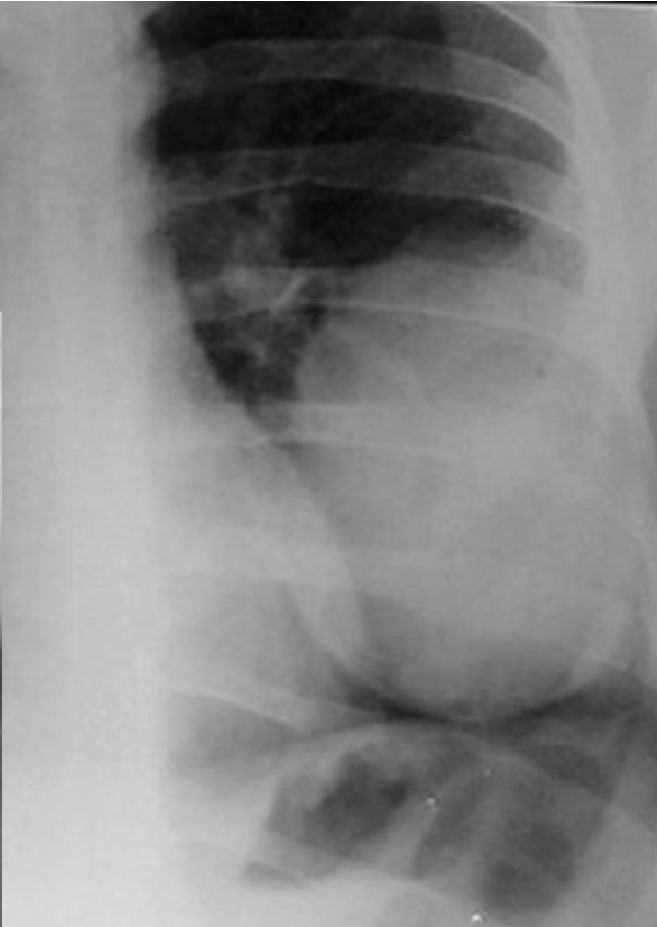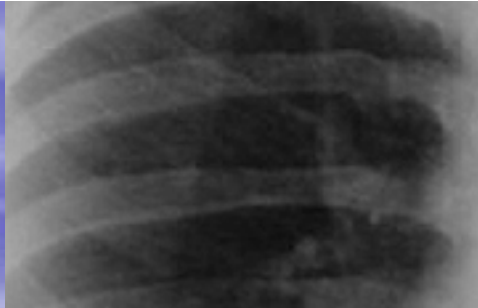
Tuberculom subclavicular dreapta



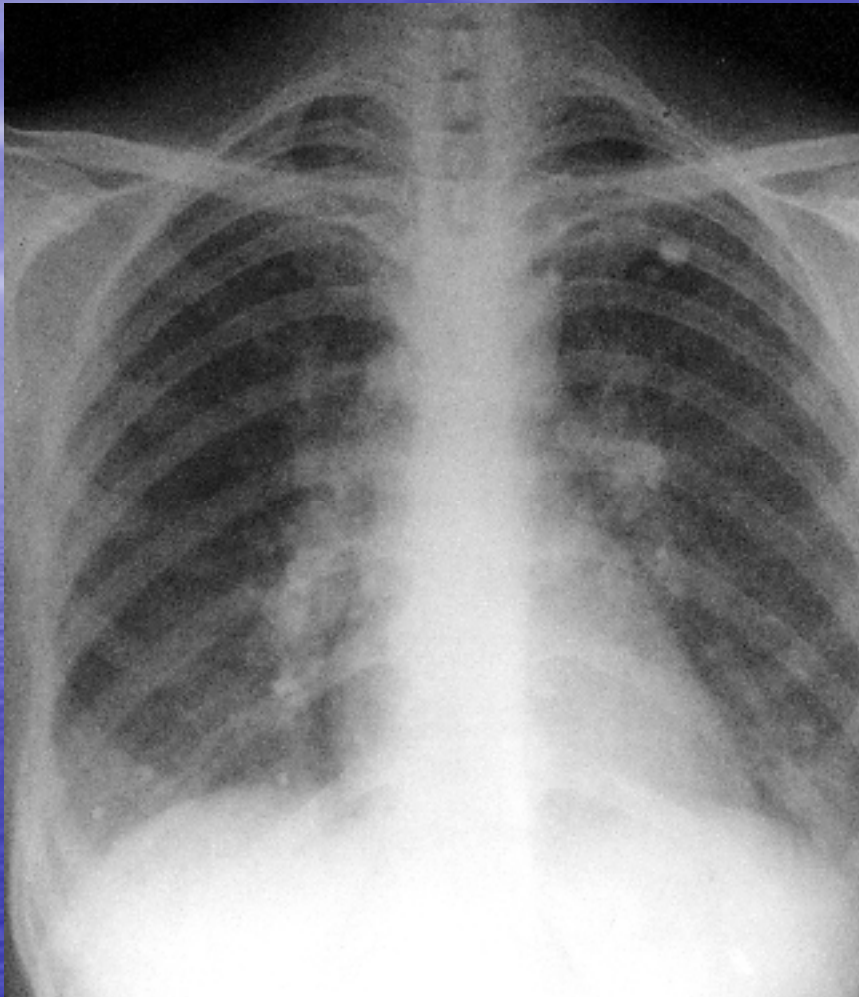
Micetomul



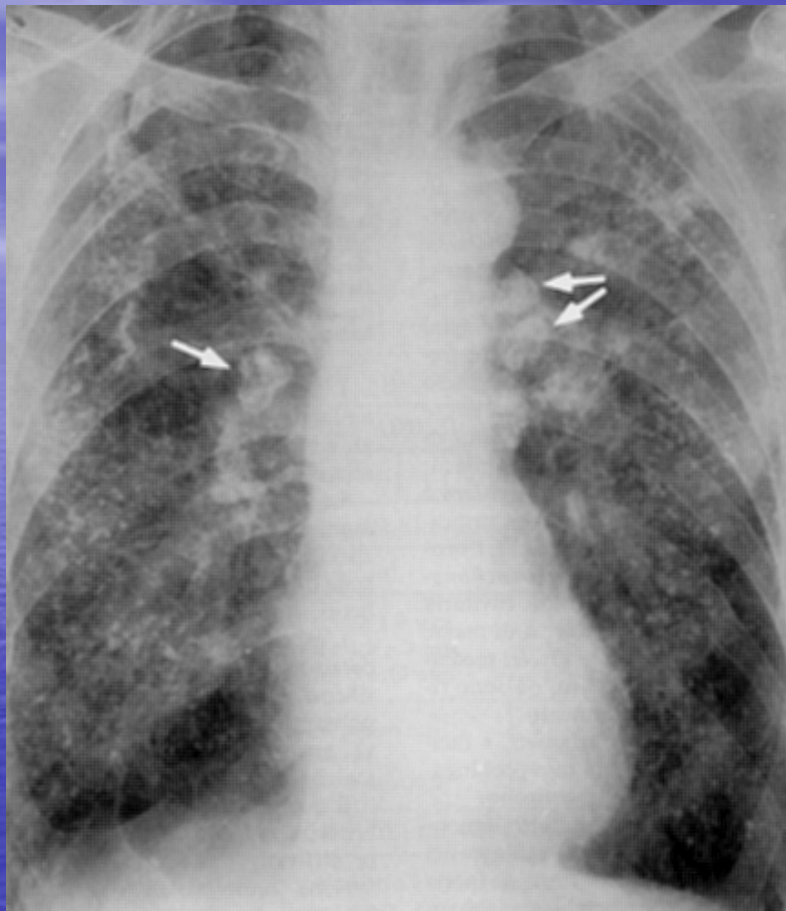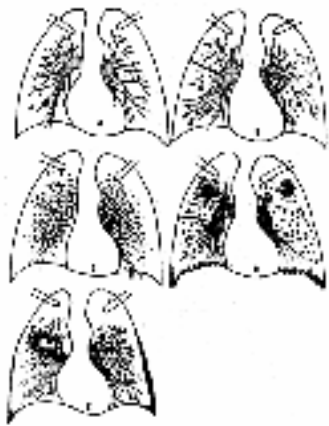
Echinococoză pulmonară- stânga multiplă, dreapta unică



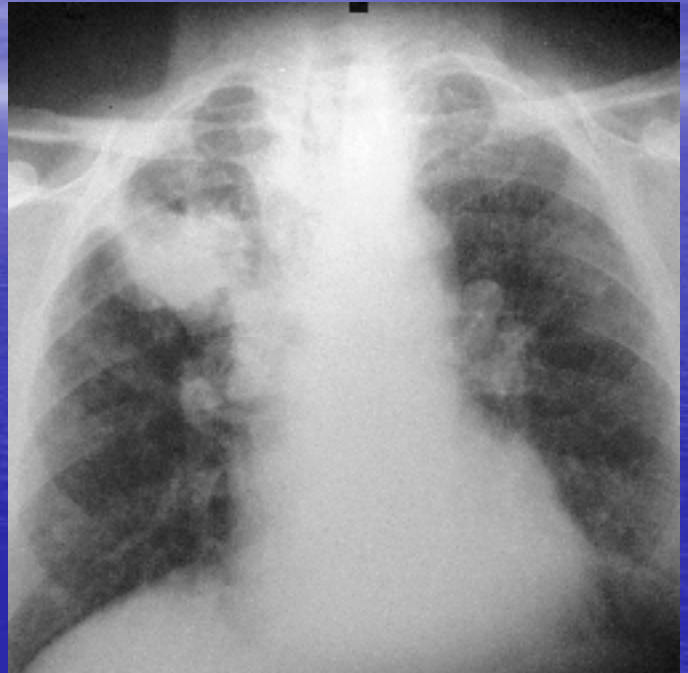
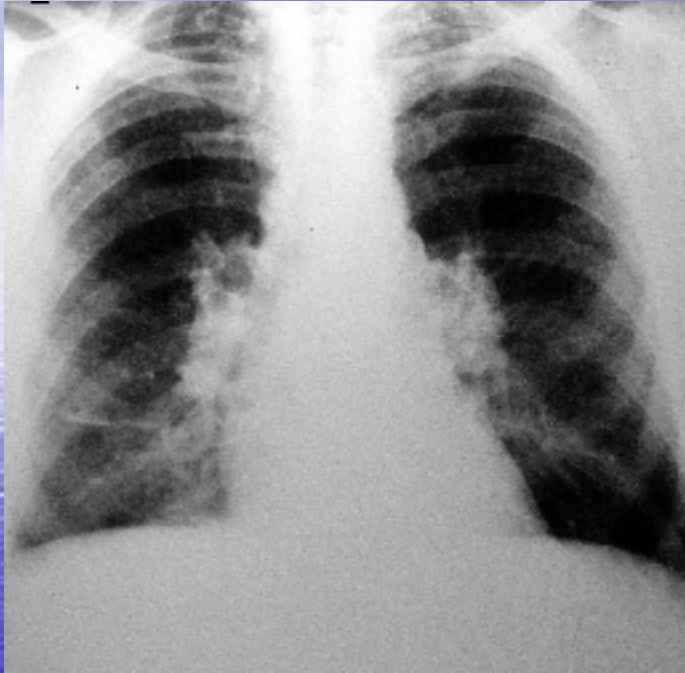
Echinococoză pulmonară-



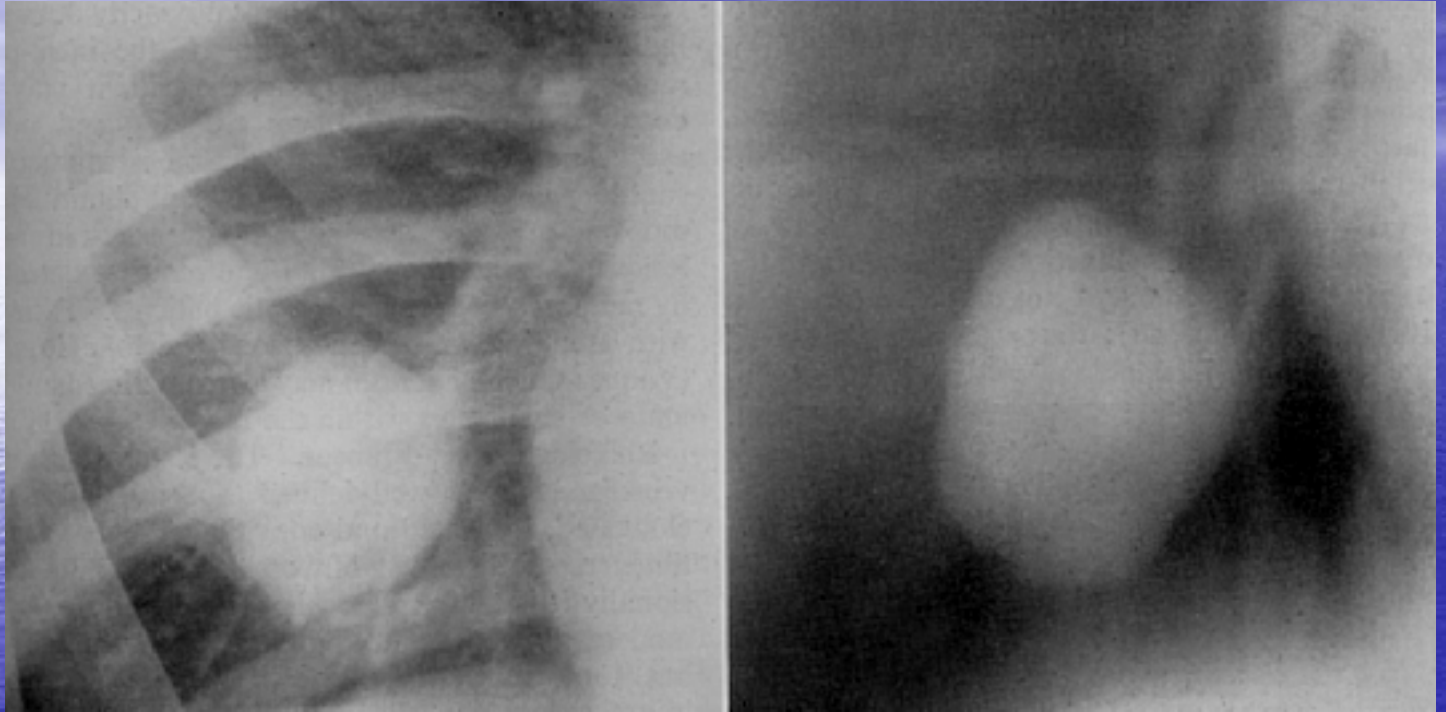
Cisticercoza pulmonară



Modificările din silicoză; calcificări ganglionare

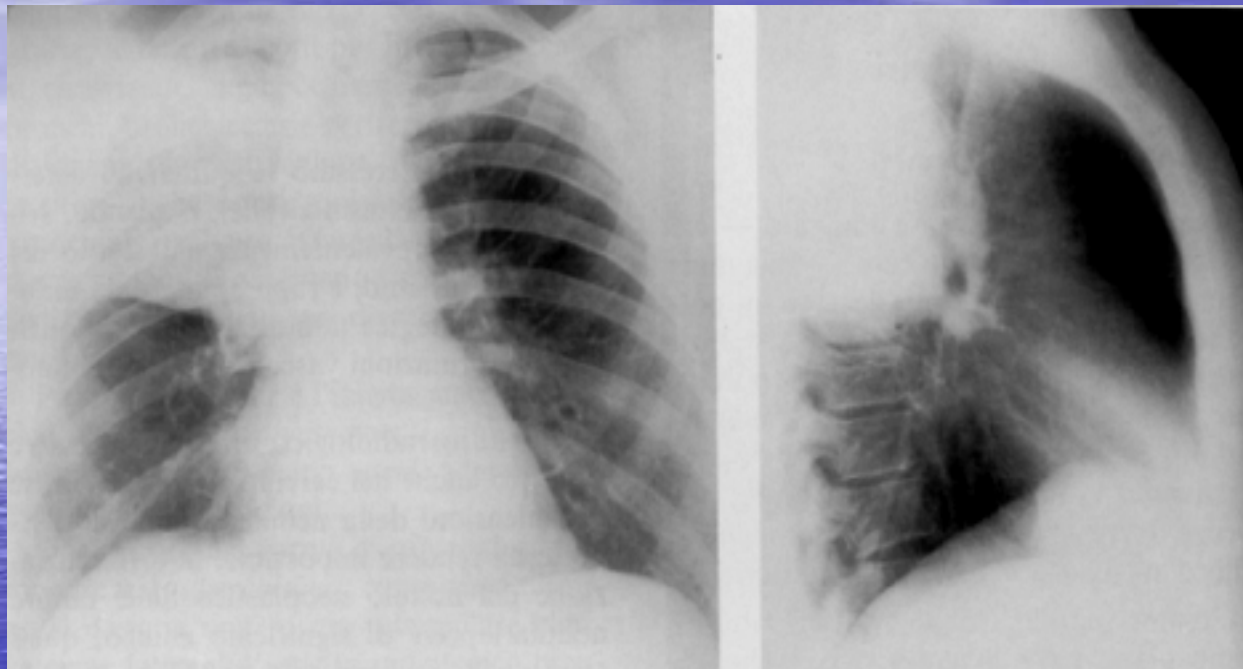


Silicoza stadiul III

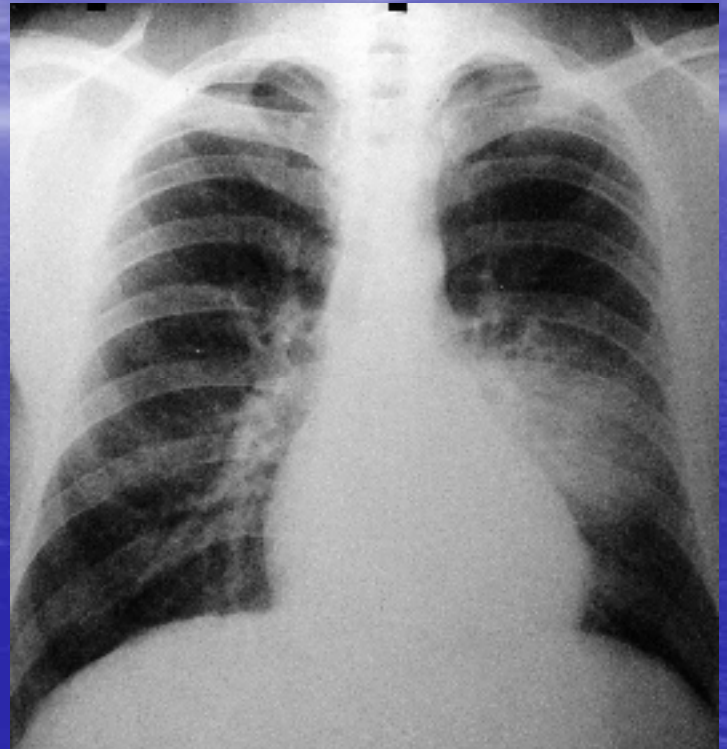
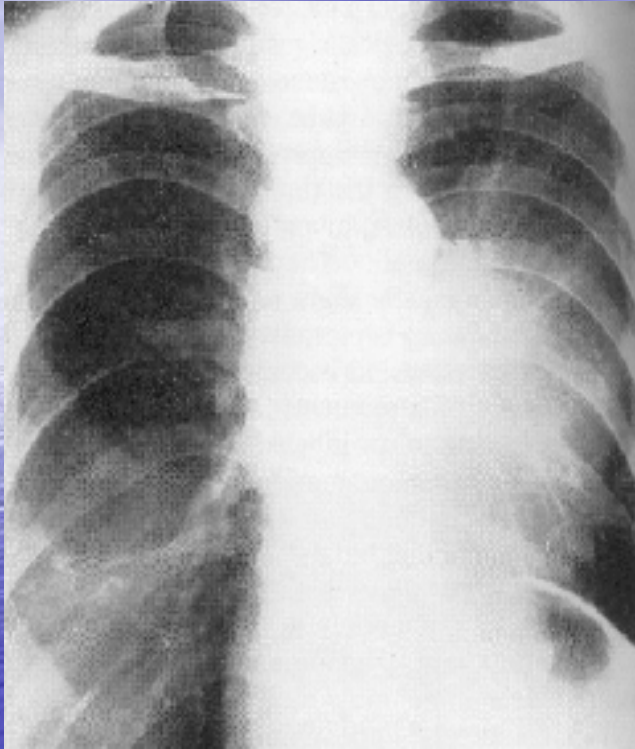


Tumoră benignă pulmonară-hamartom

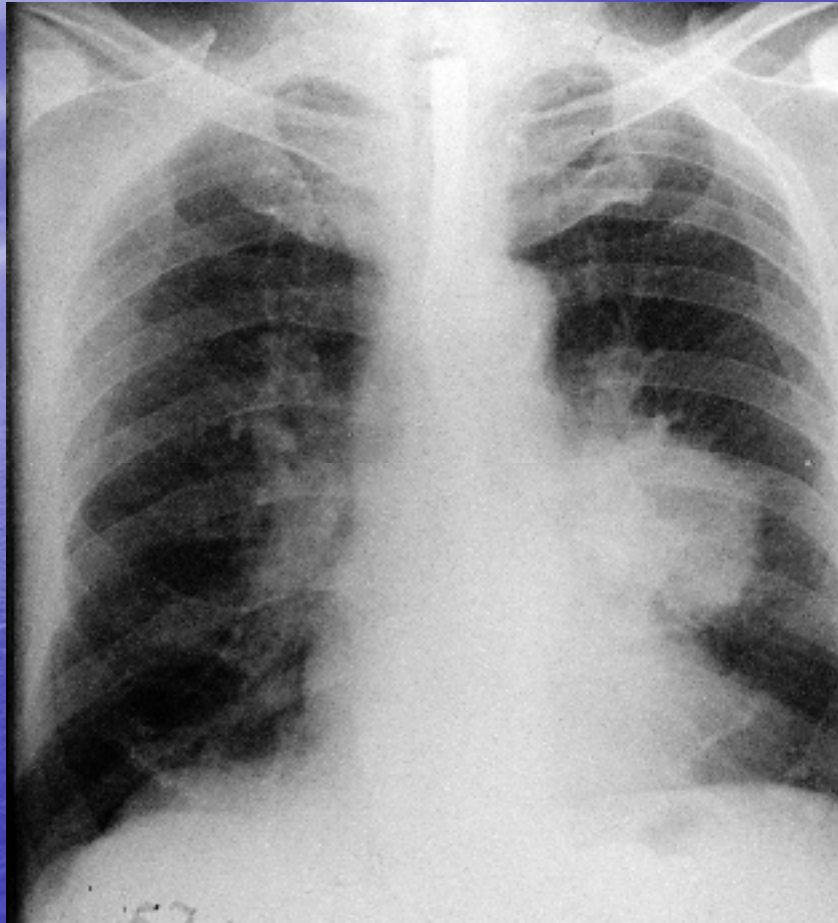




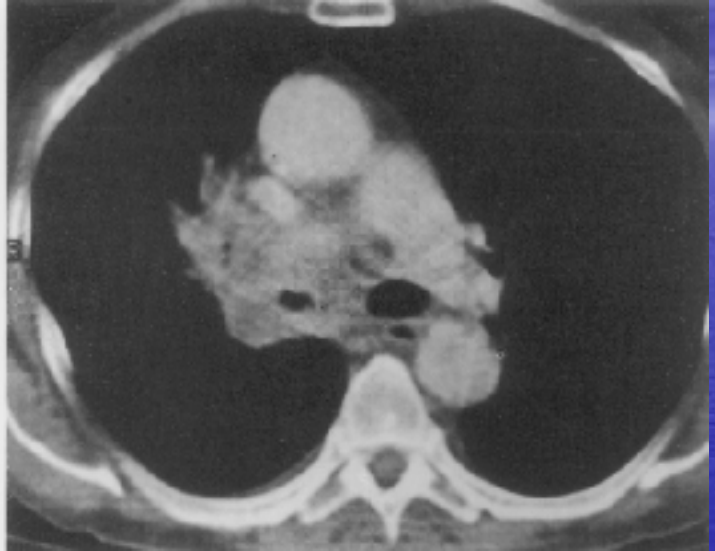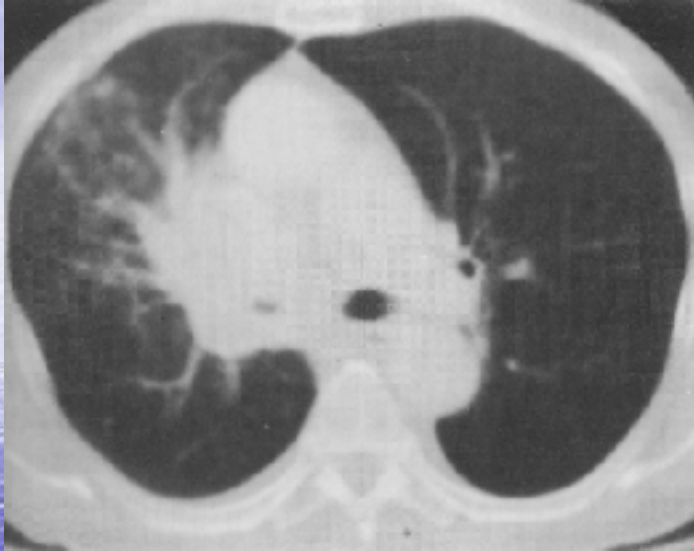
Modificări atelectatice în cancerul endobronșic



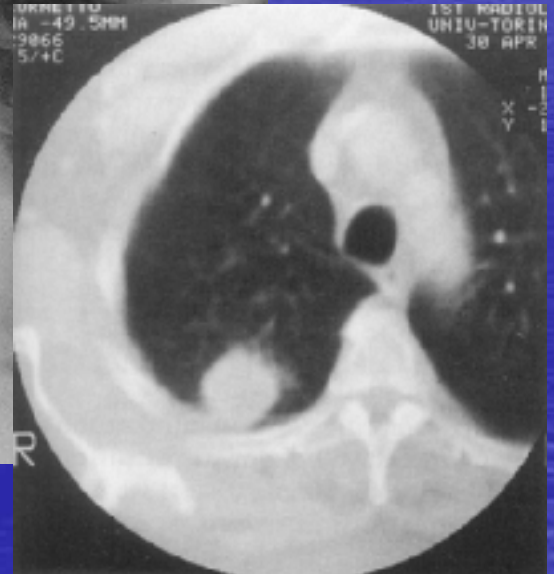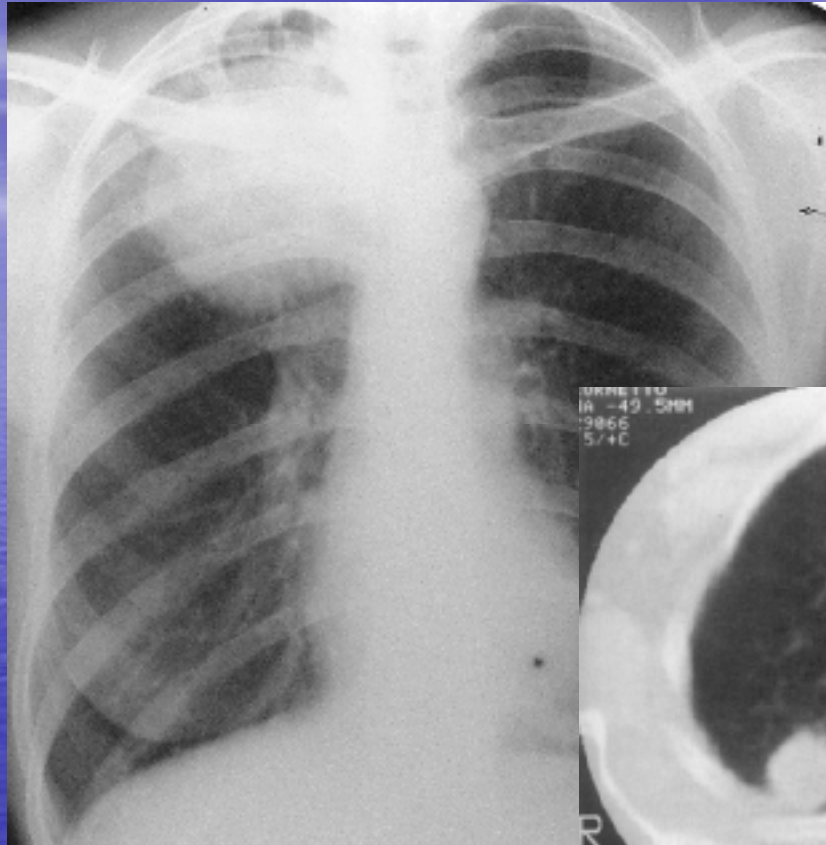
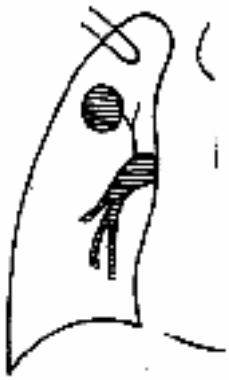Cancer exobronșic hilar stânga



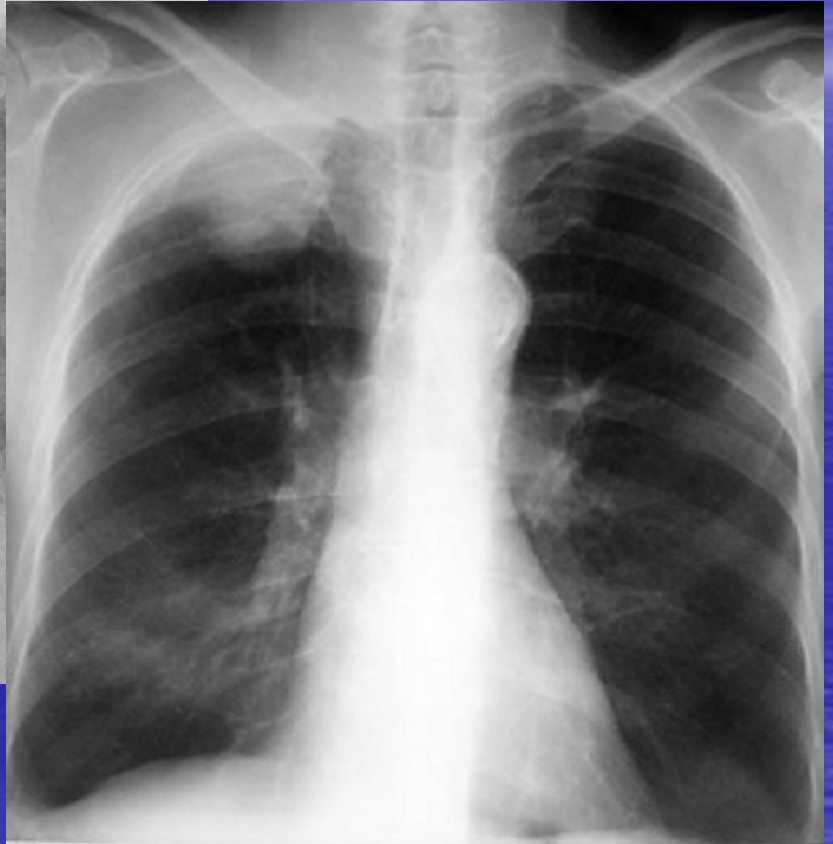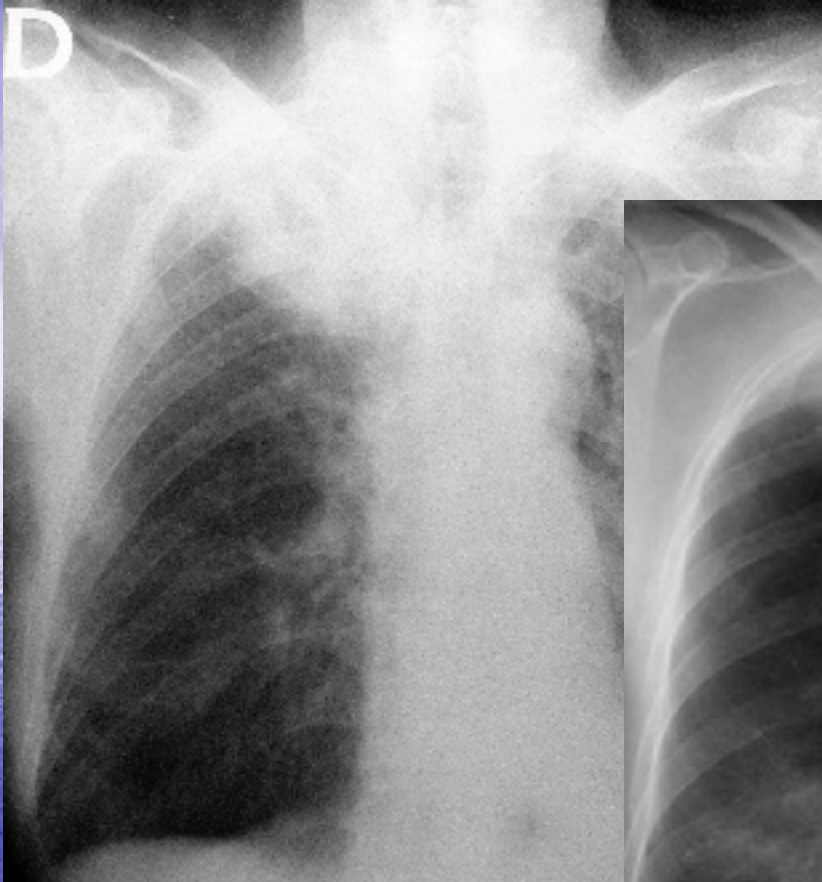
Cancer nodular central



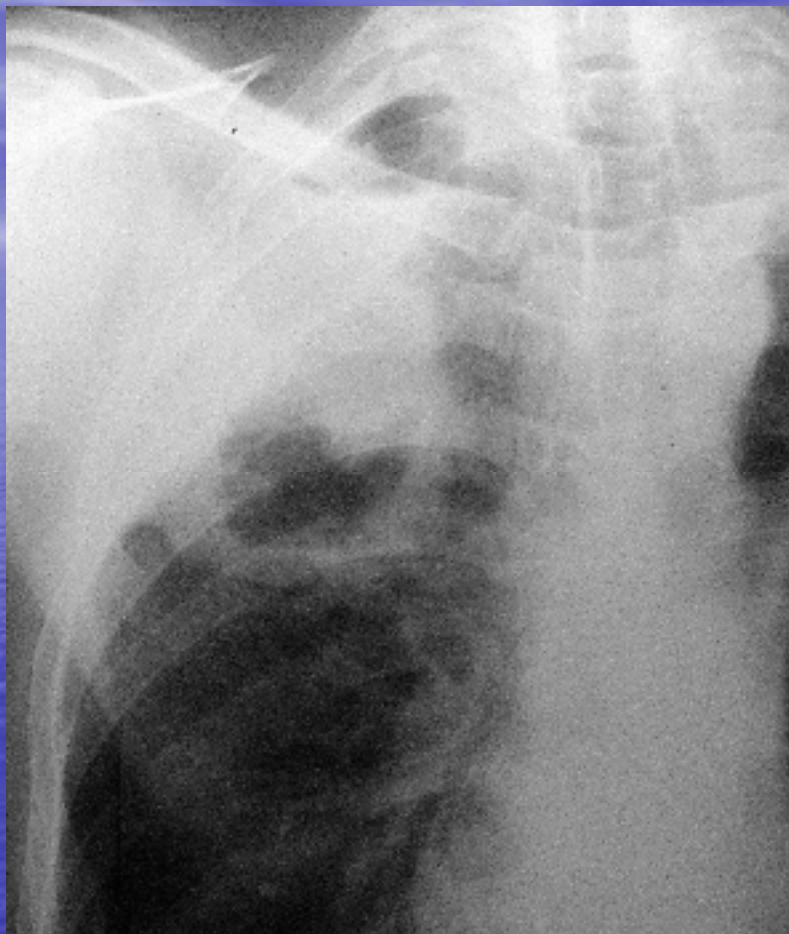
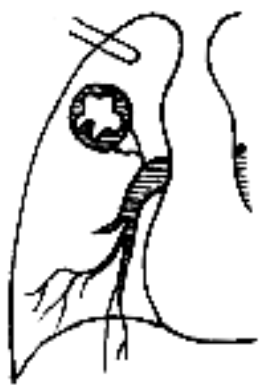Tomografie computerizată cancer central



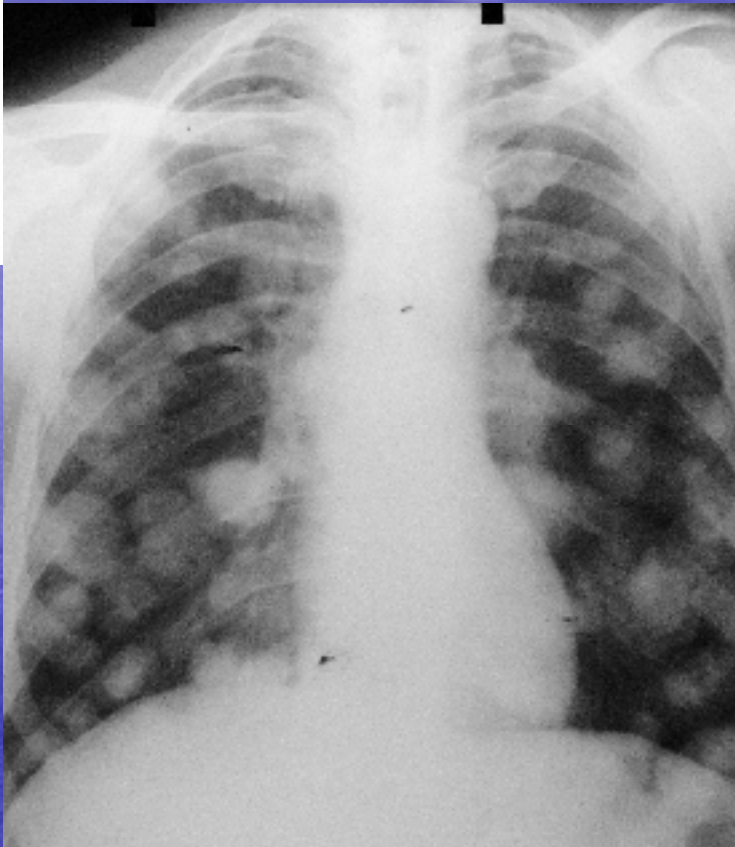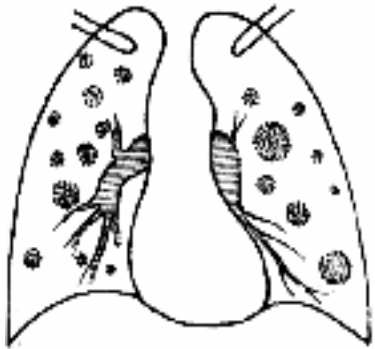
Cancer pulmonar periferic



Tumora Pancoast-Tobias

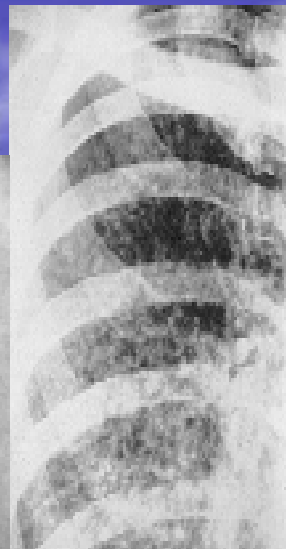
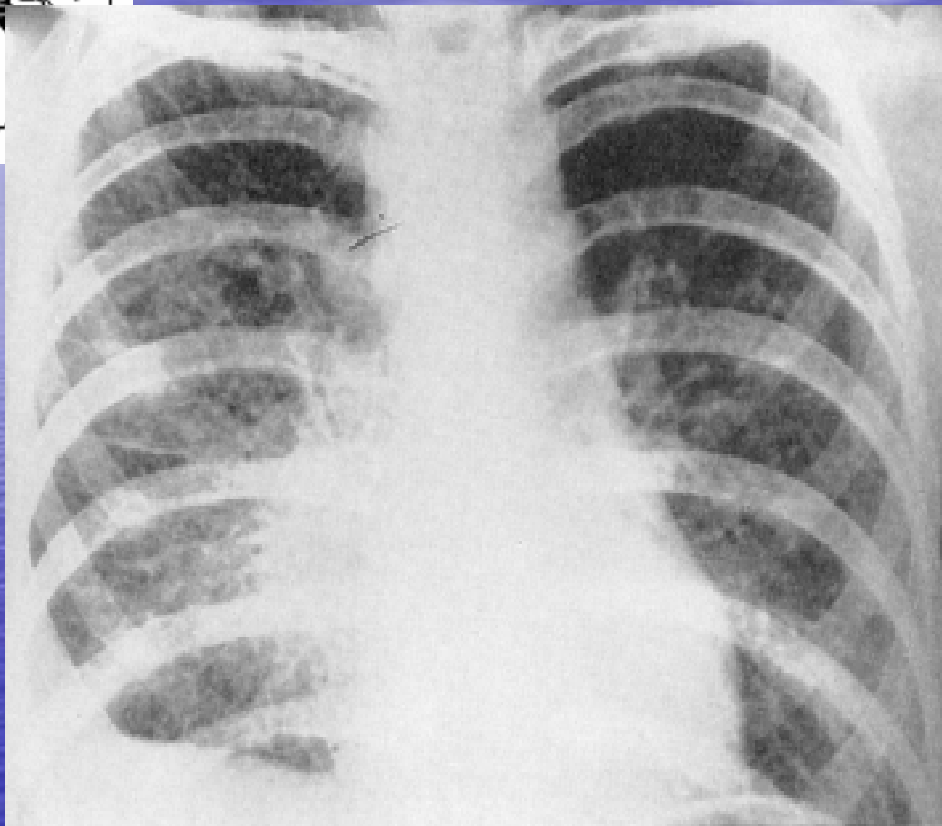
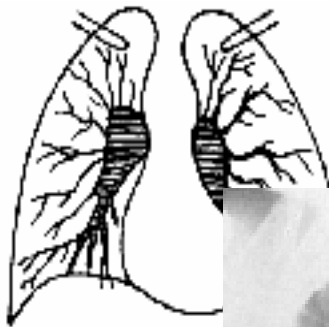


Caverna canceroasă

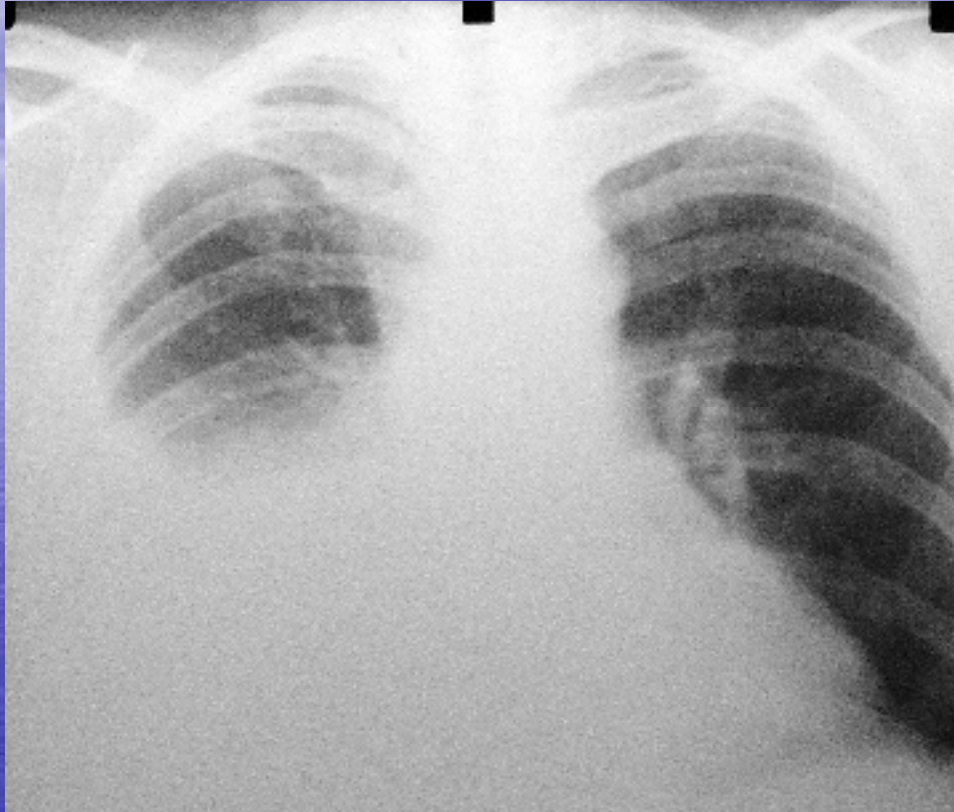
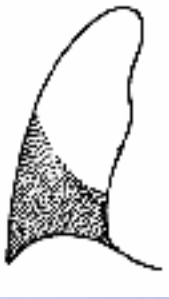

Metastaze pulmonare-forma nodulară

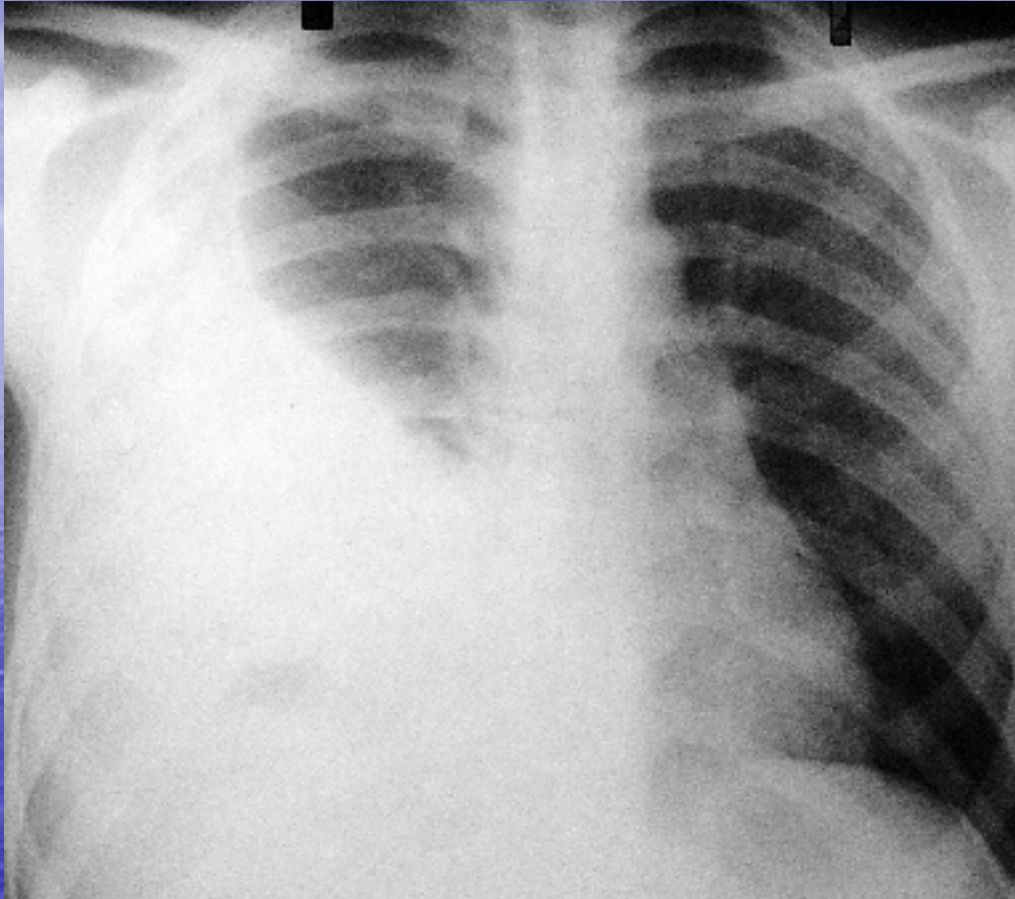




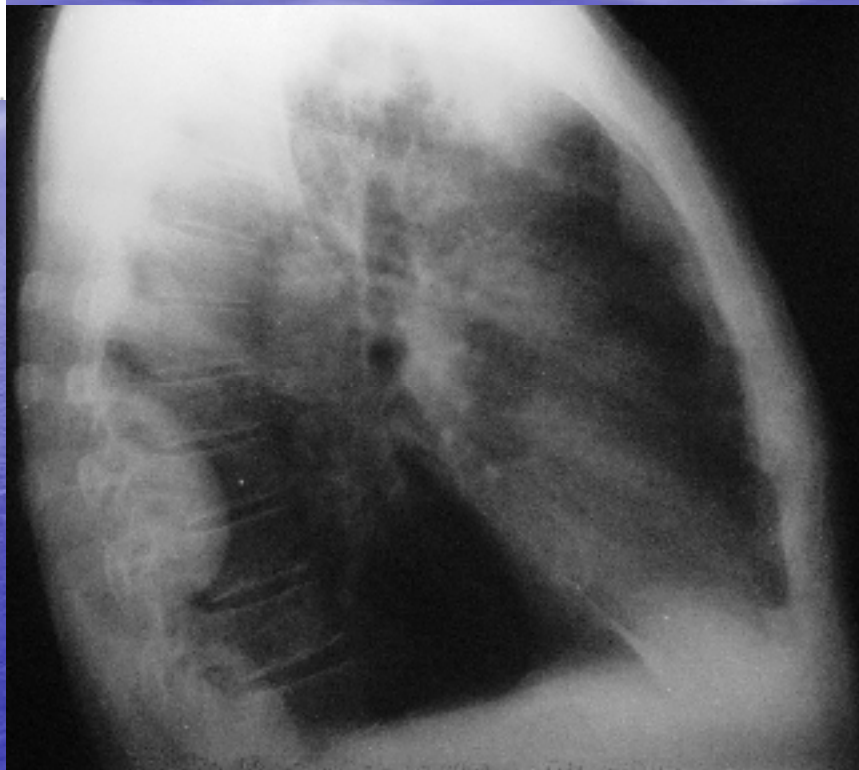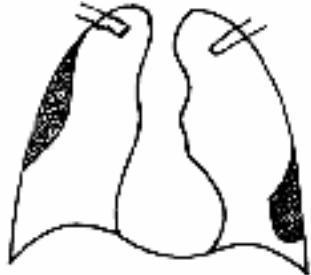Limfangita carcinomatoasă



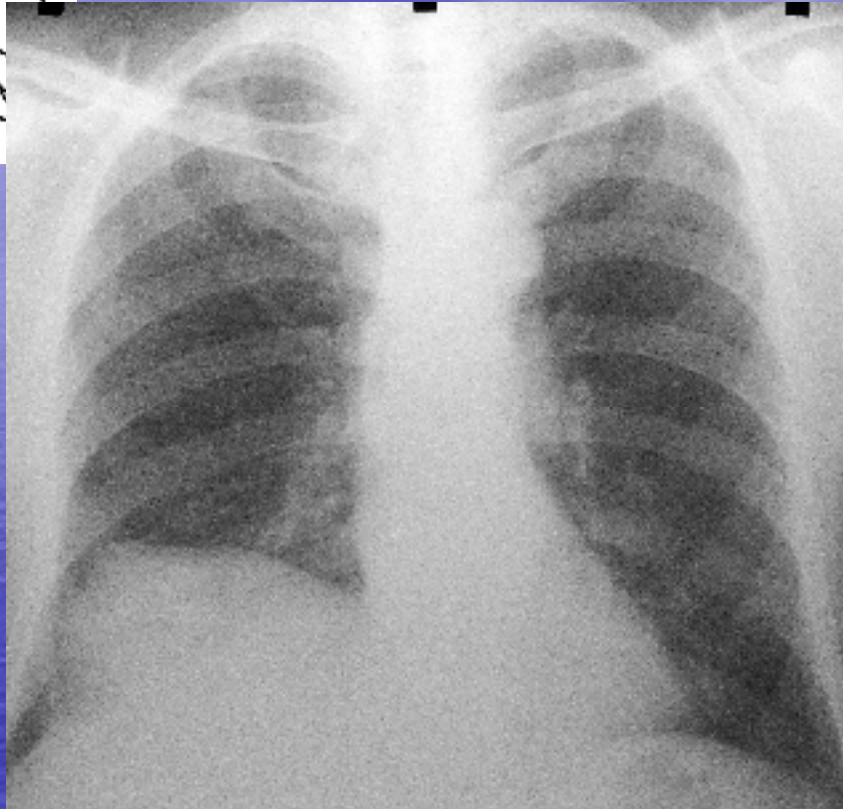
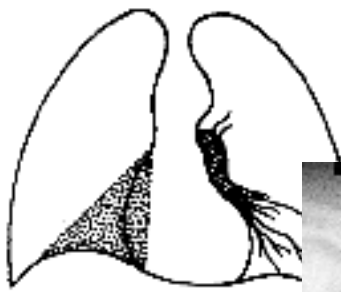
Pleurezia în cantitate medie



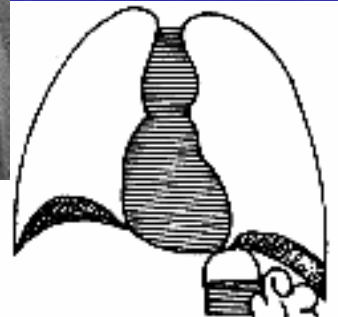
Pleurezia în cască

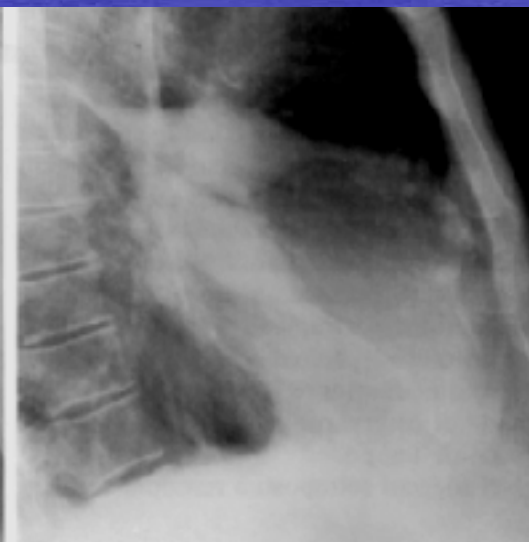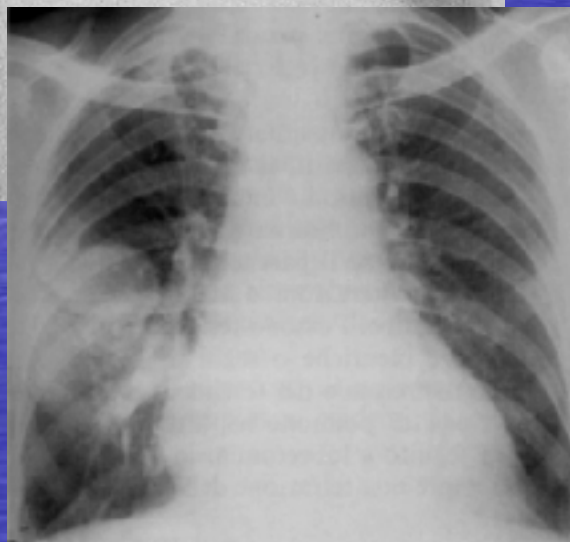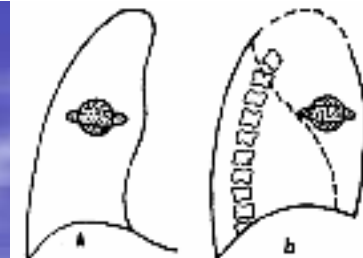


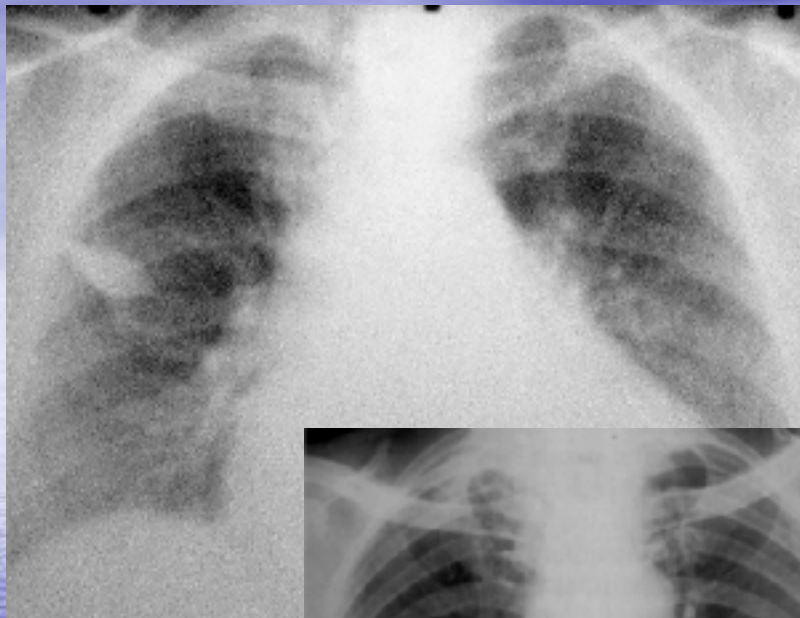Pleurezii închistate

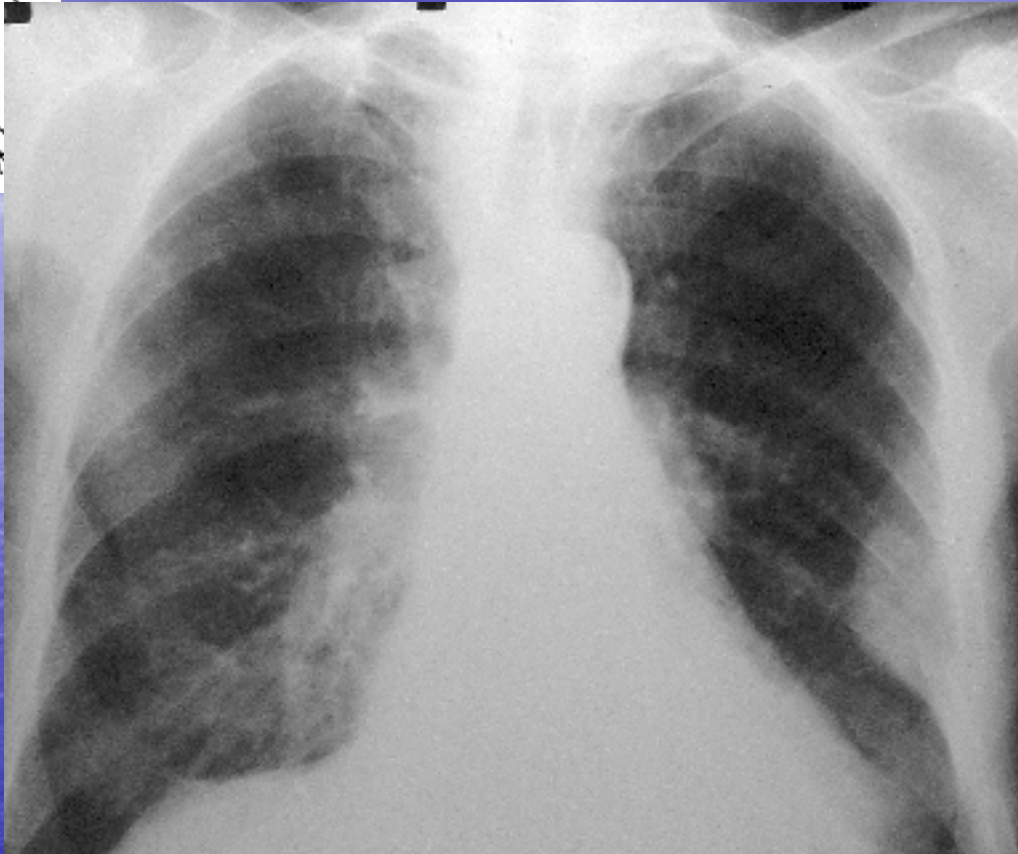
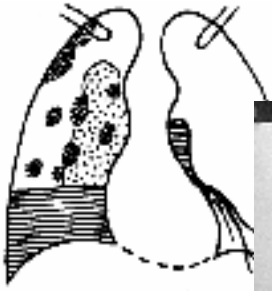


Pleurezie închistată diafragmatic

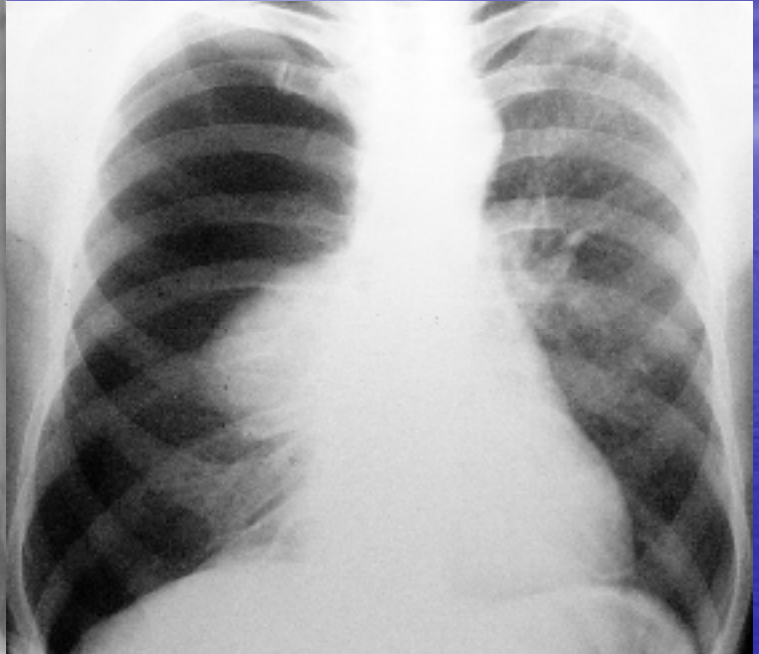
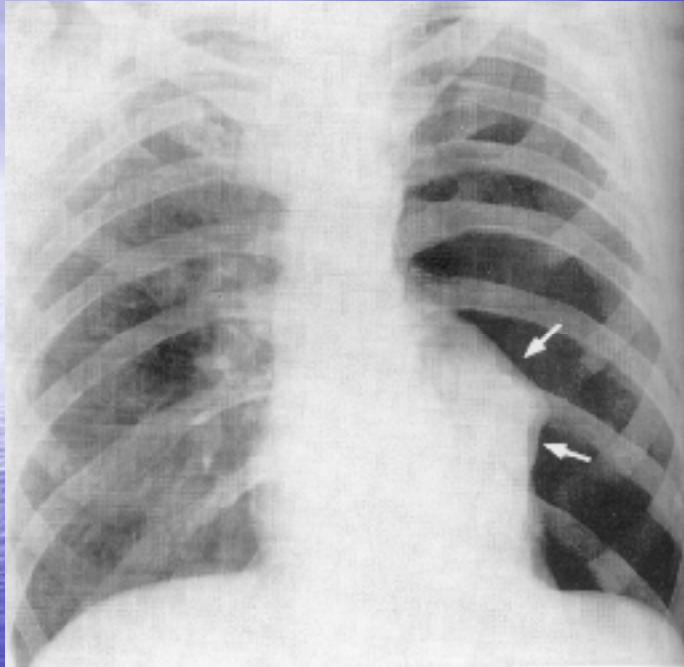




Pleurezie închistată

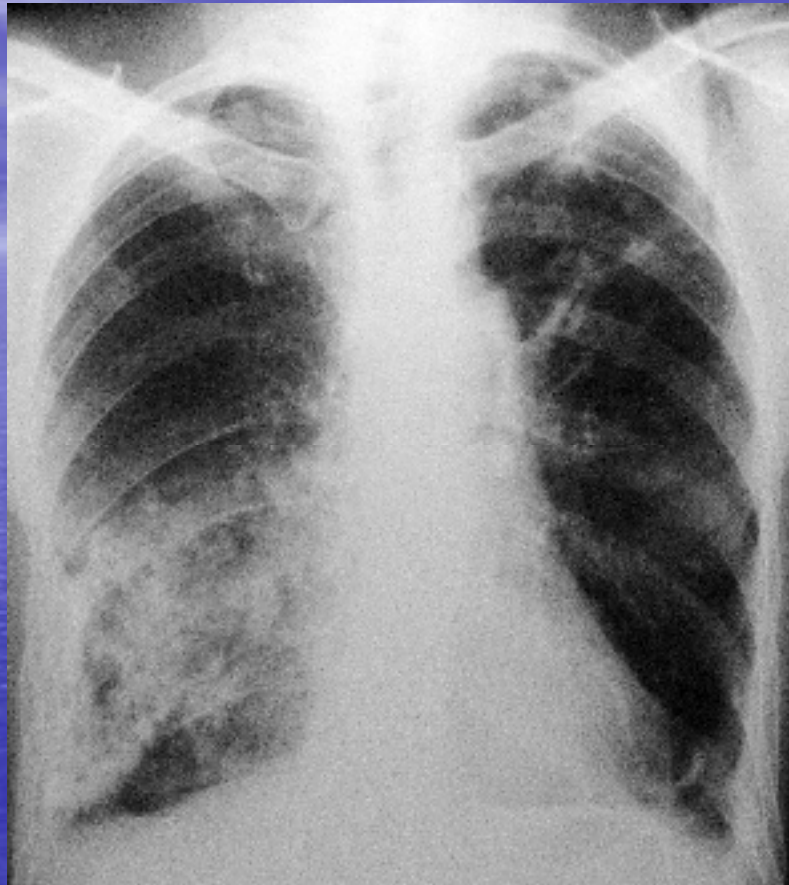
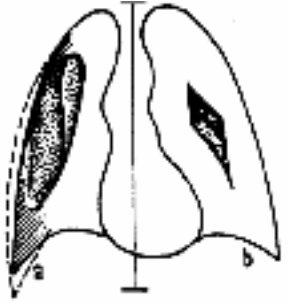


Mezoteliomul pleural

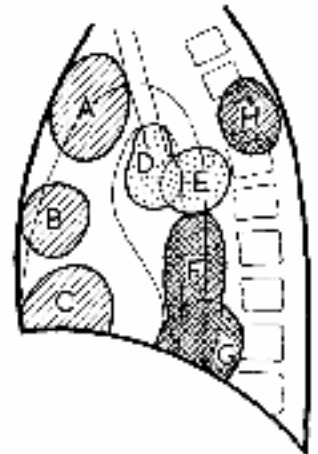
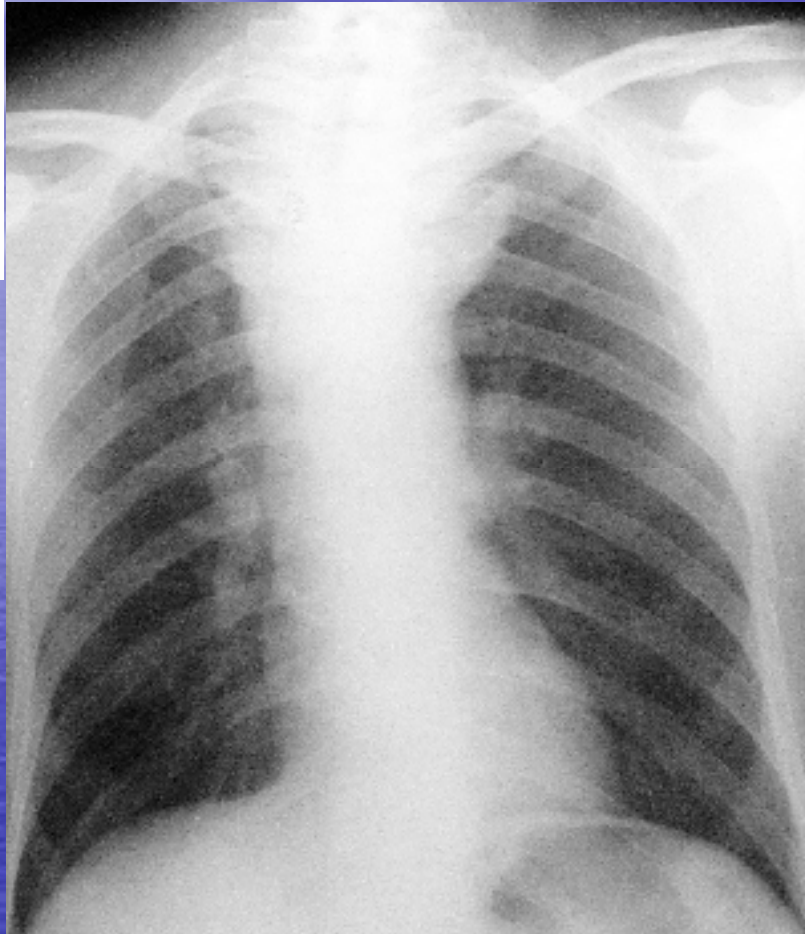
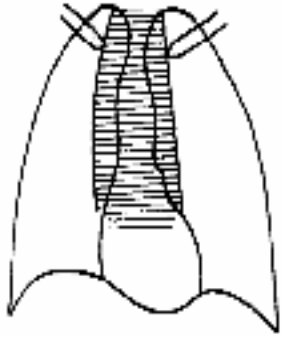


Pneumotorax stâng, respectiv drept cu plămân colabat în hil

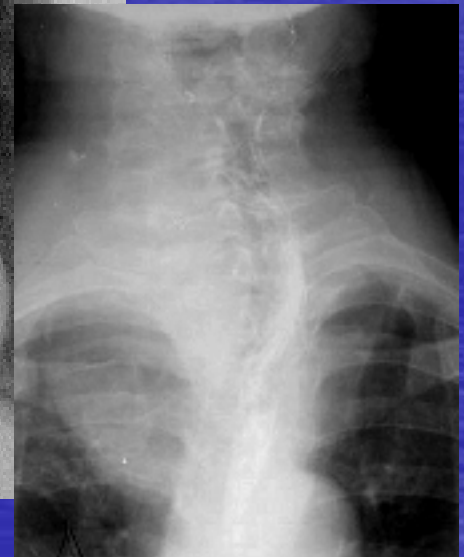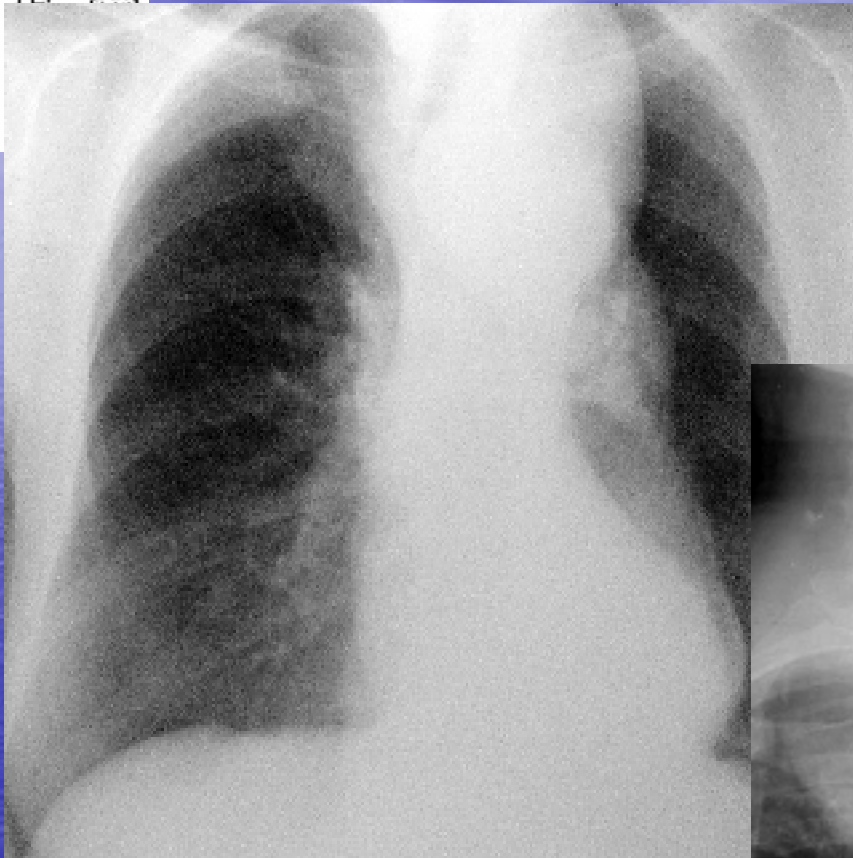
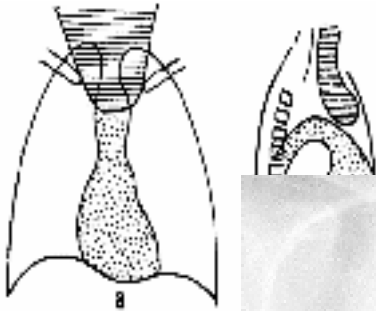




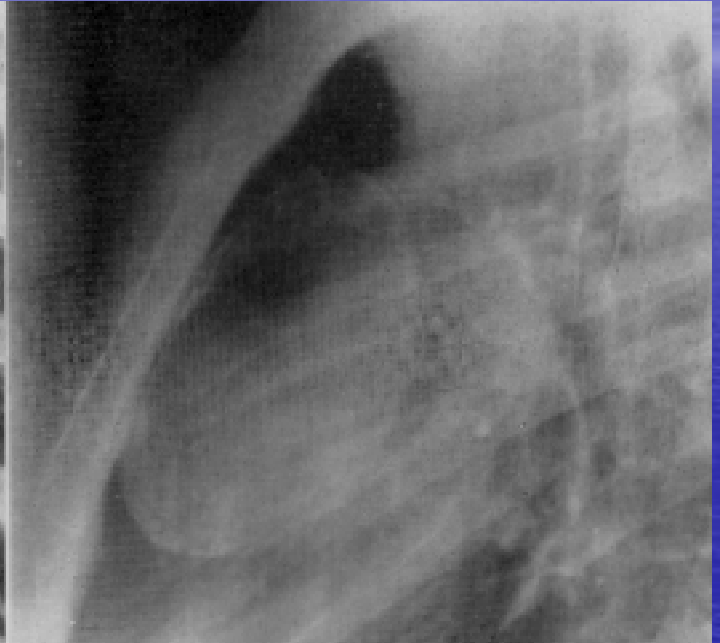
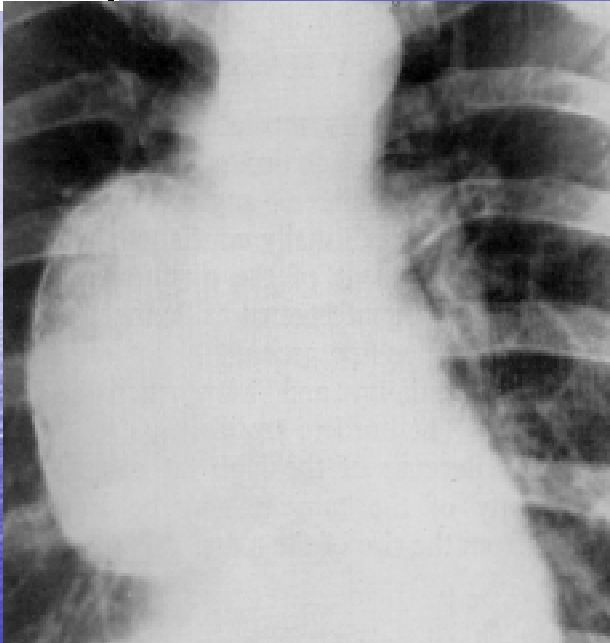
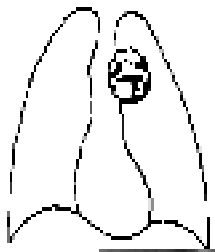
Calcificări pleurale bazale dreapta



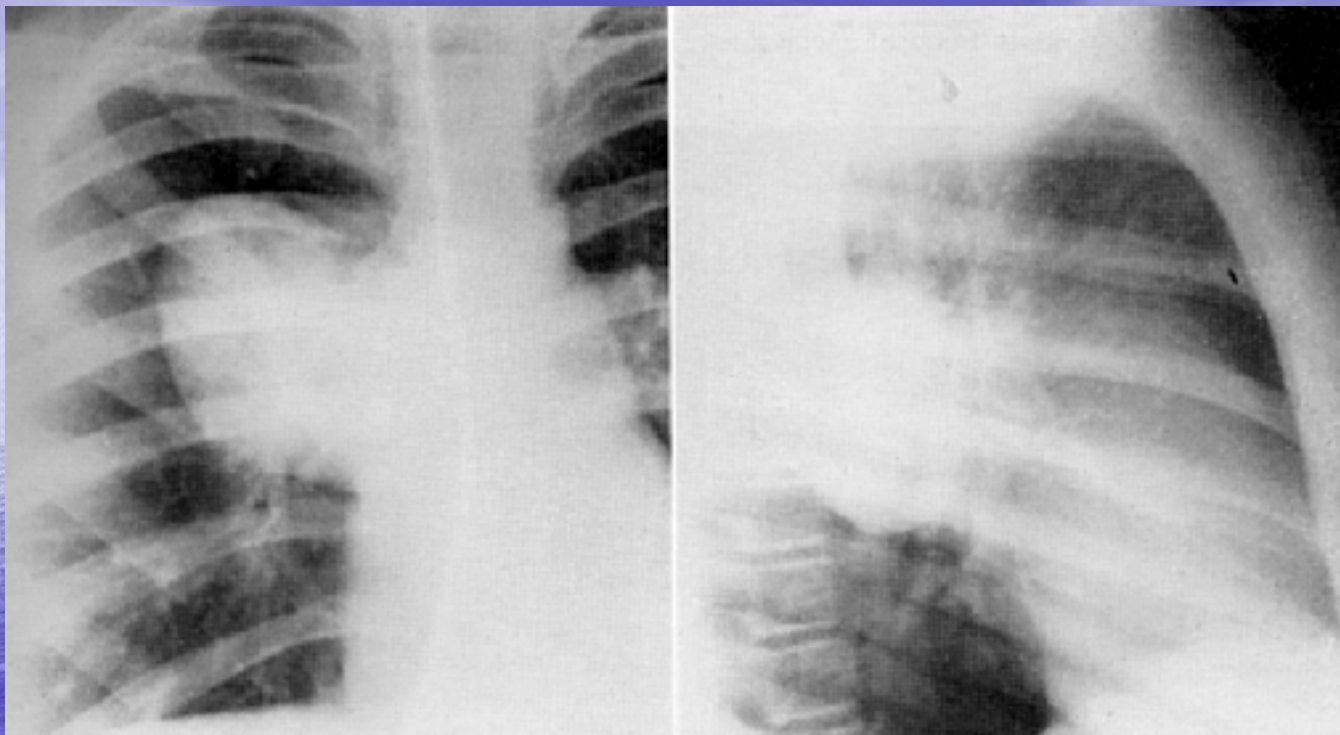
Hipertrofia de timus



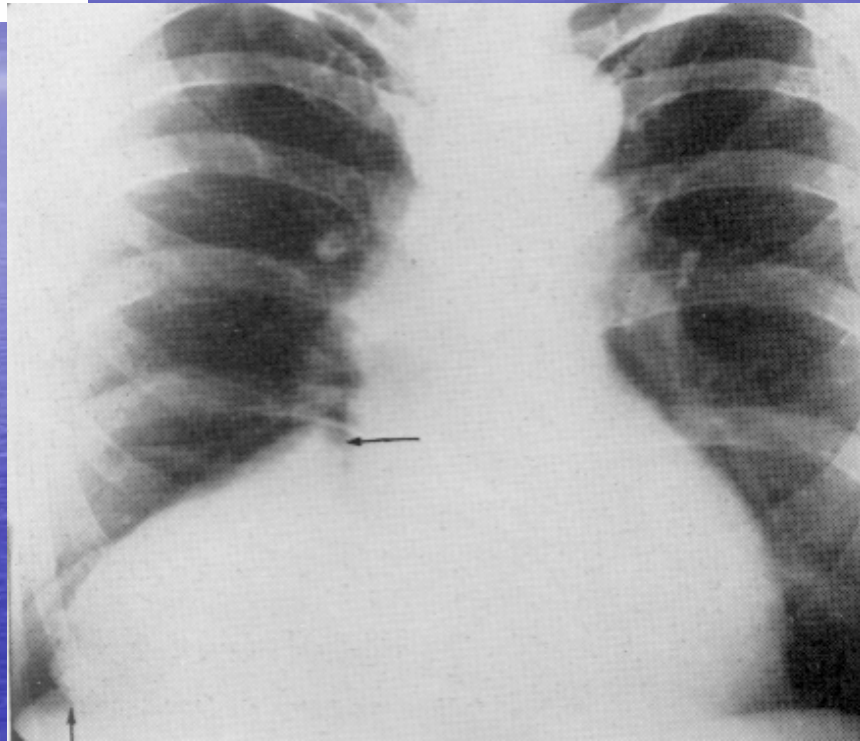
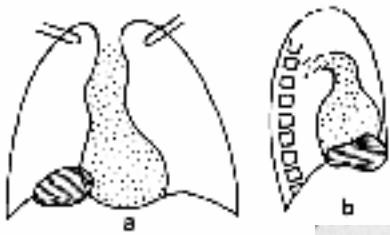
Hipertrofia tiroidiană



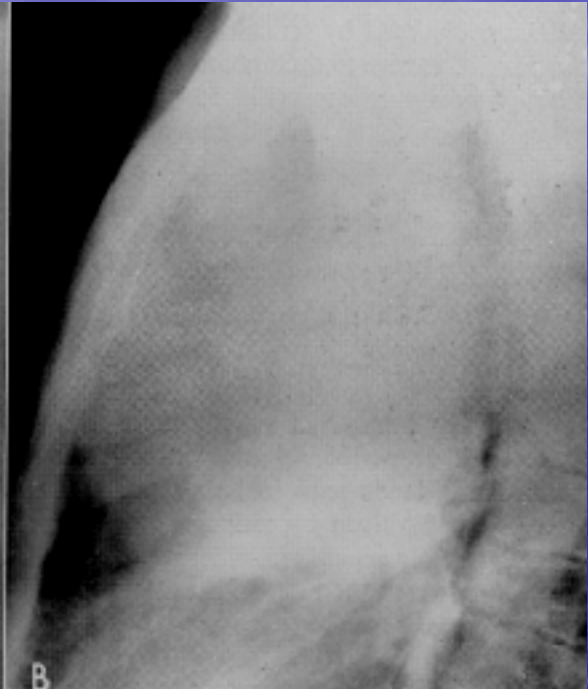
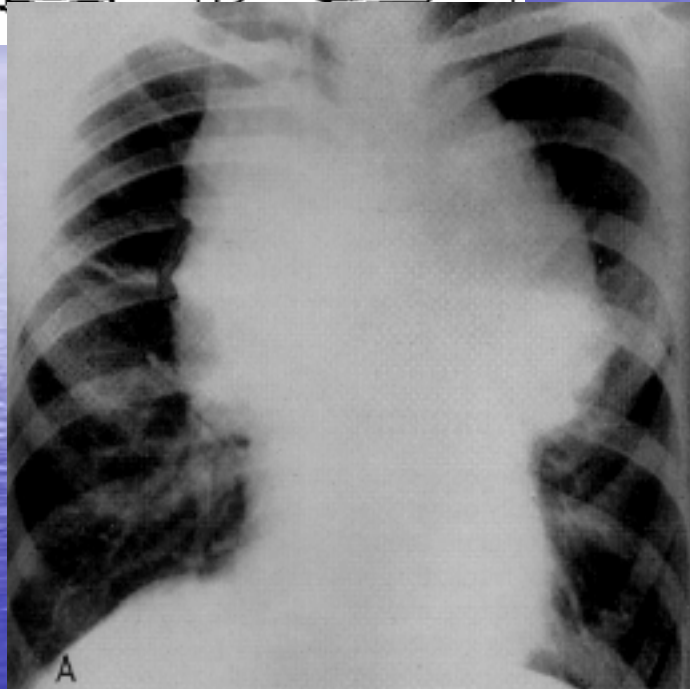
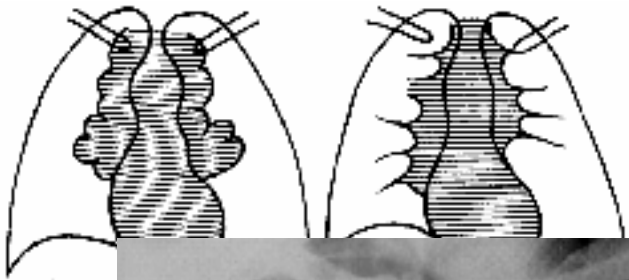Chist dermoid



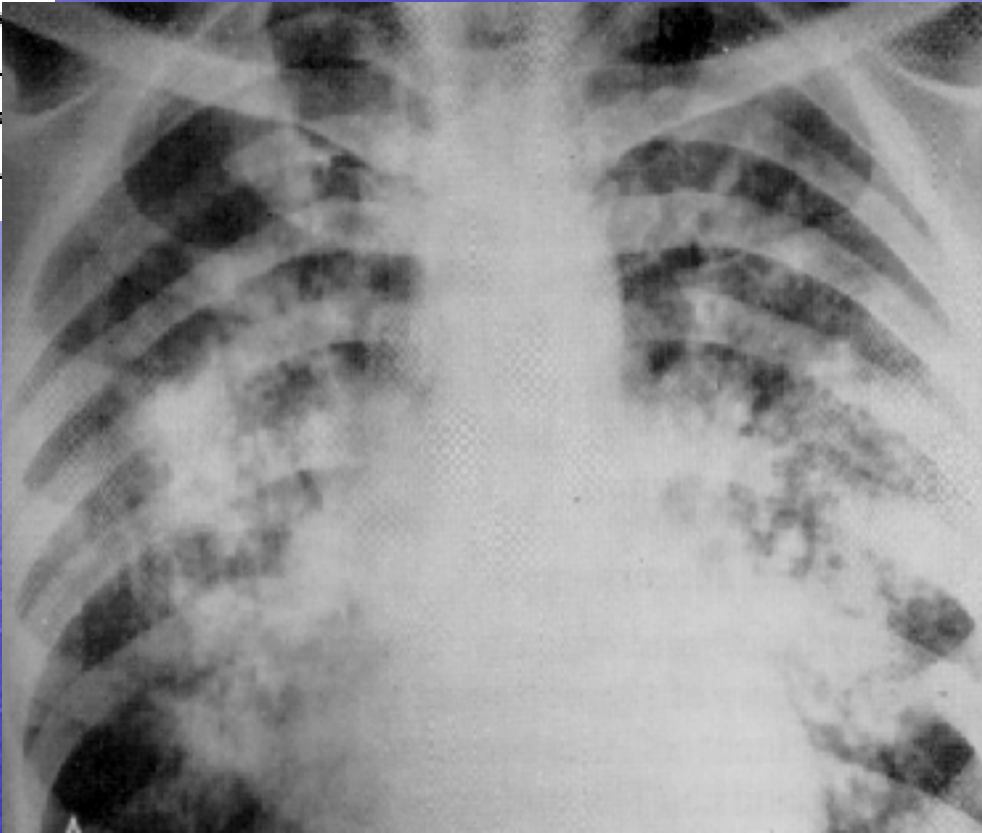
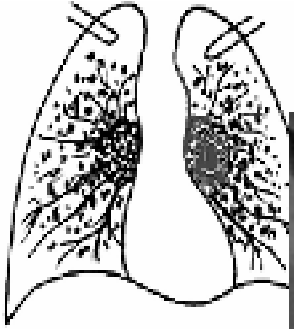
Chistul bronhogen



Chistul pleuro-pericardic

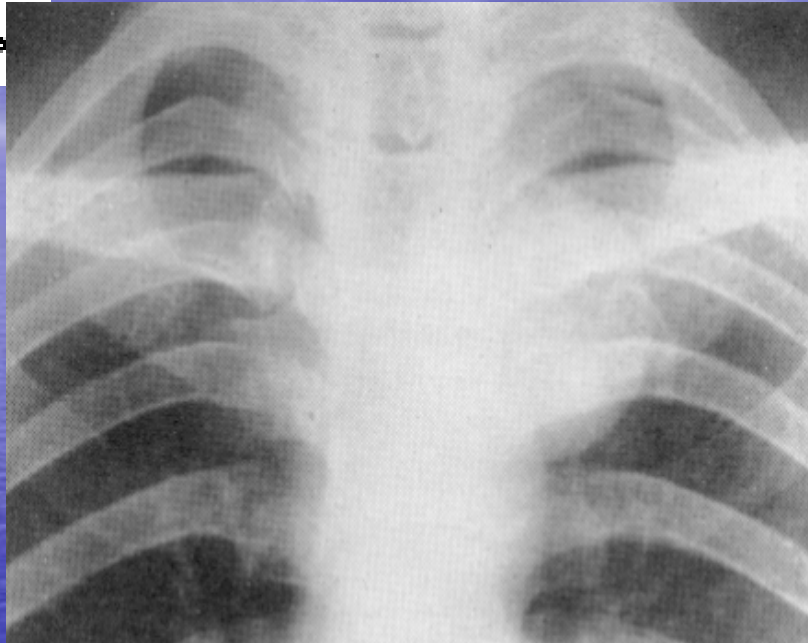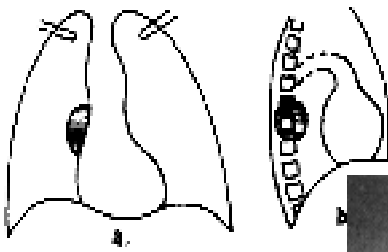


Limfogranelomatoză malignă



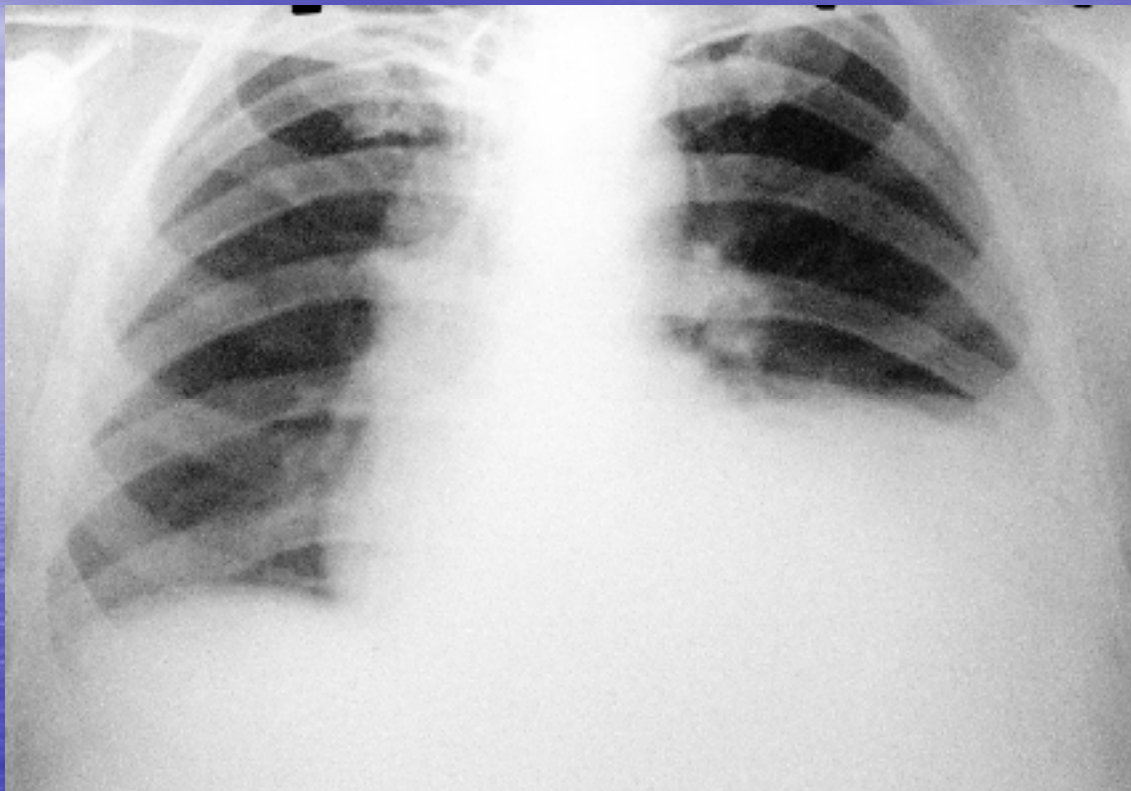Modificări în sarcoidoză



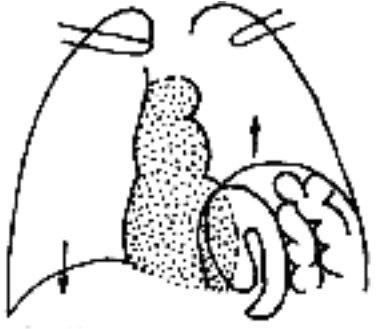


Neurinom

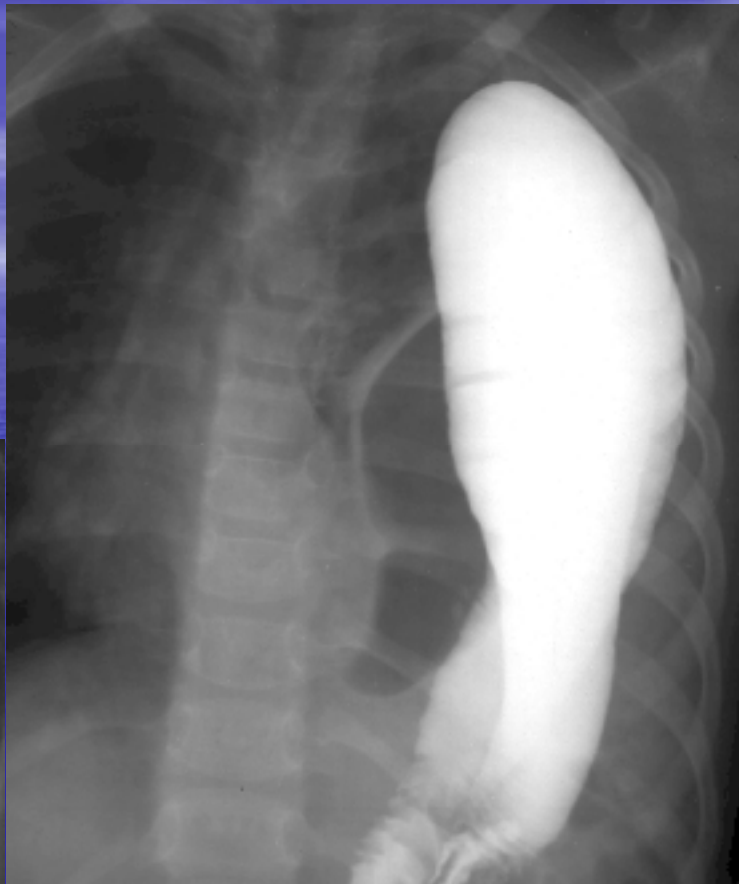




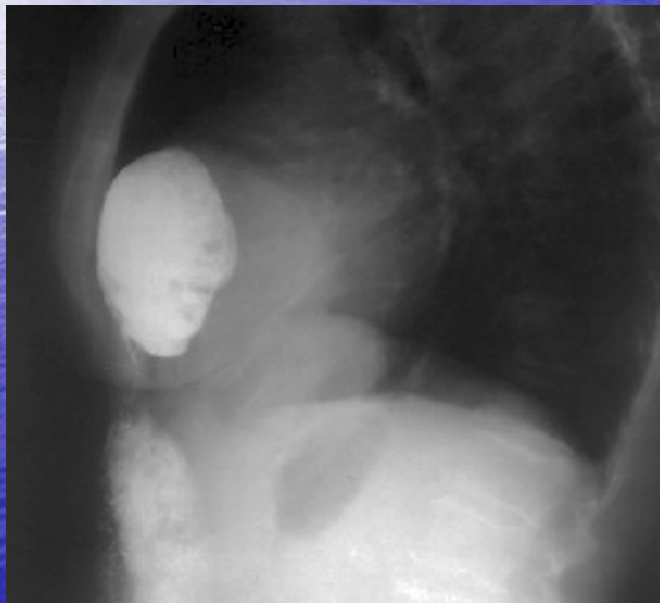Paralizia diafragmatică

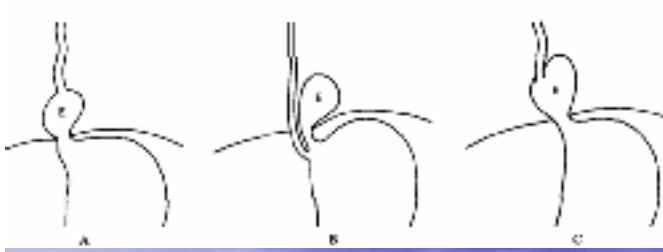


Eventrația diafragmatică

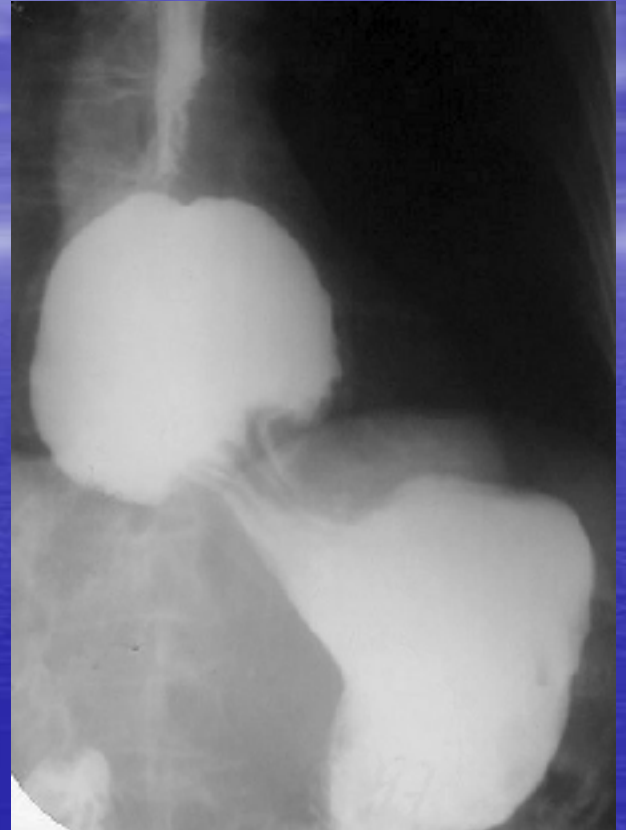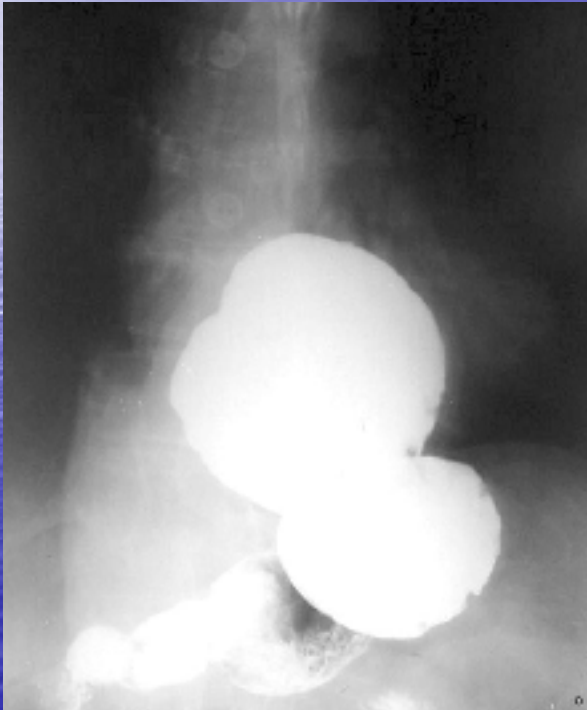


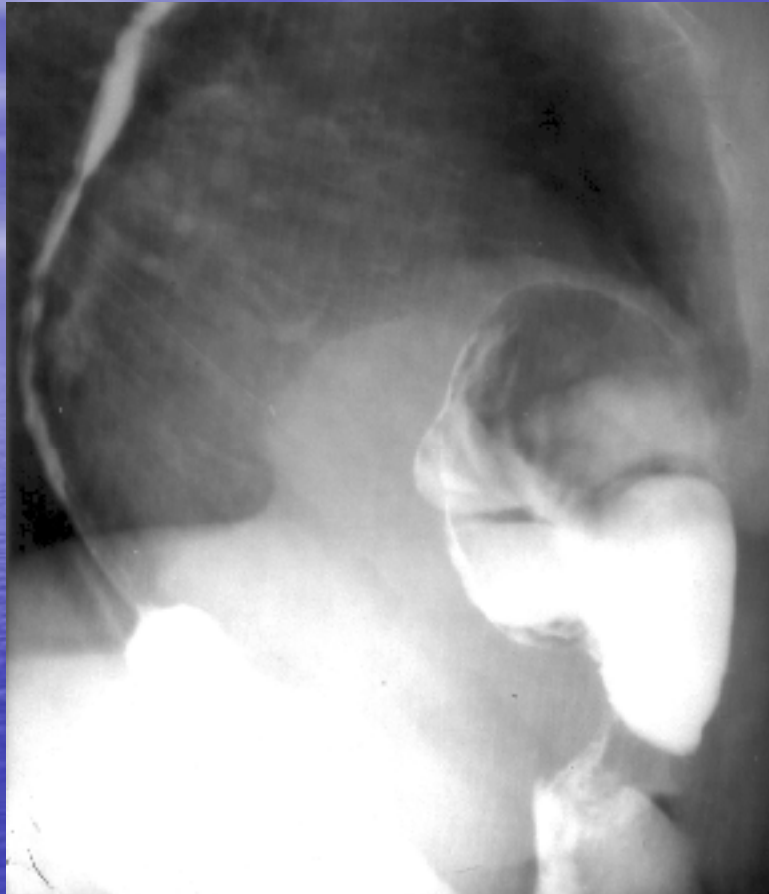Hernia diafragmatică





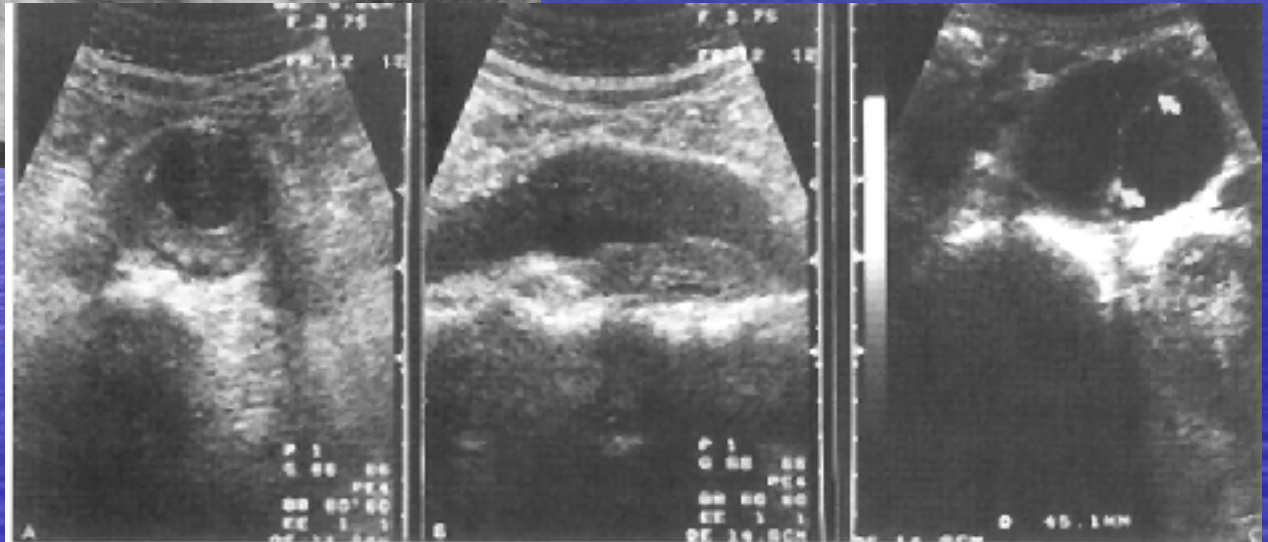
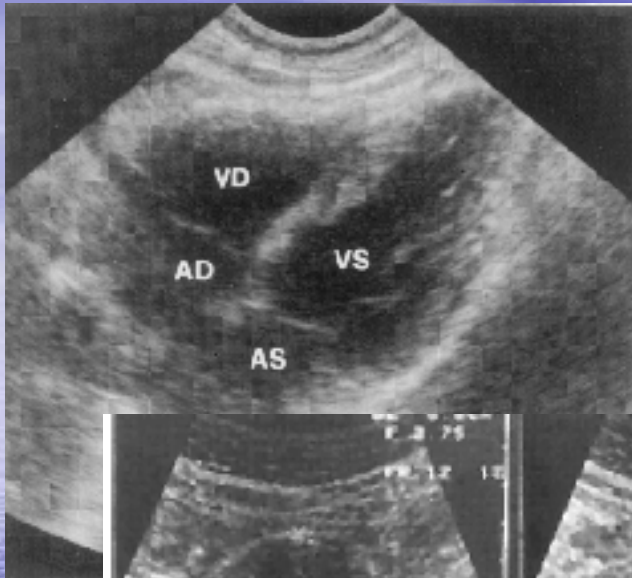
Hernia diafragmatică cu esofag scurt(A),  
paraesofagiană(B), prin alunecare(C)

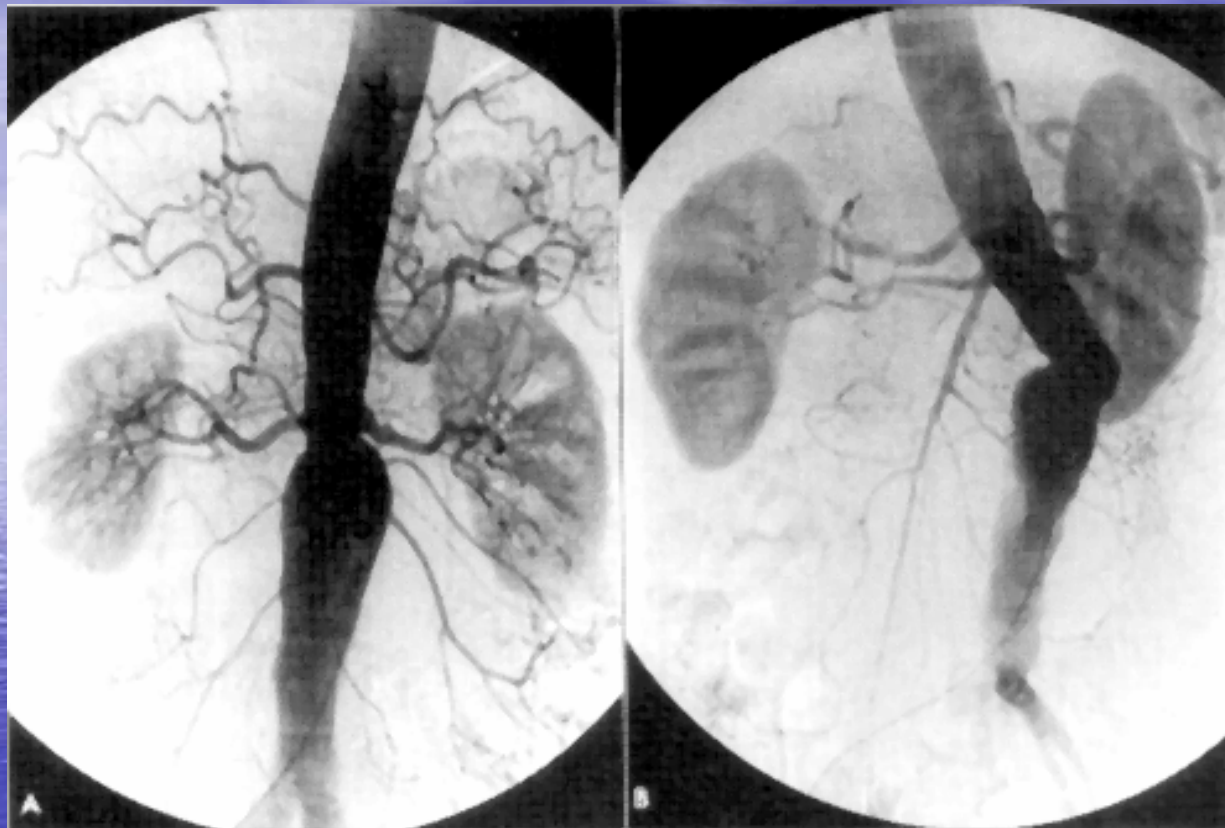




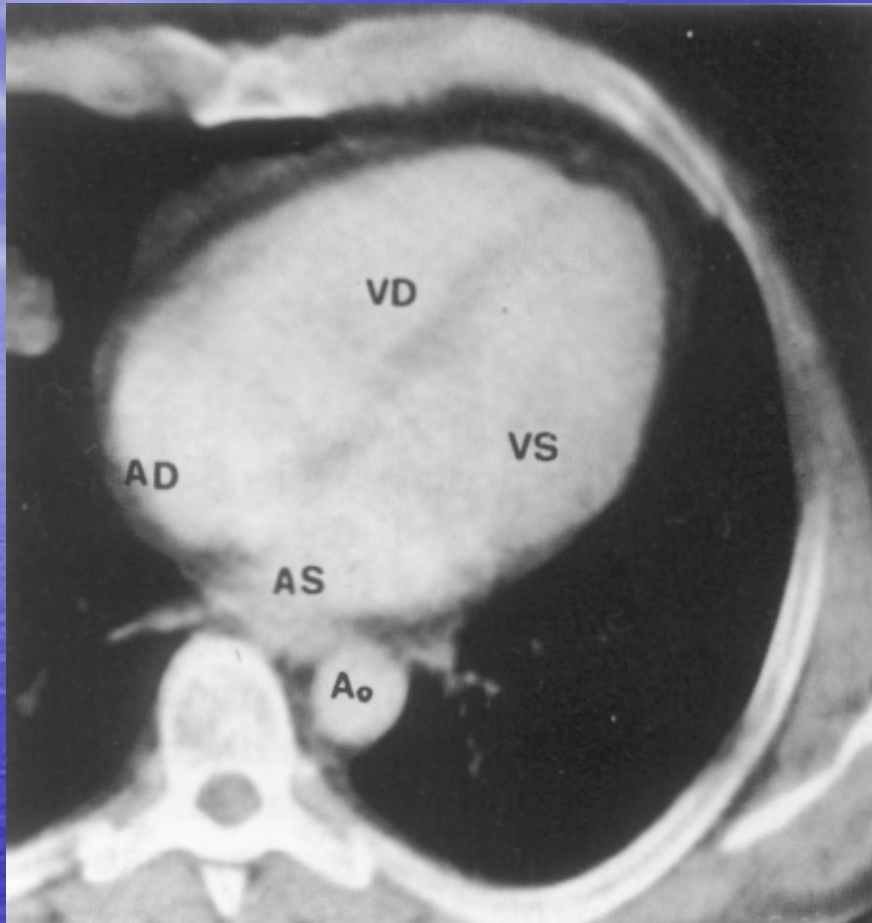
Hernia prin fanta Larey

## Ultrasonografia cardiacă și vasculară



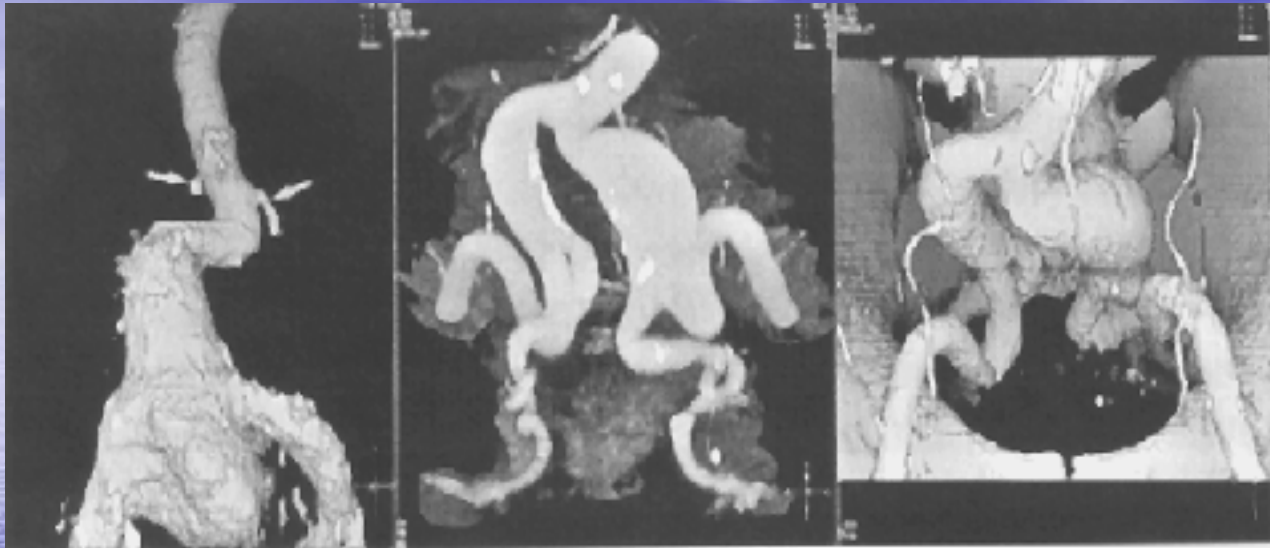


Aortografie -anevrism aortă sub emergența arterelor renale

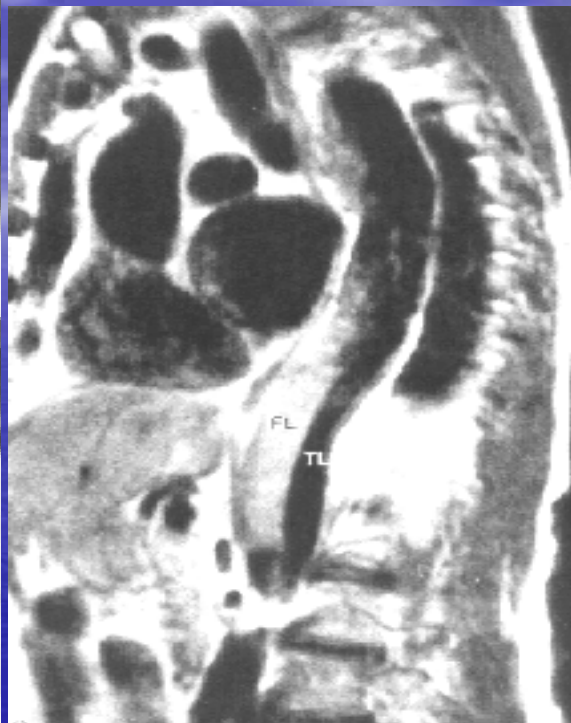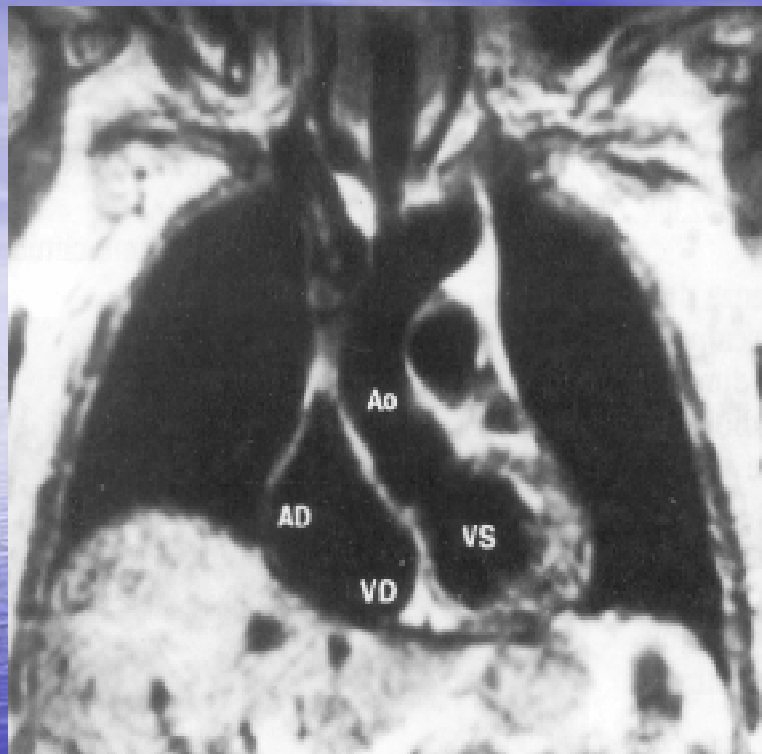


Angiografía CT

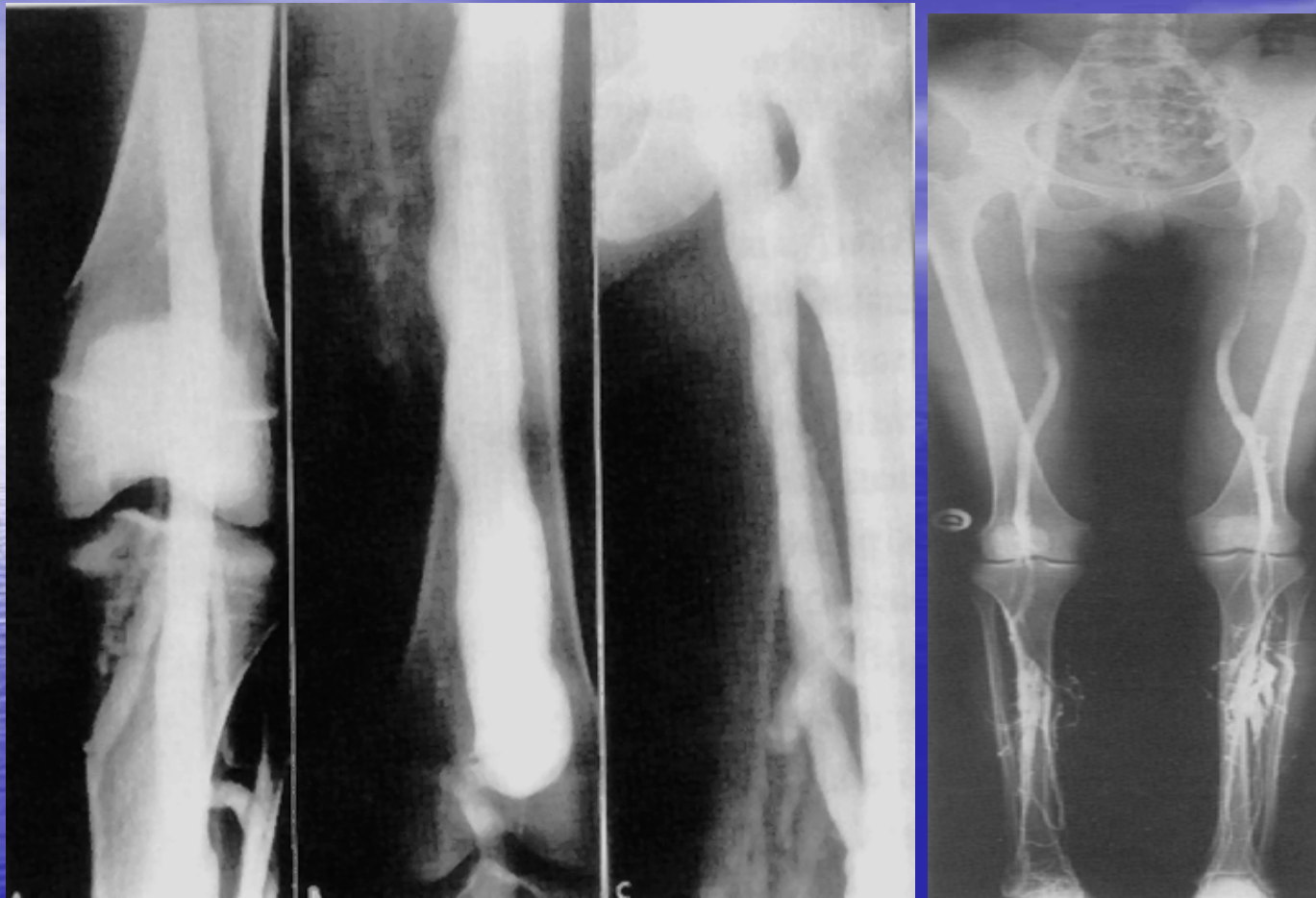




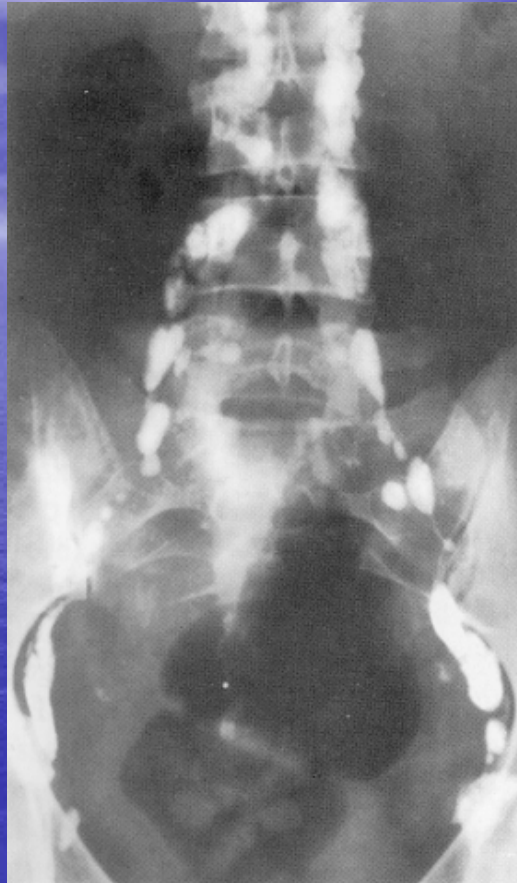
Tehnici de reconstrucție angiografică CT-volume rendering, MIP



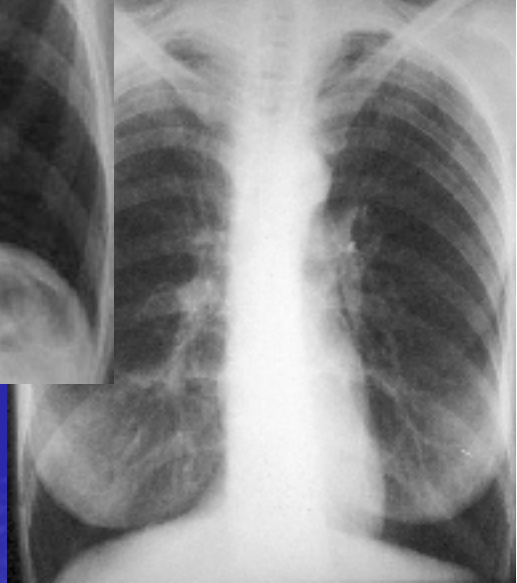
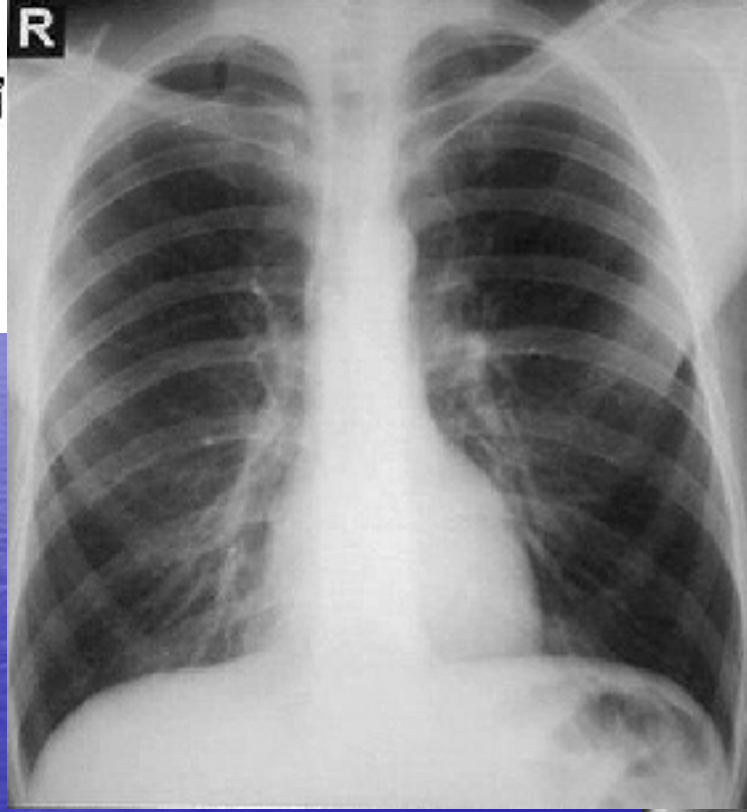
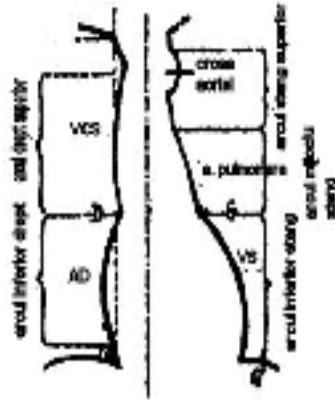
Examinare cardiacă prin IRM

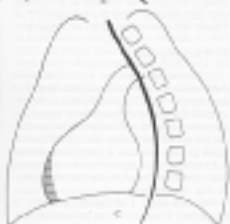
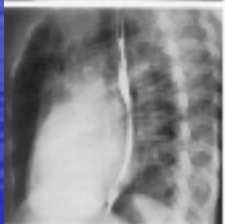
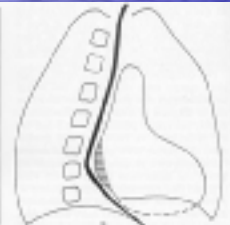
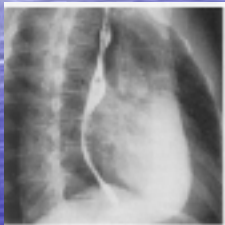
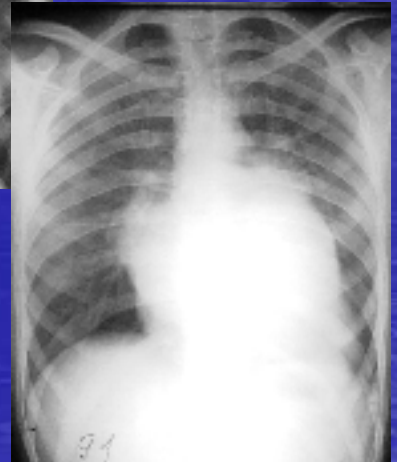
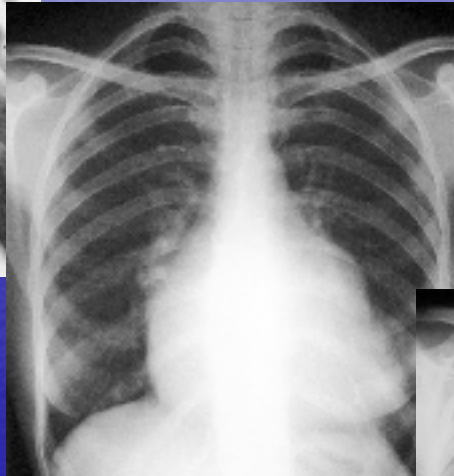
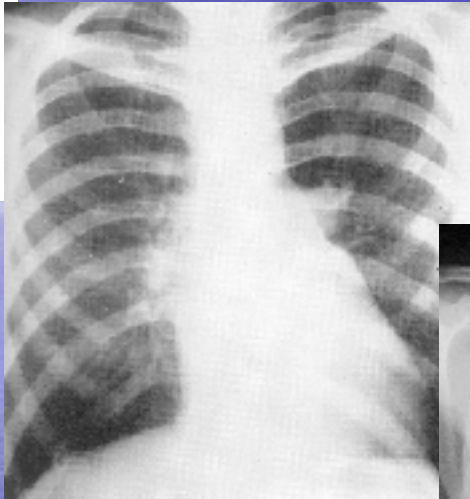
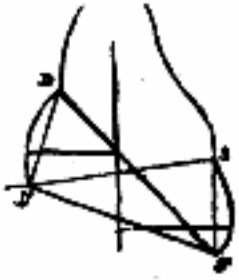


Flebografii periferice

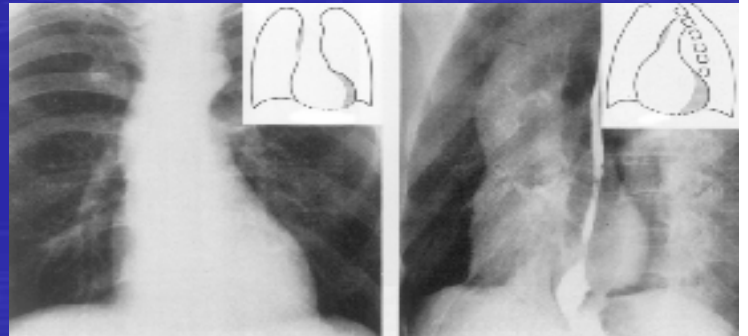
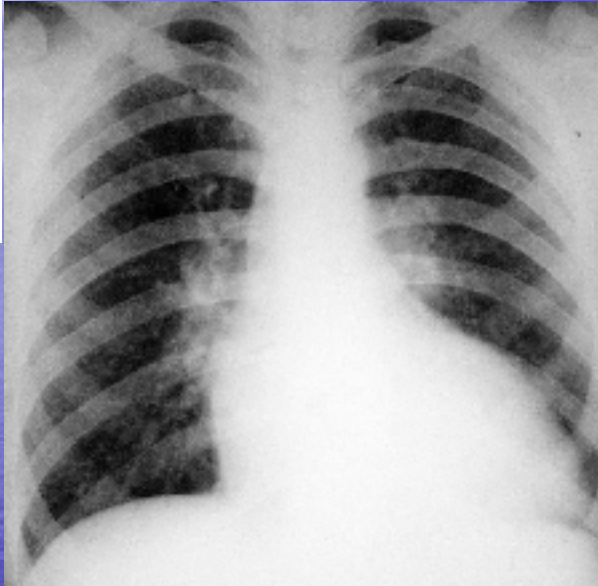
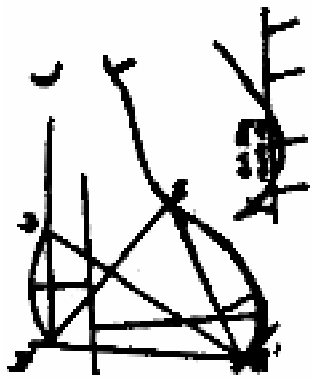


Limfografie

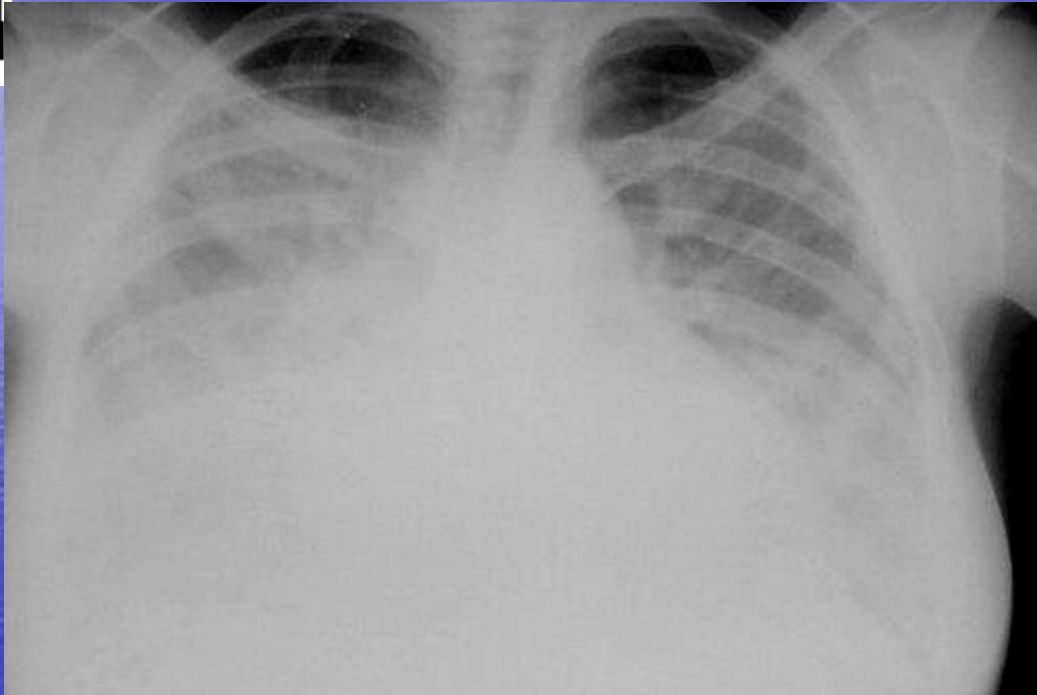
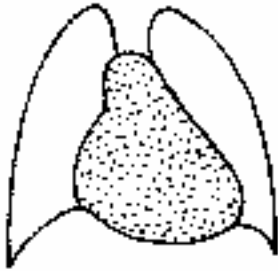




Configurații mitrale

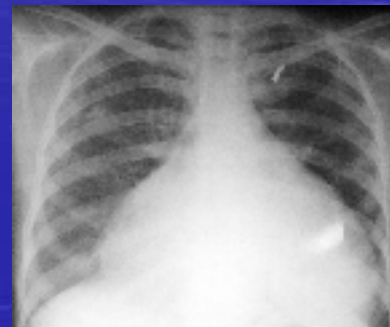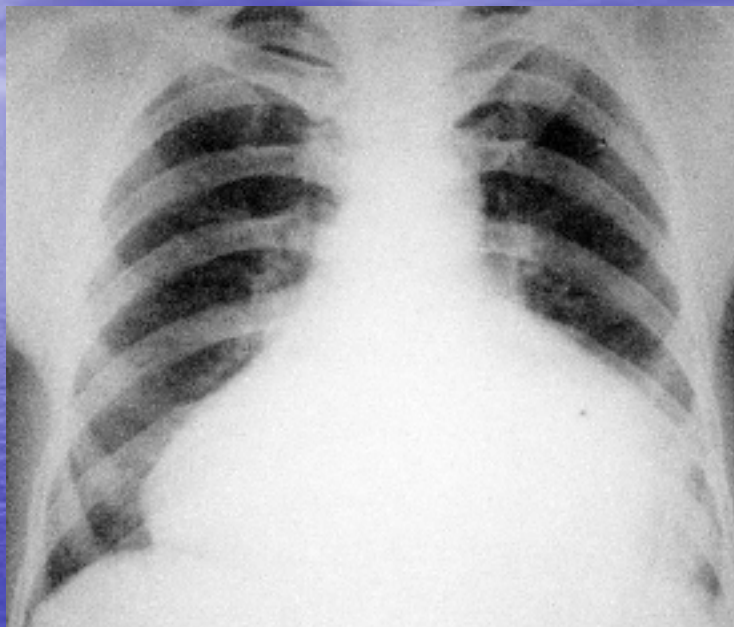
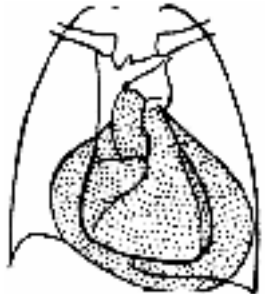


Cord configurat aortic

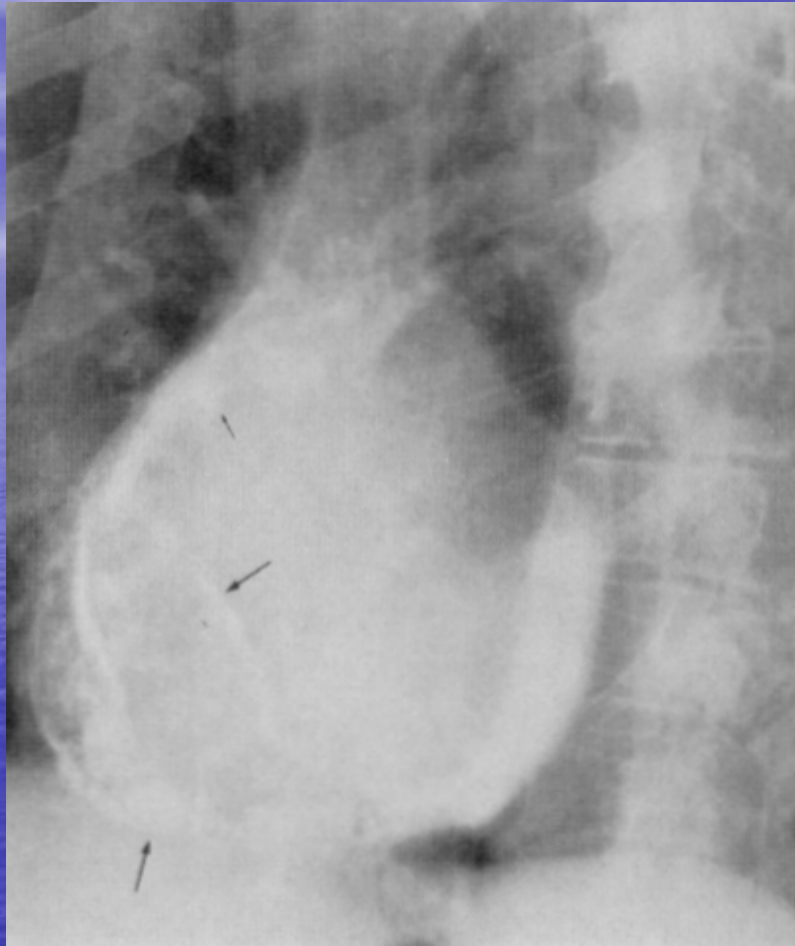
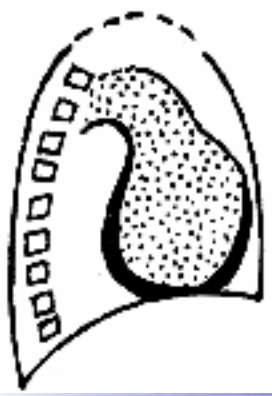


Cord moicarditic

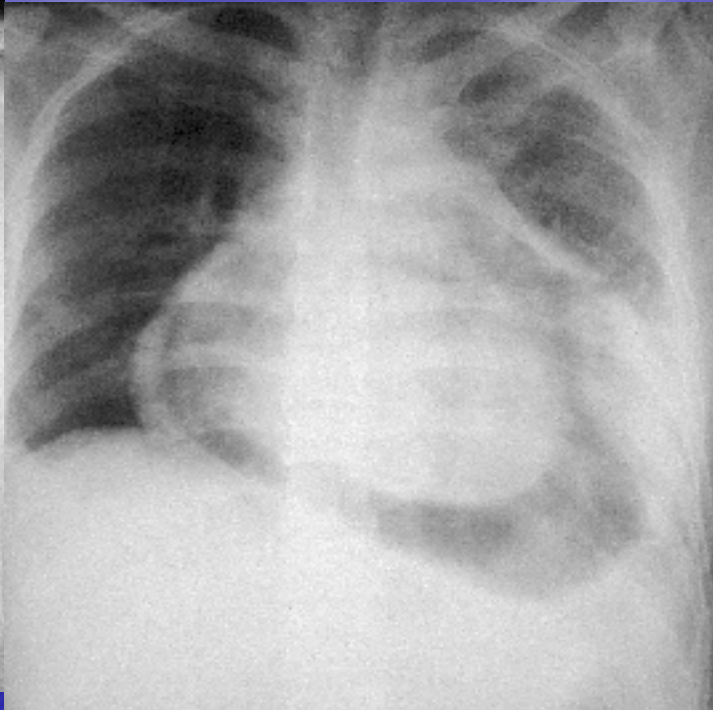
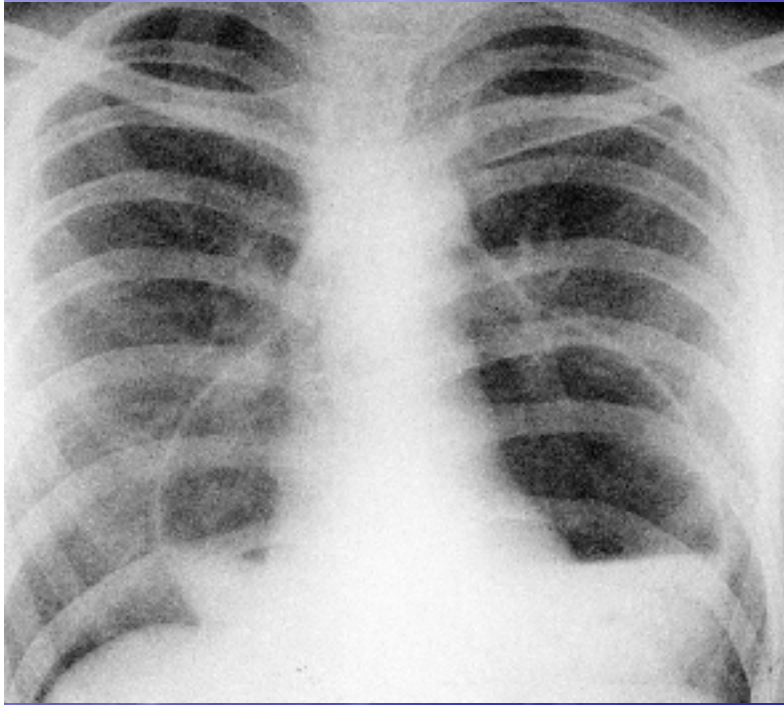




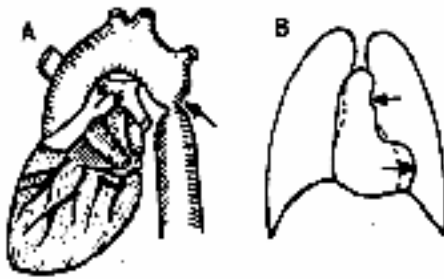
Configurația pericarditică



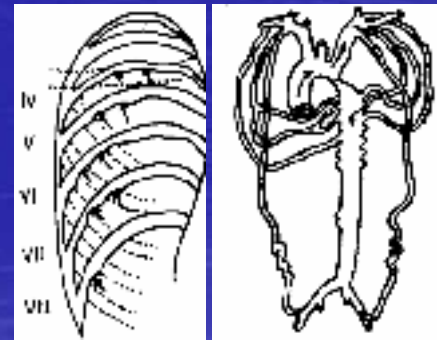
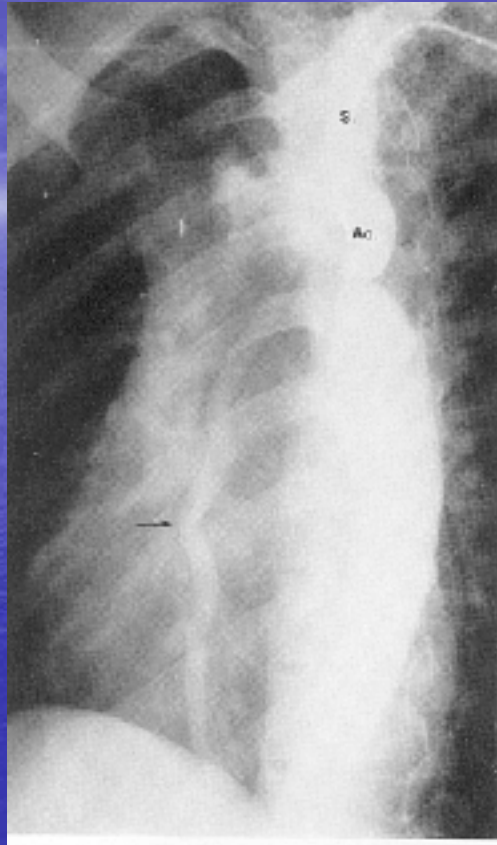
Calcificări pericarditice

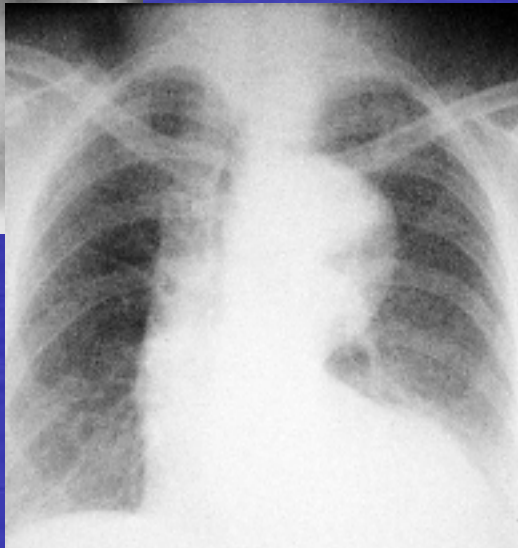
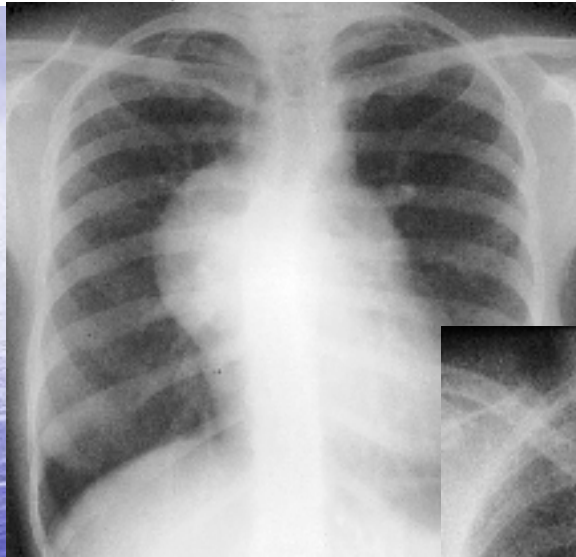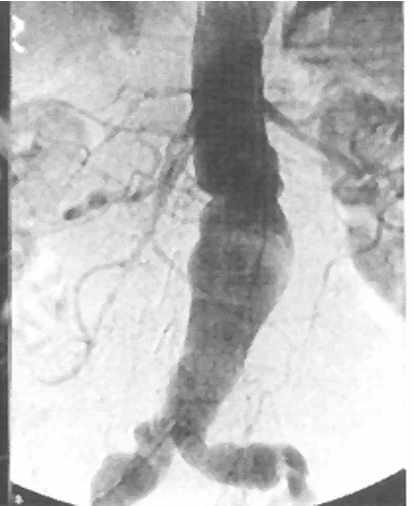
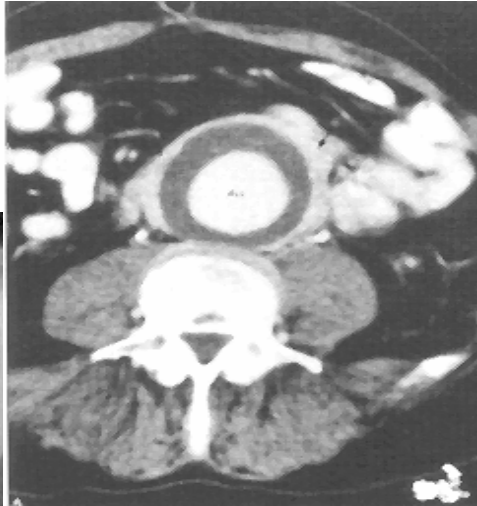

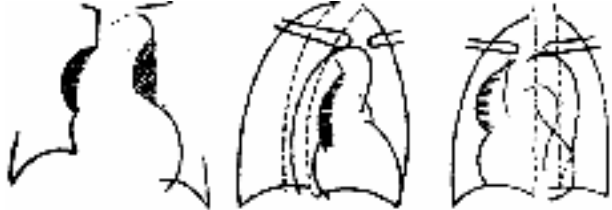
Hidropneumopericard

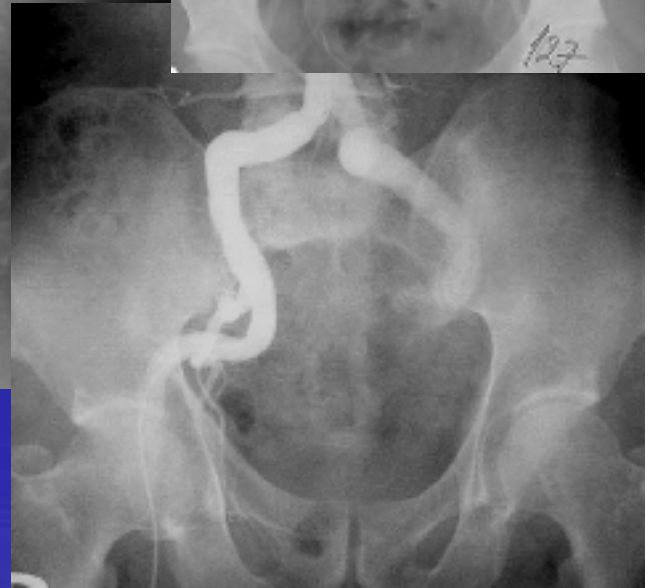
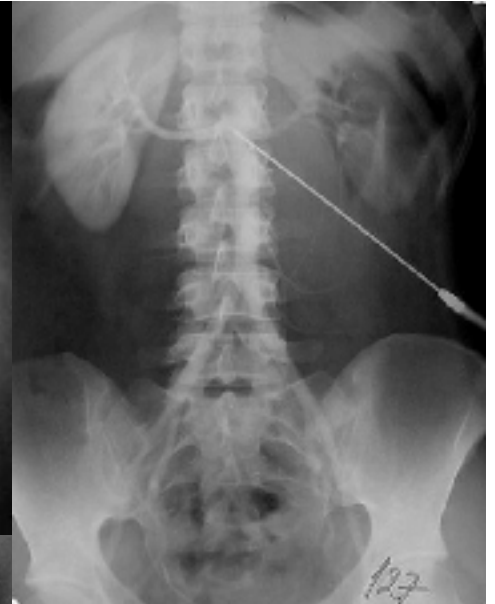
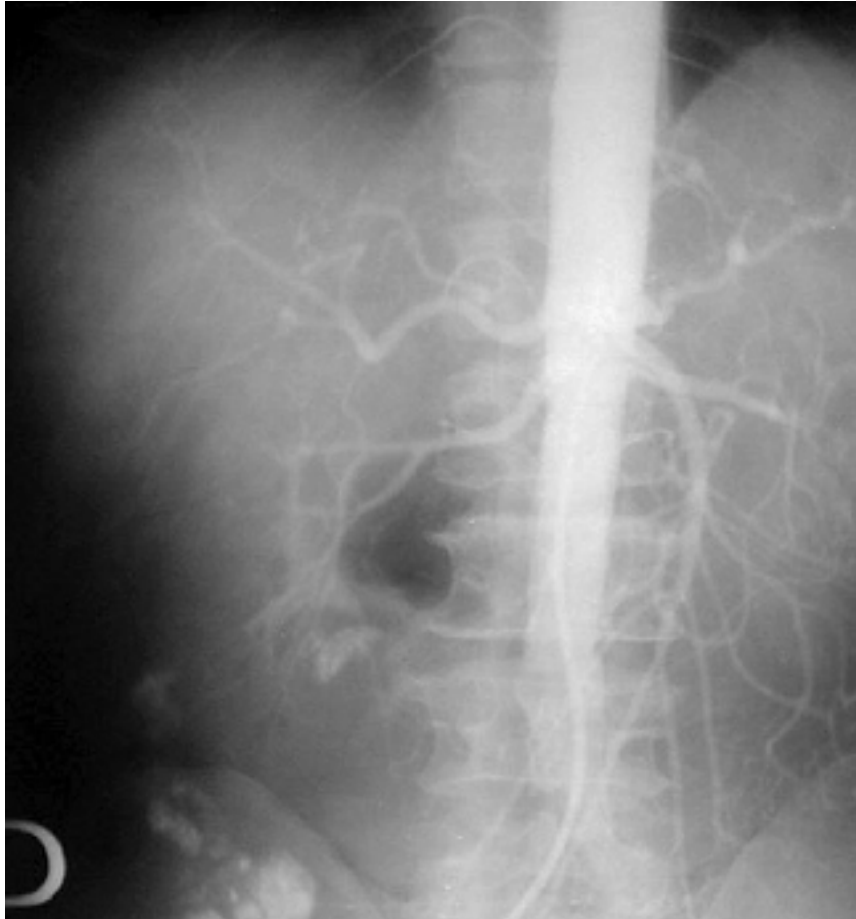Coarctăția de aortă

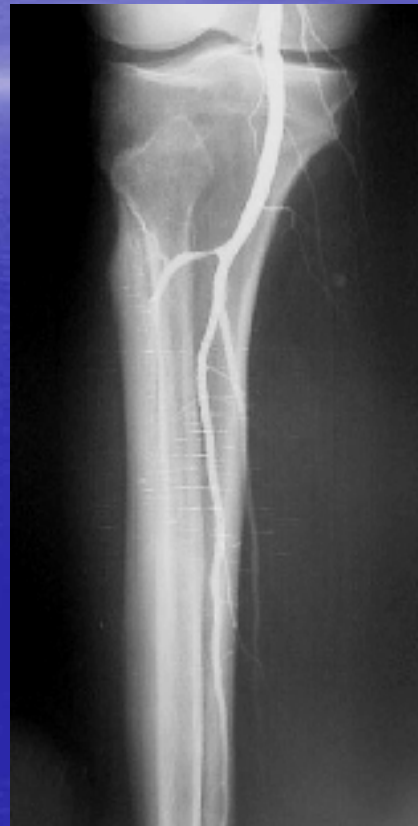
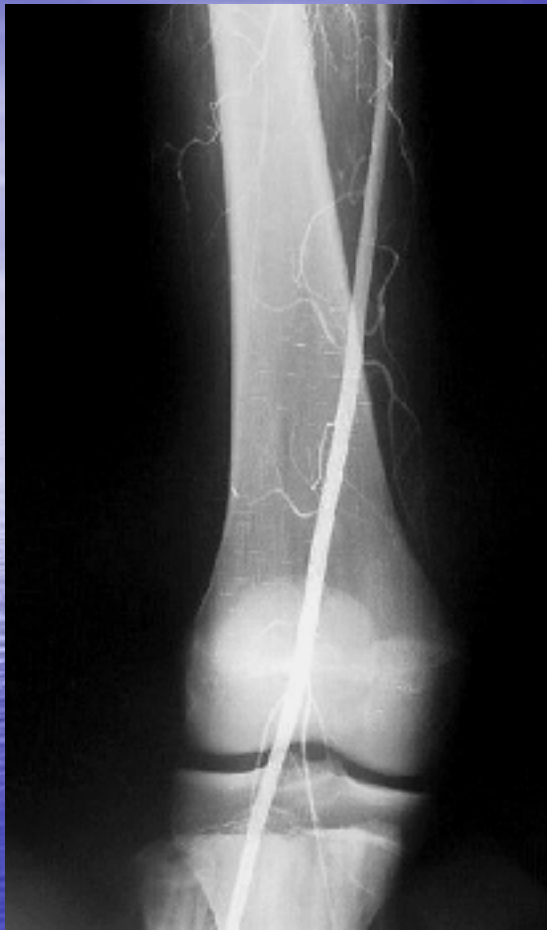
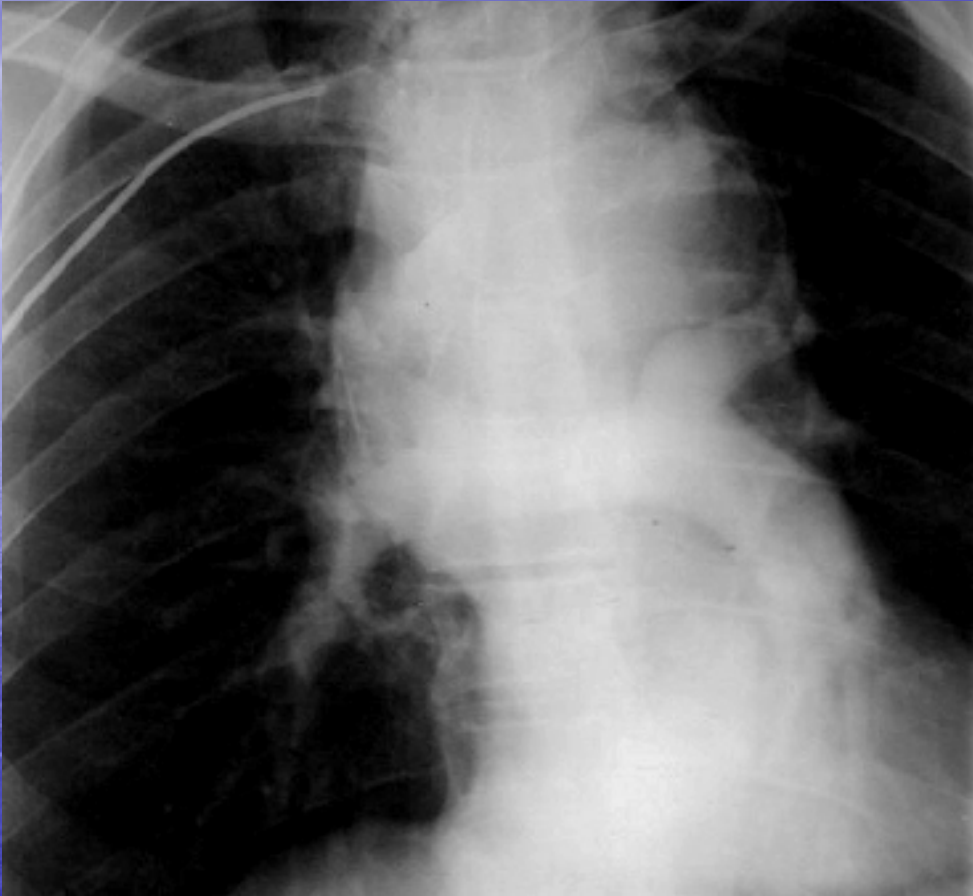


Aneurisme aortă



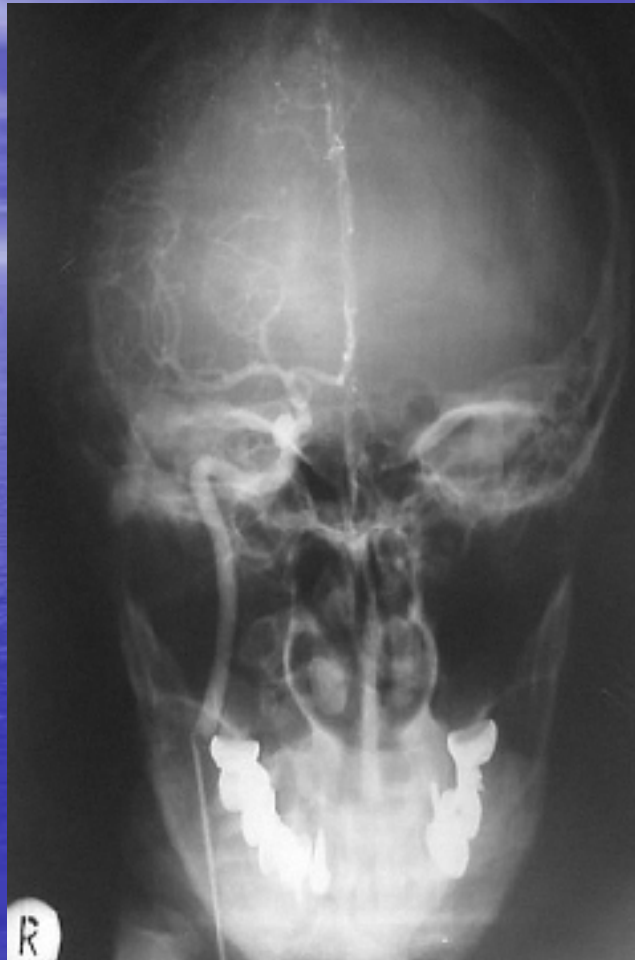Aortografie abdominala



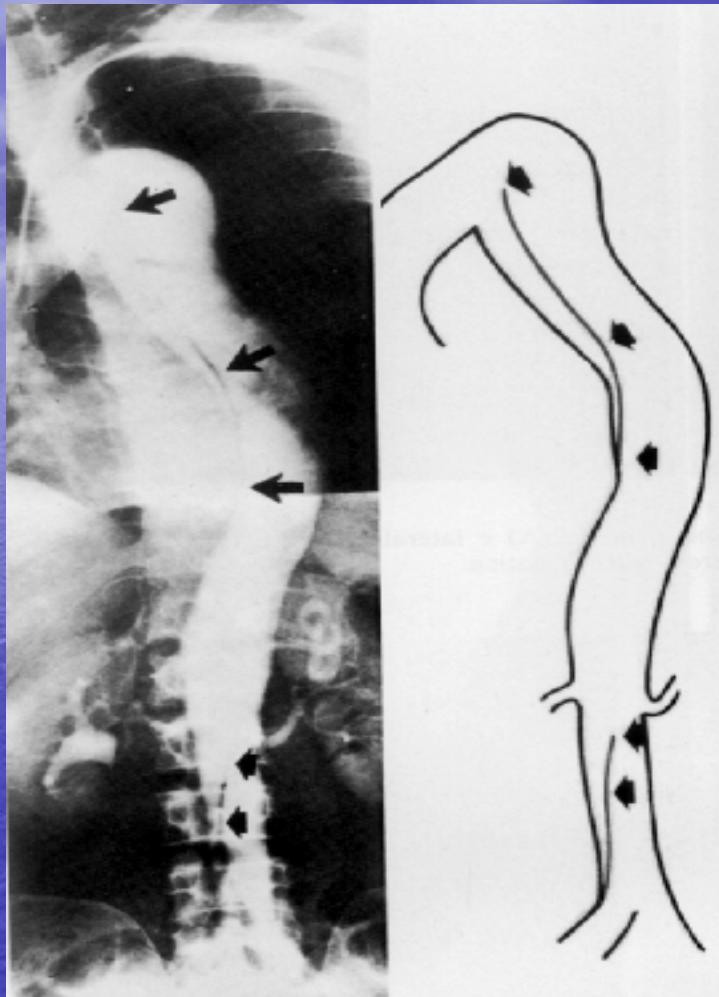


Arteriografie pulmonara

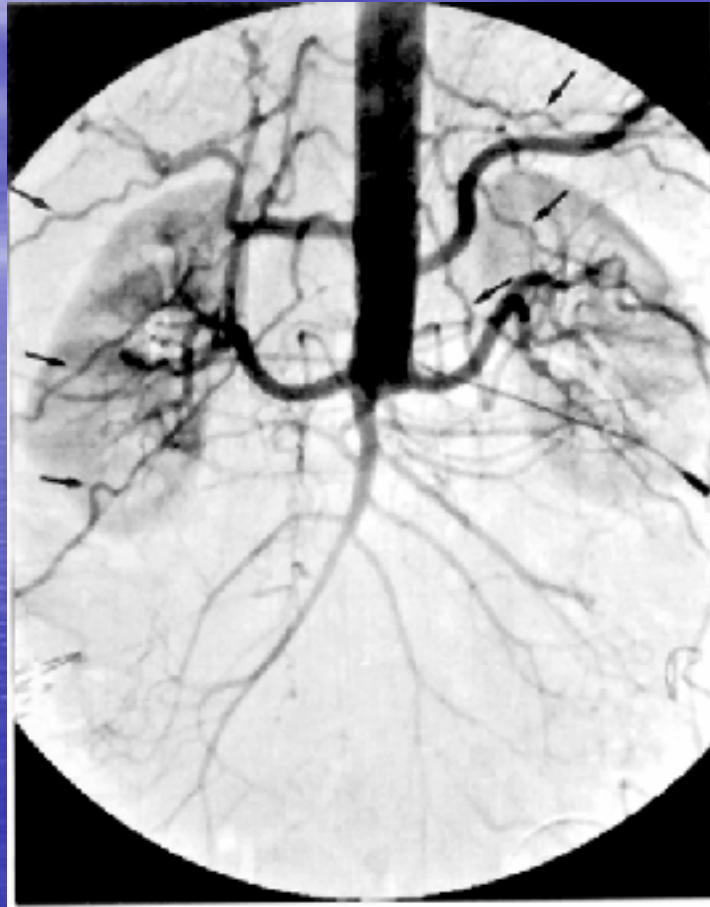



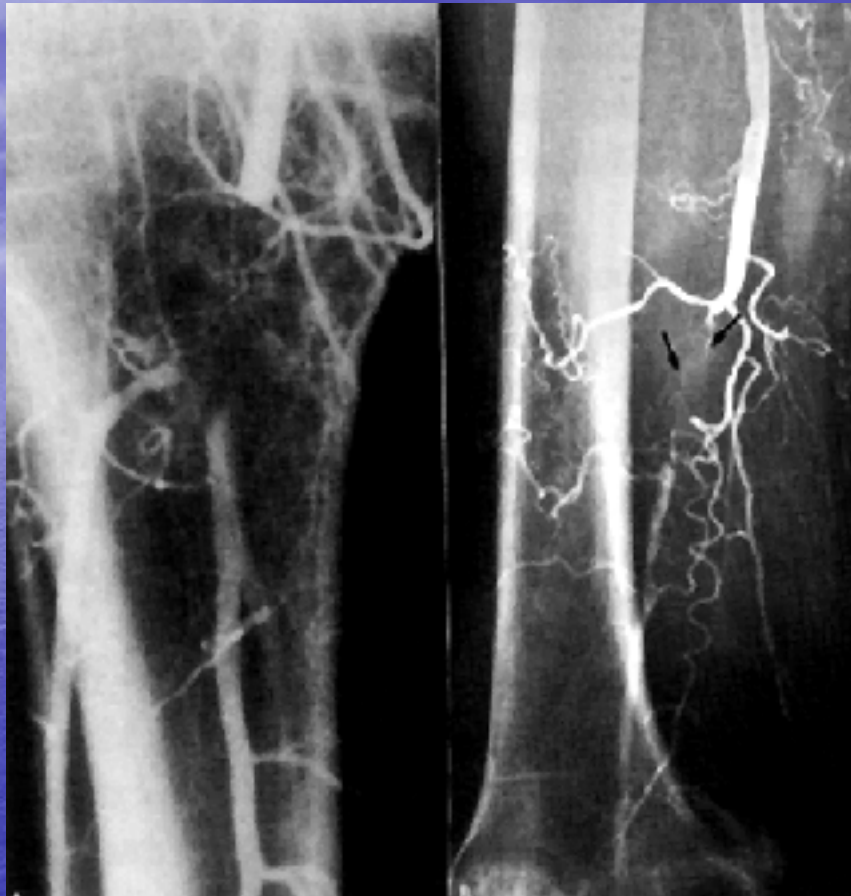Arteriografie cerebrala



Aneurism disecant



Sindrom Lerriche-angiografie



Stenoze la nivelul a. femurale-angiografie