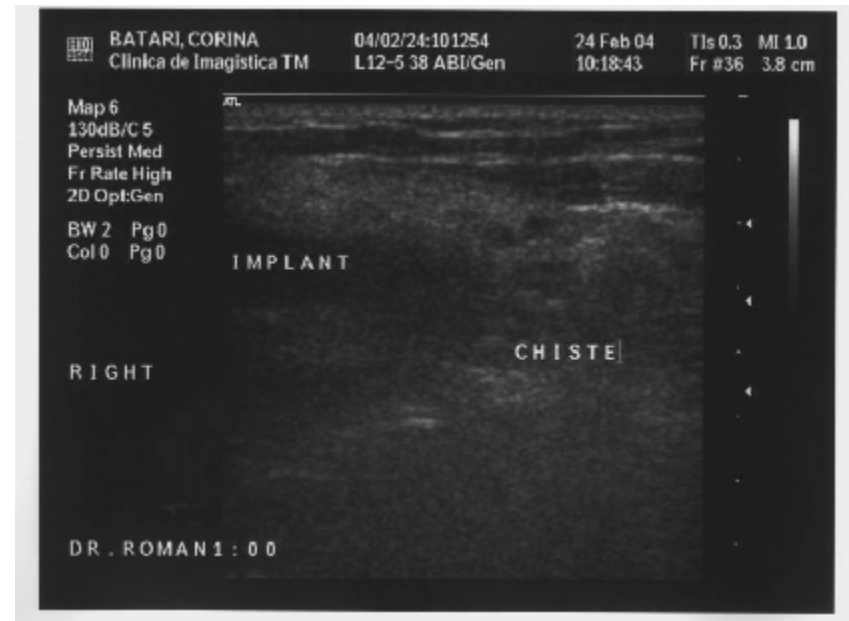
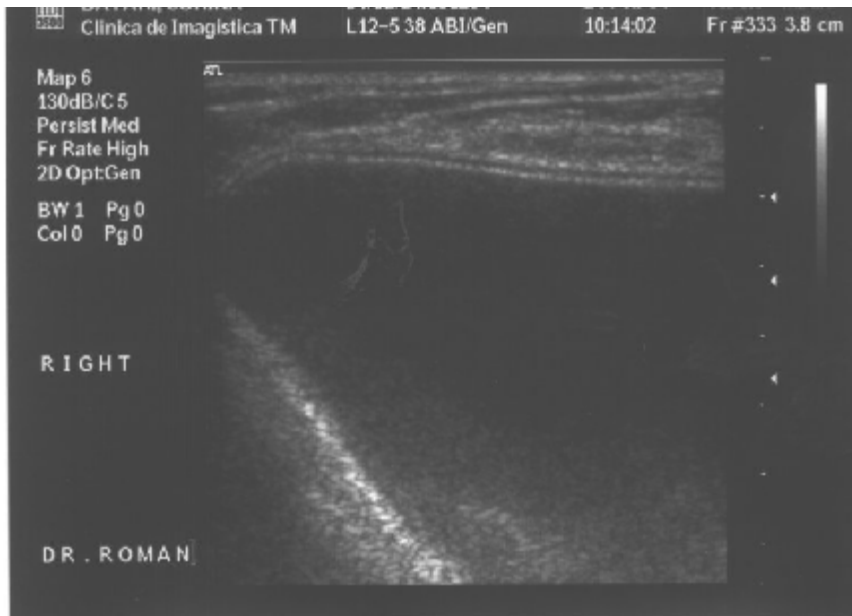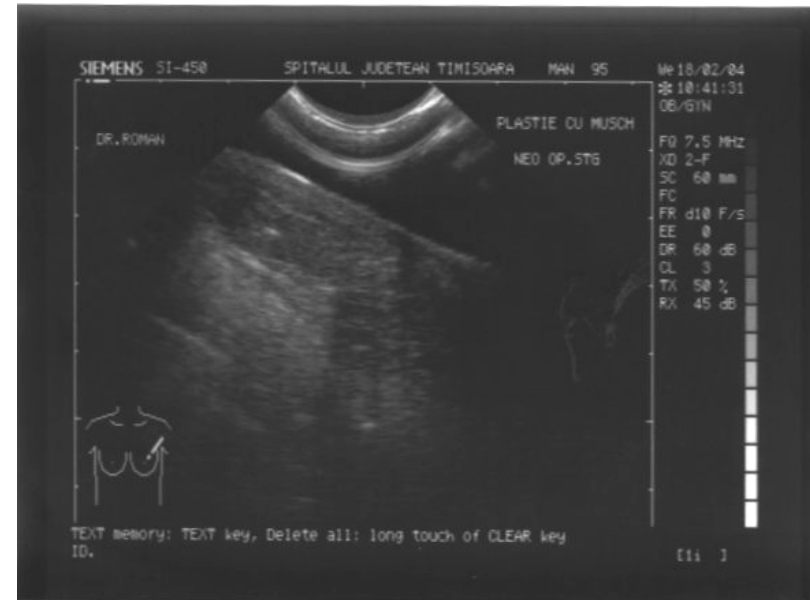
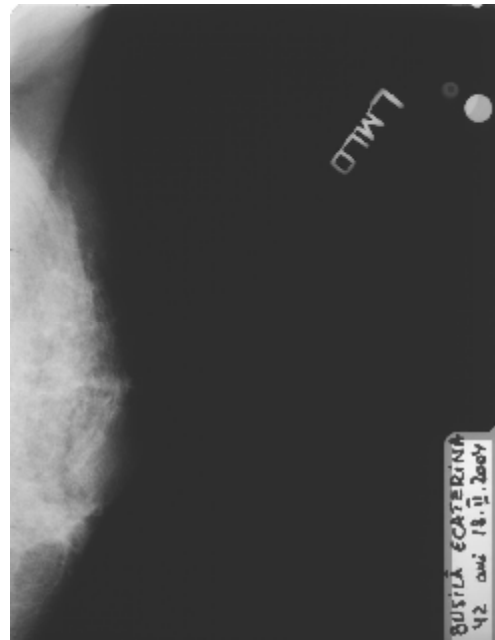
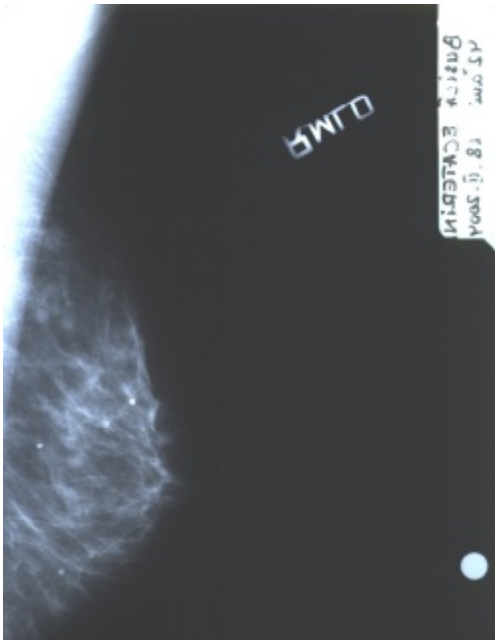


CAZURI CLINICE SENOLOGIE

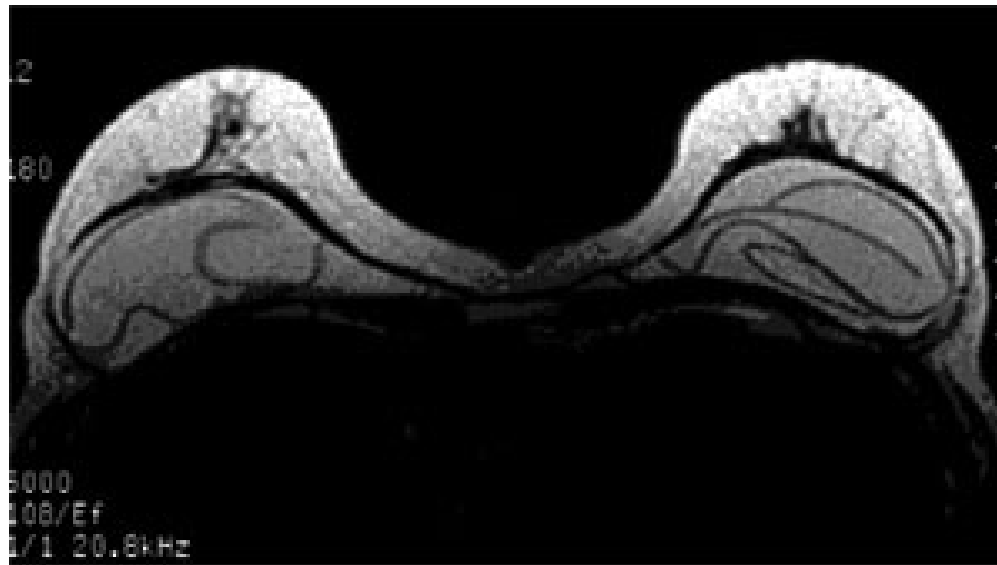


IMPLANTURI



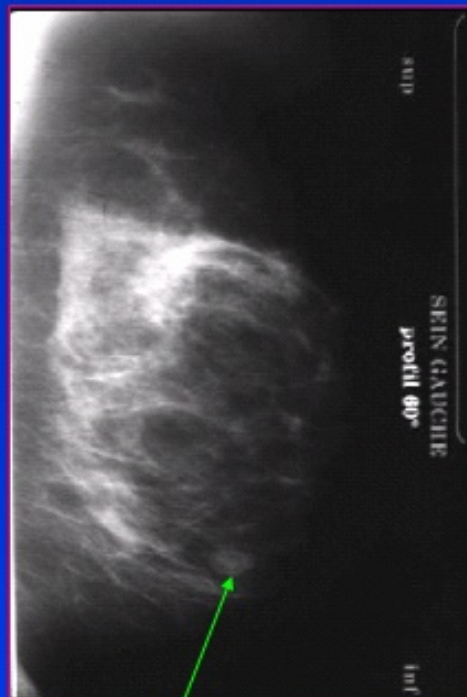


25 DE ANI, INTERVENȚIE CHIRURGICALĂ ANTERIOARĂ,
DURERI INTENSE SÂN DREPT

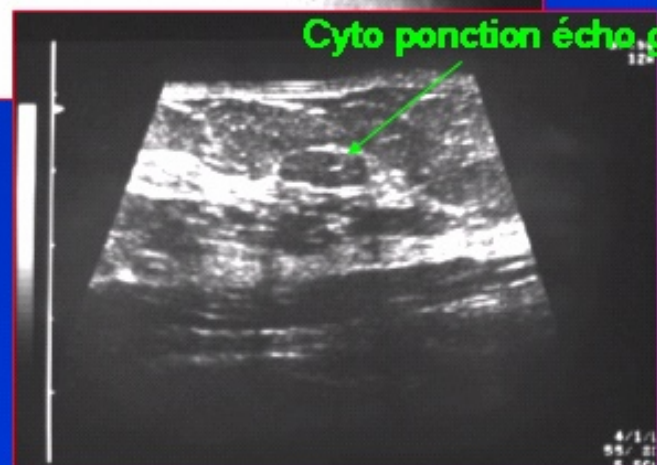
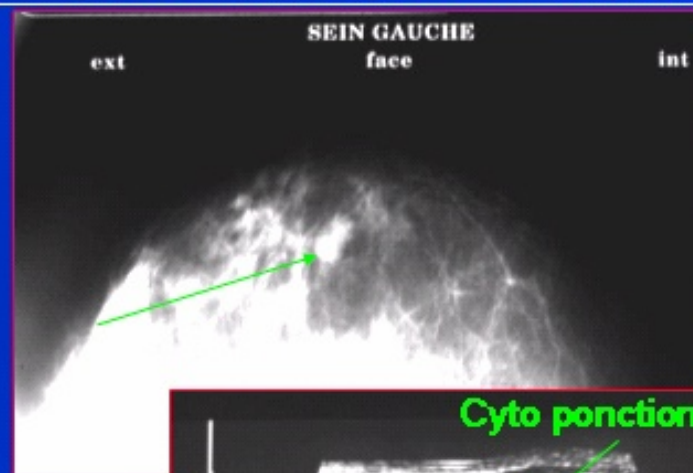


DIAGNOSTIC?

RUPTURĂ DE IMPLANT



*Cas clinique:
53 ans, surveillance de TSH,
image ACR 3, cytologie sous échographie*

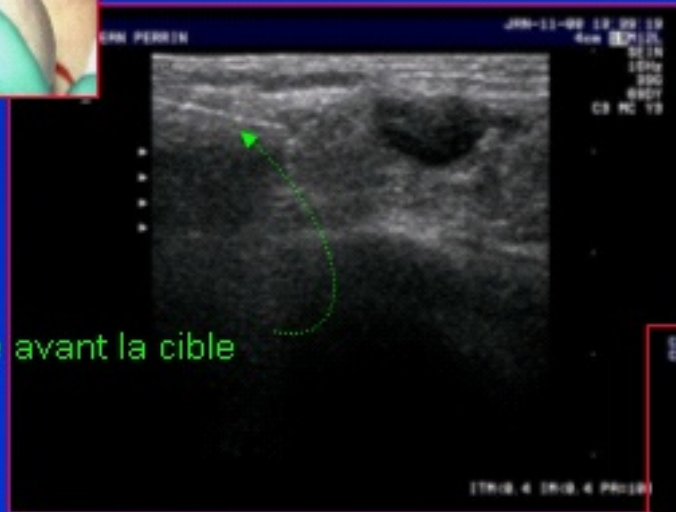
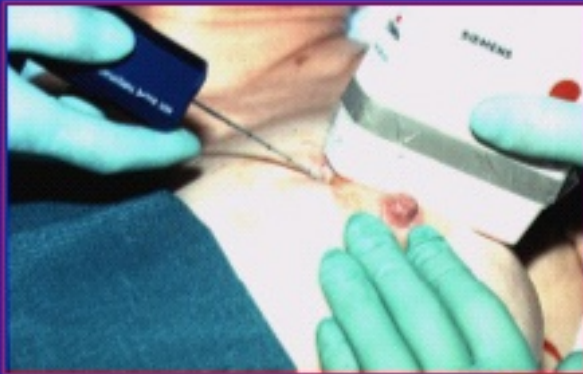
DIAGNOSTIC ?

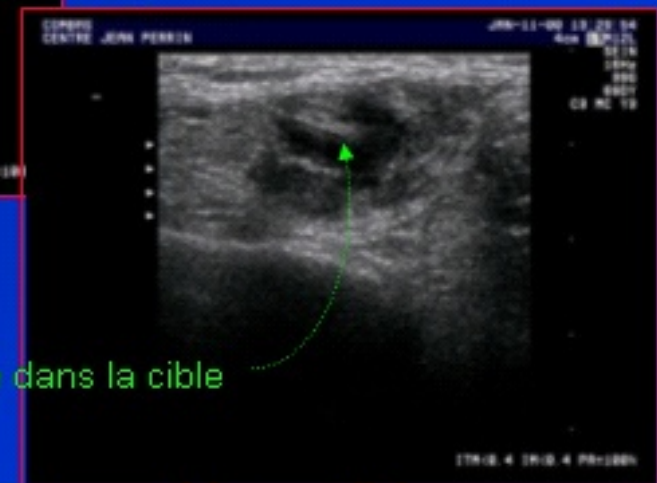
CANCER DUCTAL INFILTRATIF, COD 2/5



PUNCTIE ECOGHIDATĂ



Aiguille avant la cible

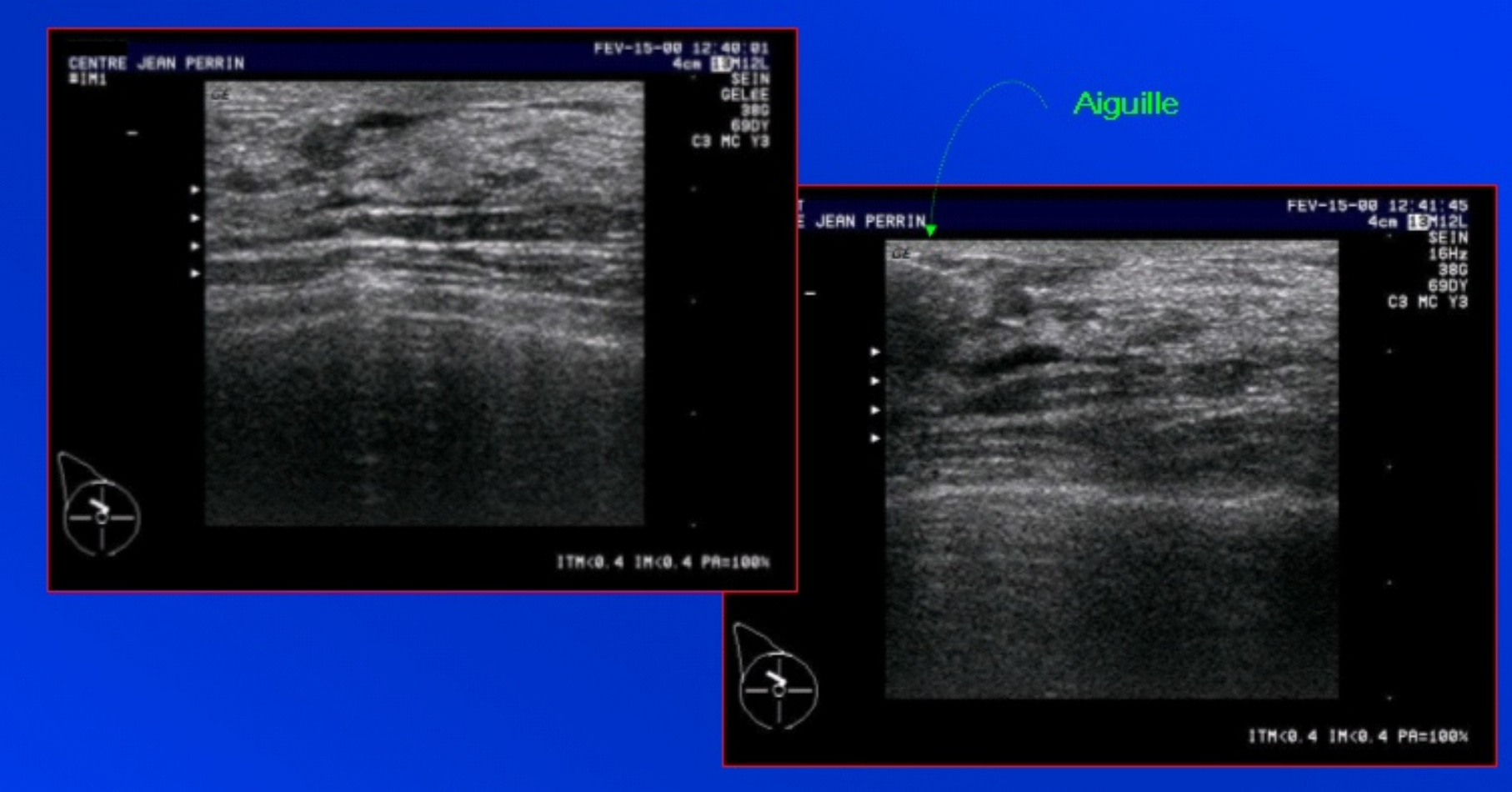


Aiguille dans la cible



DIAGNOSTIC ?

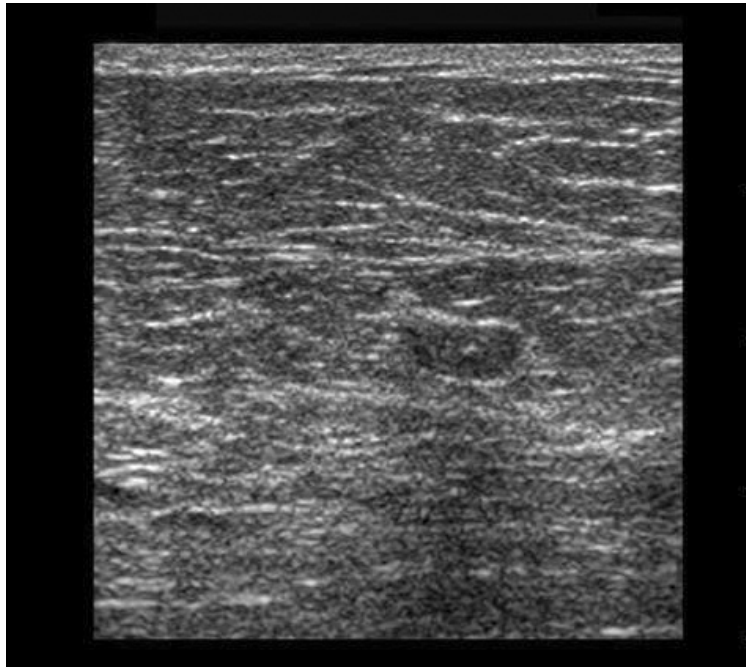
CHIST SOLITAR



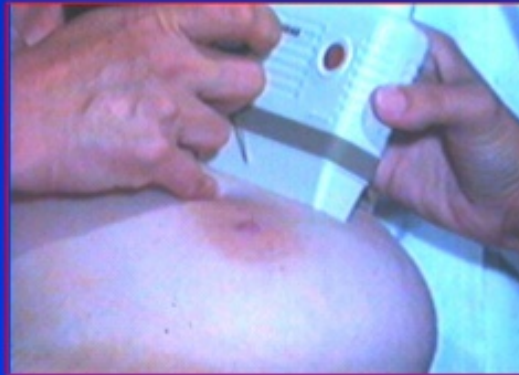CITOPUNCȚIE DIRECTĂ GHIDATĂ ECOGRAFIC



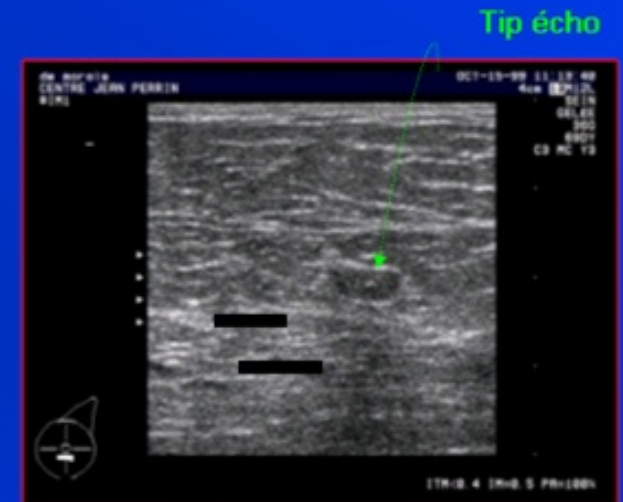
50 DE ANI, FORMAȚIUNE PALPABILĂ, APĂRUTĂ RECENT



DIAGNOSTIC ?

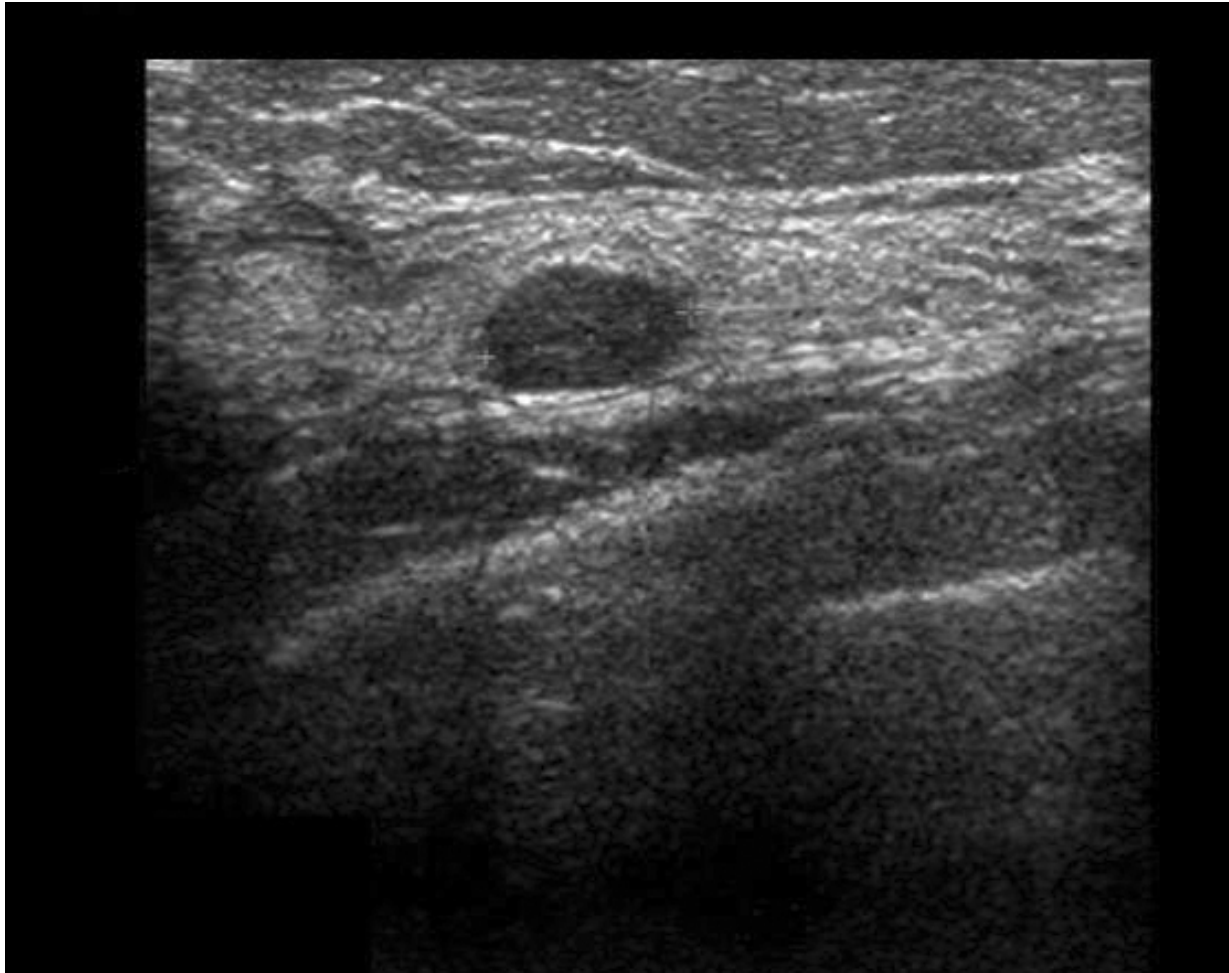


FIBROADENOM





**35 ANI, FORMAȚIUNE PALPABILĂ ÎN PRELUNGIREA AXILARĂ,
DUREROASĂ ȘI MOBILĂ**

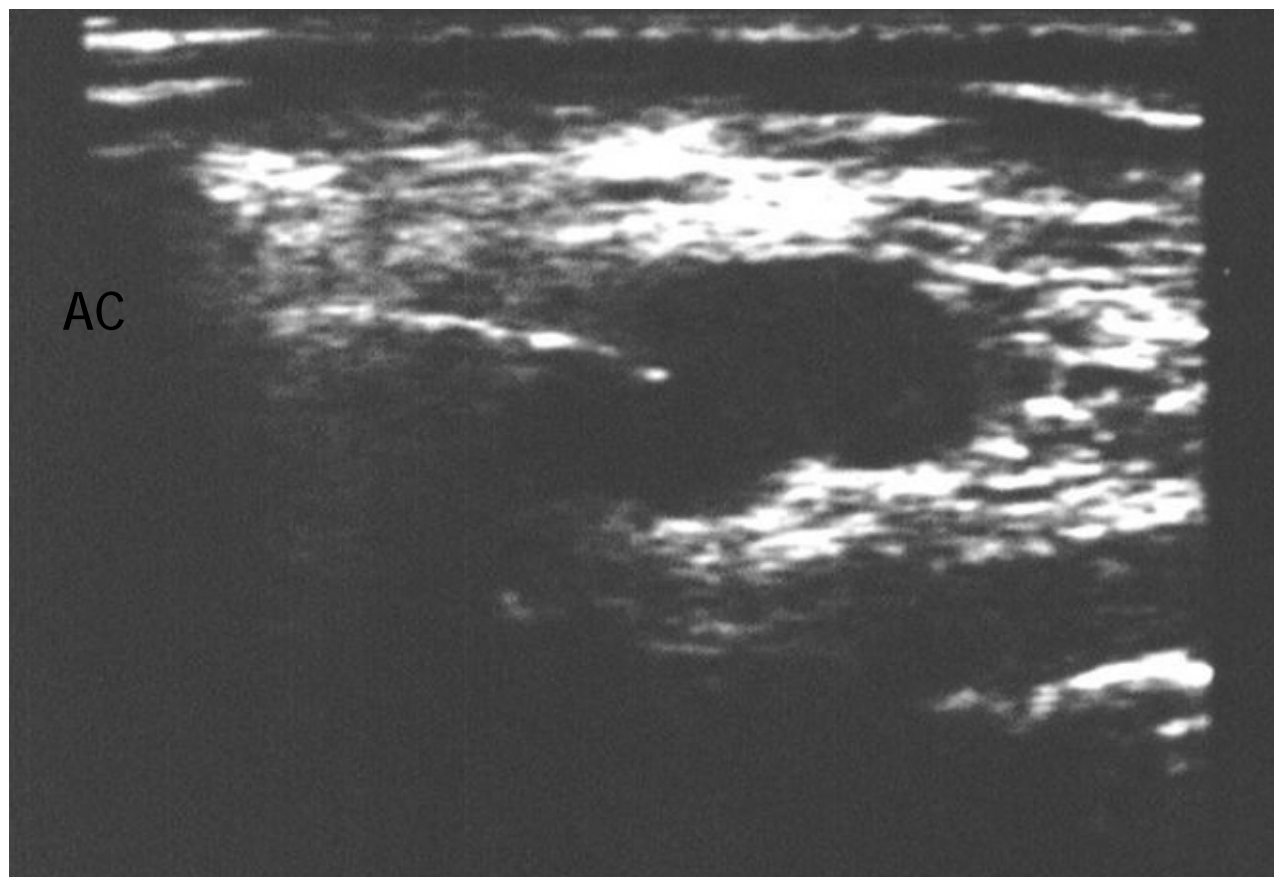


DIAGNOSTIC ?

CHIST CU CONȚINUT DENS



48 ANI, THS, MAMO-SÂN DENS

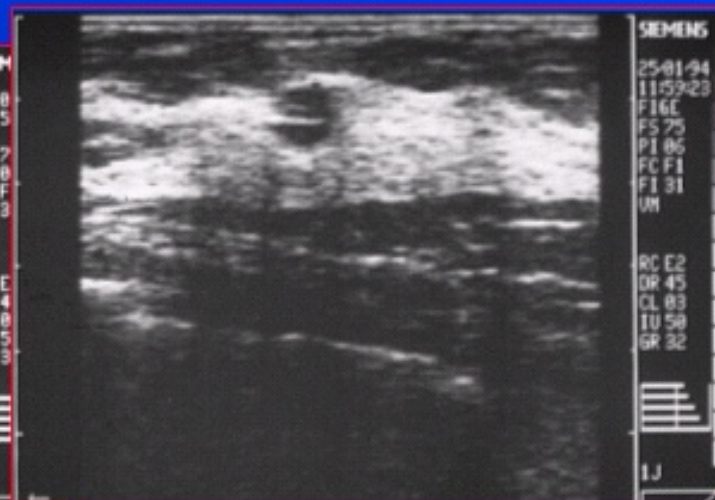
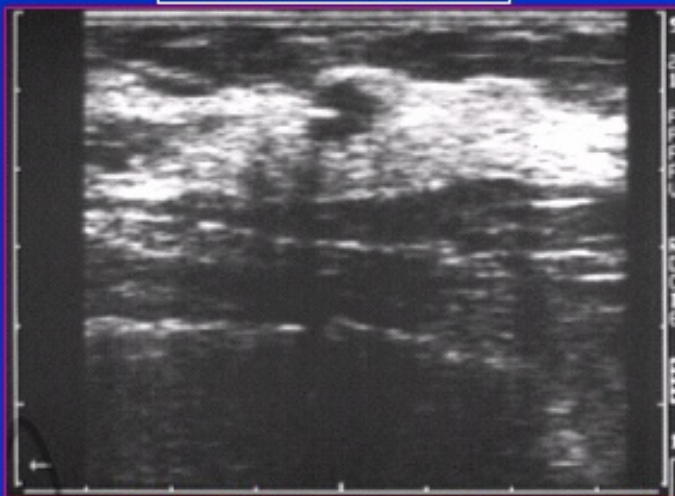


DIAGNOSTIC?

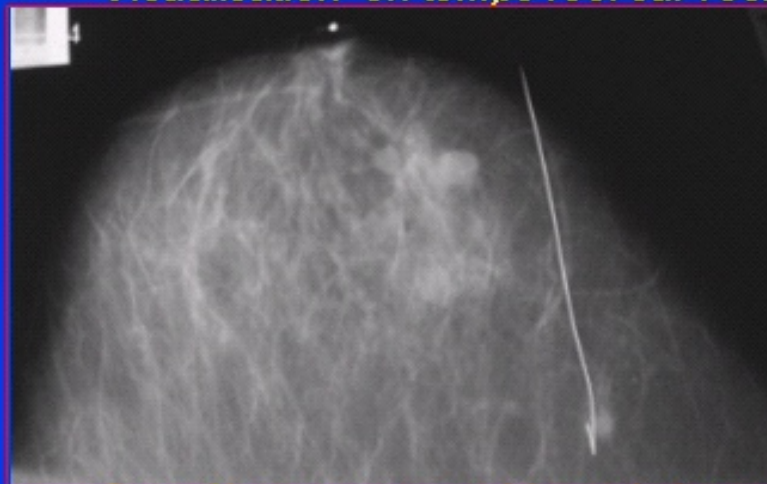
CCI

58 DE ANI, MASTOZĂ FIBROCHISTICĂ ÎN ANTECEDENTE, ÎN PROGRAM DE URMĂRIRE

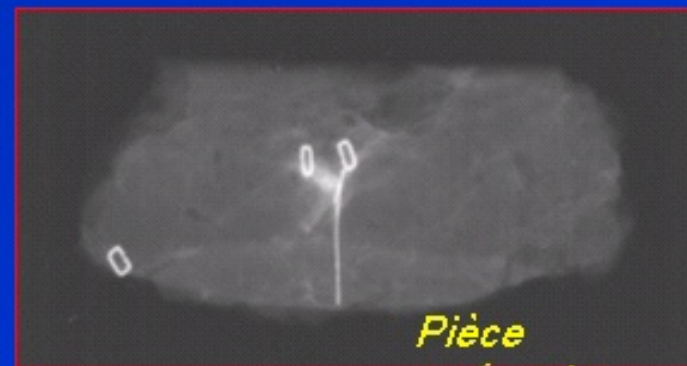62 DIAGNOSTIC ?



Visualisation en temps réel sur l'écran d'écho du largage du fil métallique



Contrôle mammographique de la position correcte du hameçon

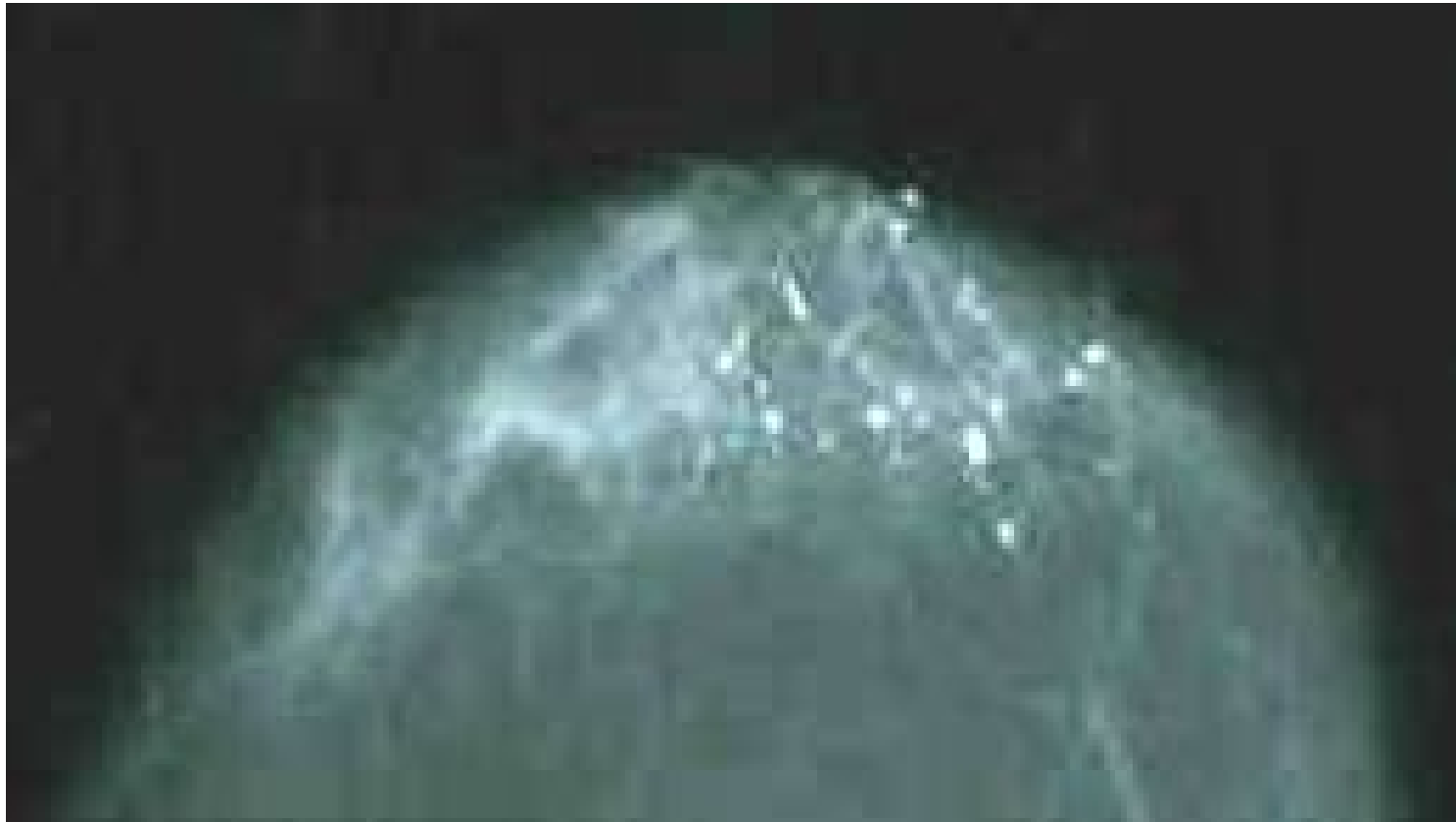


Pièce opératoire

CCI, COD 2/5



62 DE ANI, FĂRĂ SIMPTOMATOLOGIE CLINICĂ, ÎN PROGRAM DE URMARIRE

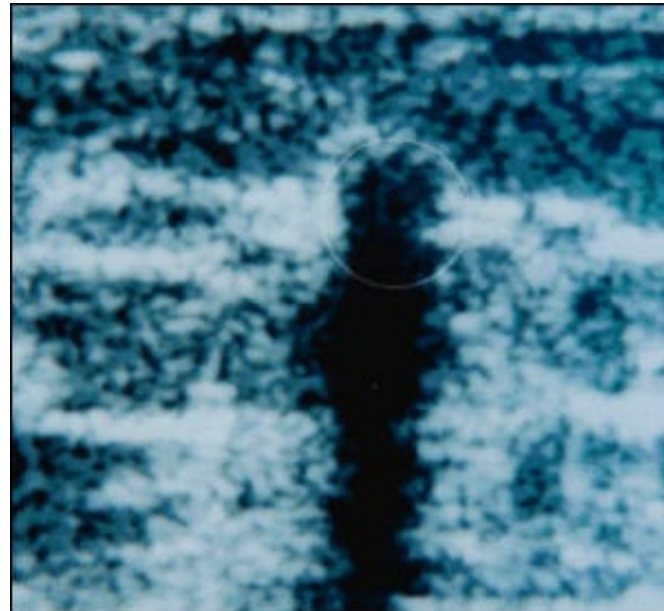
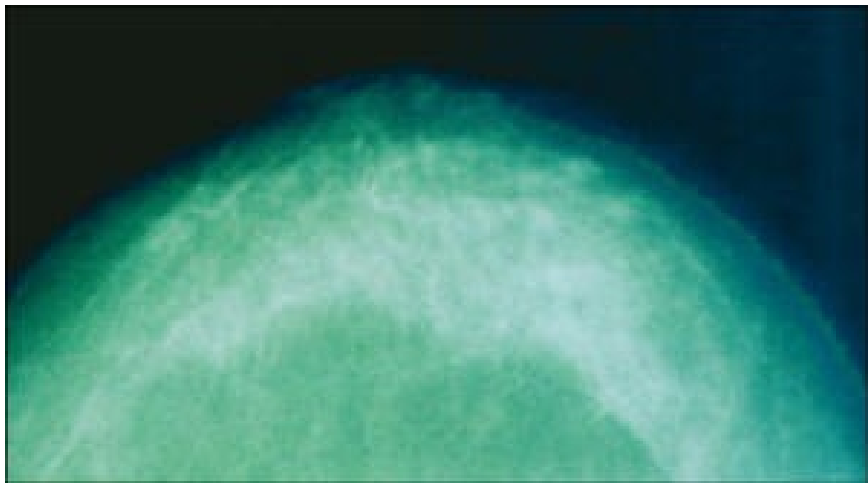


DIAGNOSTIC ?

COD BIRADS 2/2 - CALCIFICĂRI BENIGNE



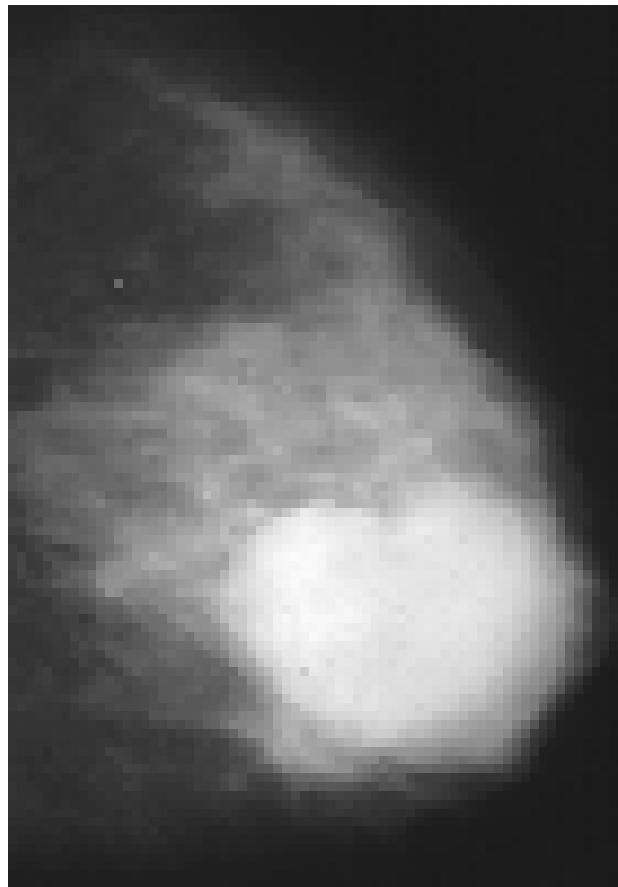
42 DE ANI, PREMENOPAUZĂ, ASIMPTOMATICĂ



DIAGNOSTIC? CCI, COD 3/5



MASĂ PALPABILĂ LA O FEMEIE DE 58 DE ANI

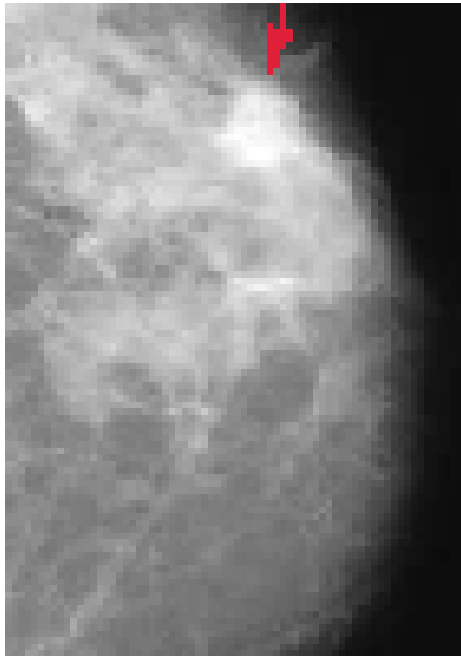


DIAGNOSTIC?

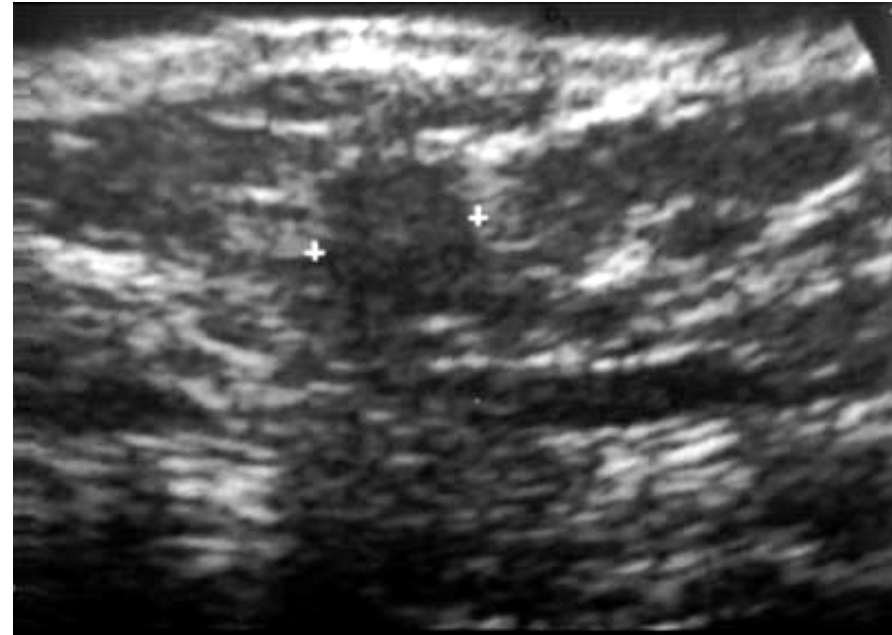TUMORĂ PHILODĂ, COD 3/5



42 DE ANI, FORMAȚIUNE PALPABILĂ, NEDUREROASĂ



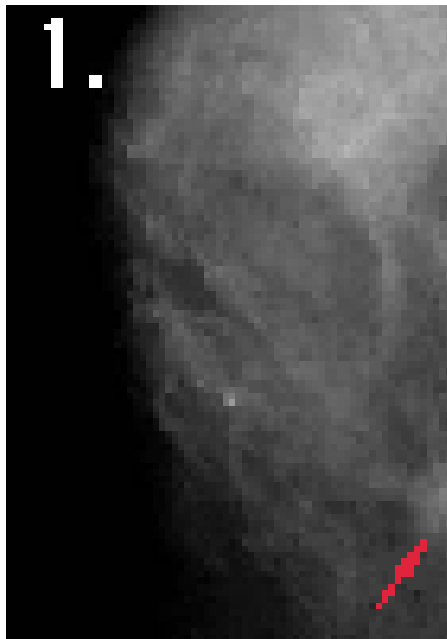
DIAGNOSTIC ?



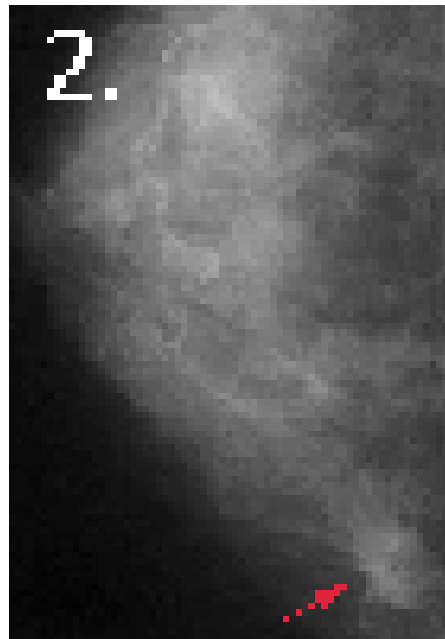
CARCINOM DUCTAL INFILTRATIV, COD 2/5



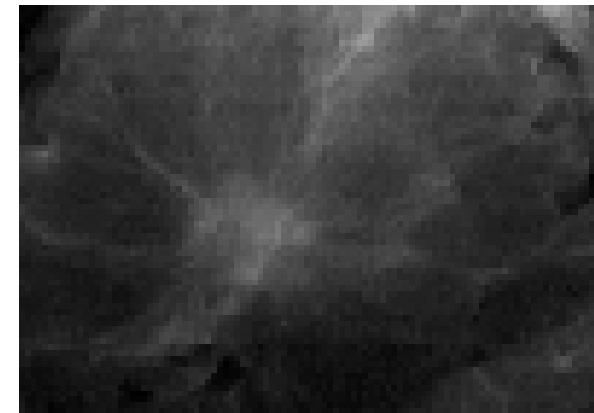
63 DE ANI, DENSIFICARE DIFUZĂ ÎN SANȚUL SUBMAMAR



DIAGNOSTIC?

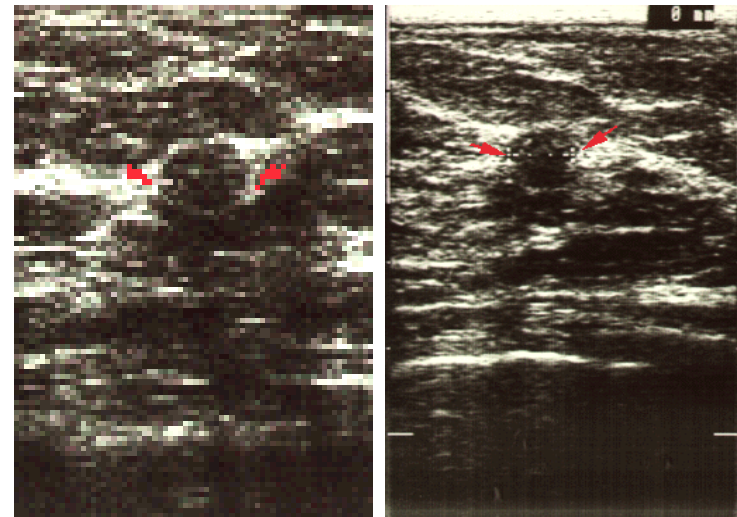
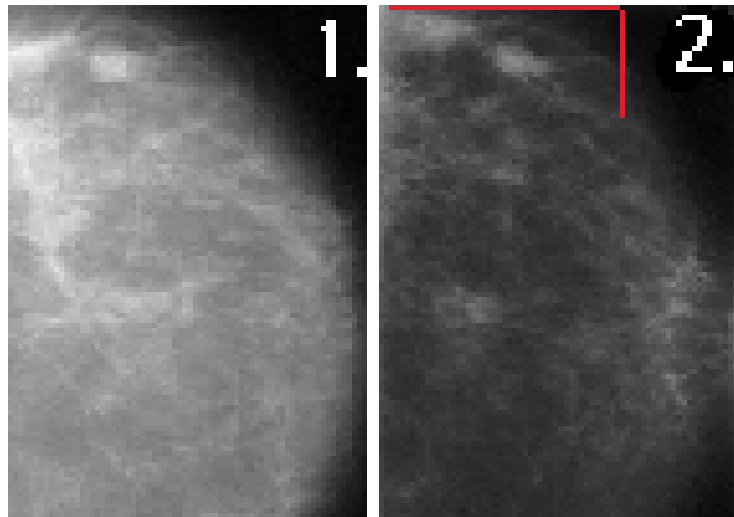


CCI, COD 2/5





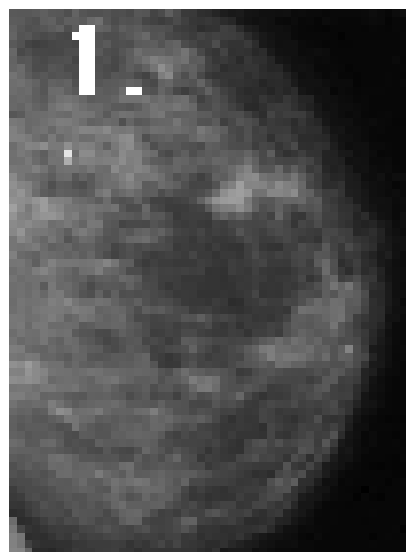
65 DE ANI, ÎN PROGRAM DE SCEENING,
ASIMPTOMATICA



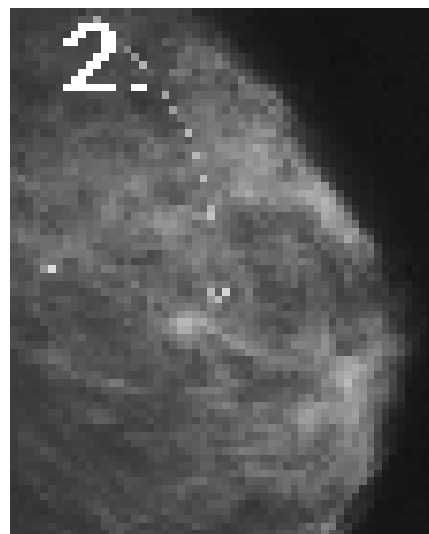
DIAGNOSTIC ? CANCER COLOID, COD 2/5



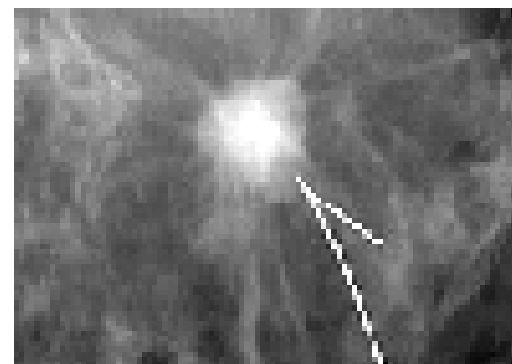
70 DE ANI, ASIMPTOMATICĂ



DIAGNOSTIC ?

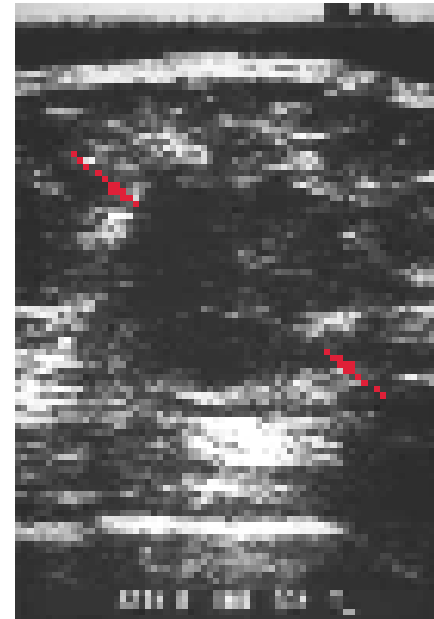
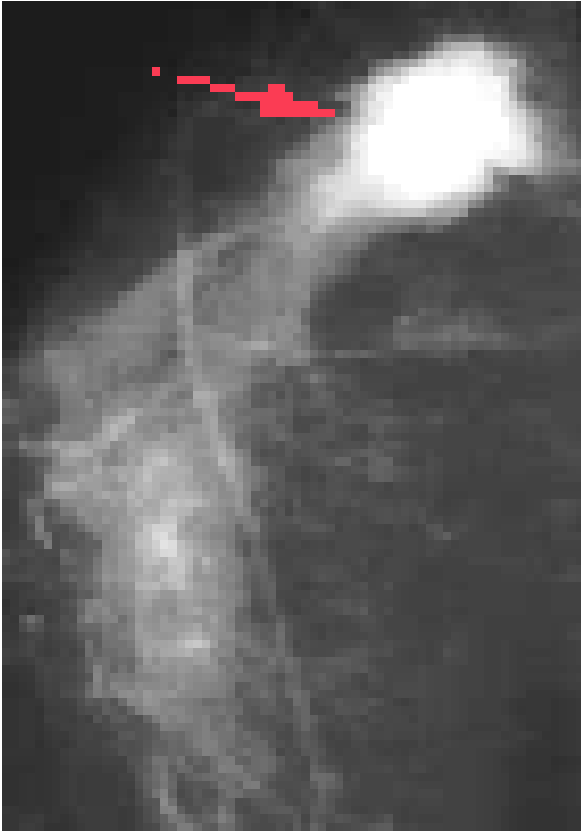

CCI, COD 2/5





63 DE ANI, FORMAȚIUNE PALPABILĂ

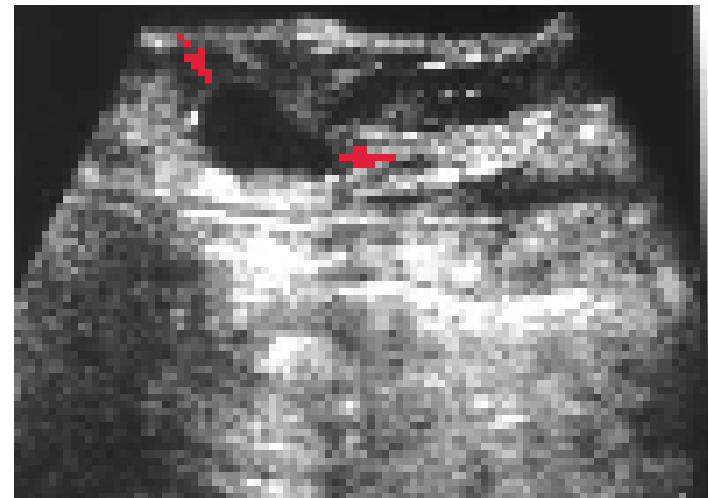
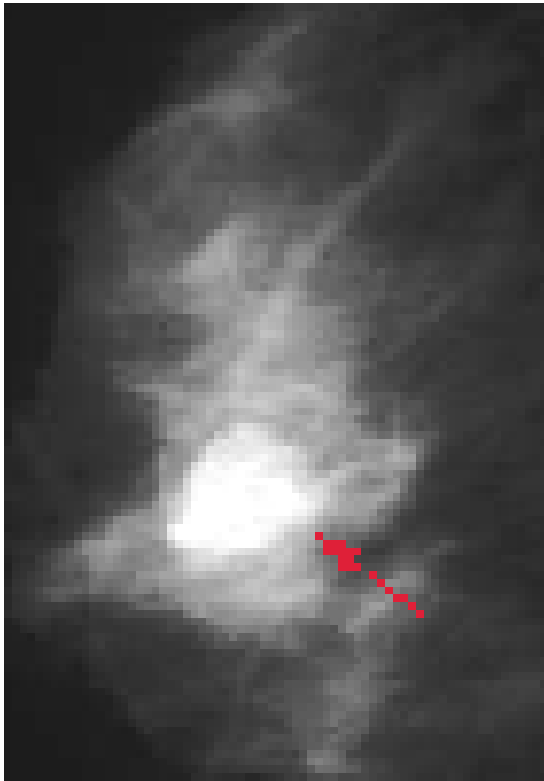


DIAGNOSTIC ?

CCI, COD 2/5



50 DE ANI, THS, EXAMEN DE RUTINĂ

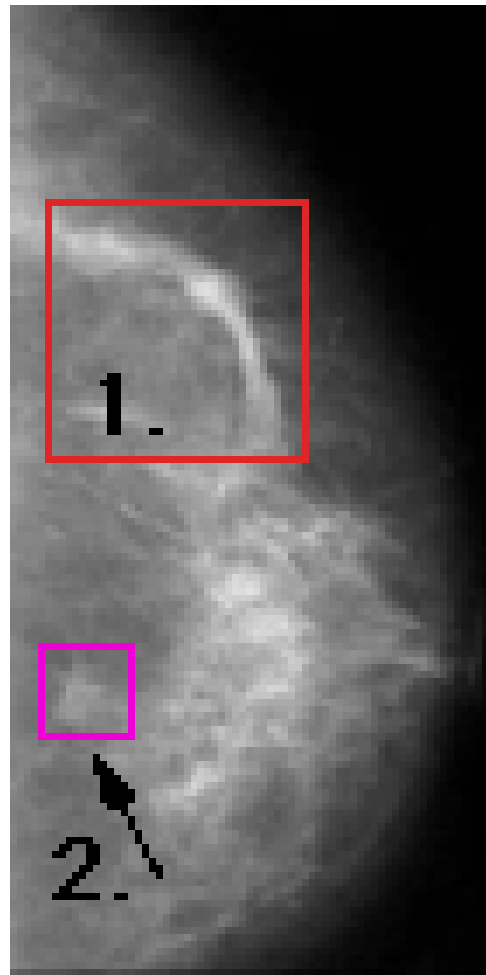


DIAGNOSTIC ?

CANCER MEDULAR, COD 2/5



40 DE ANI, EXAMEN DE RUTINĂ

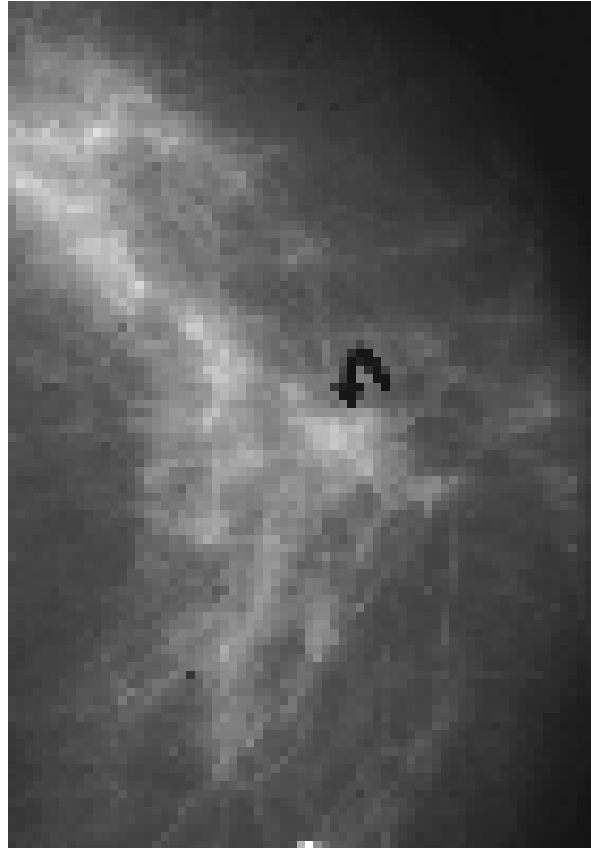


DIAGNOSTIC ?

CANCER MULTICENTRIC, COD 2/5



54 DE ANI, EXAMEN DE RUTINĂ

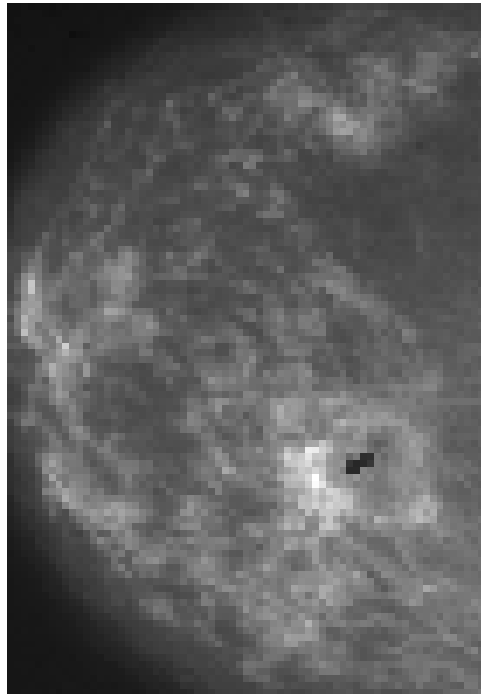


DIAGNOSTIC ?

CANCER DUCTAL INFILTRATIV, COD 2/5



52 DE ANI, EXAMEN DE RUTINĂ

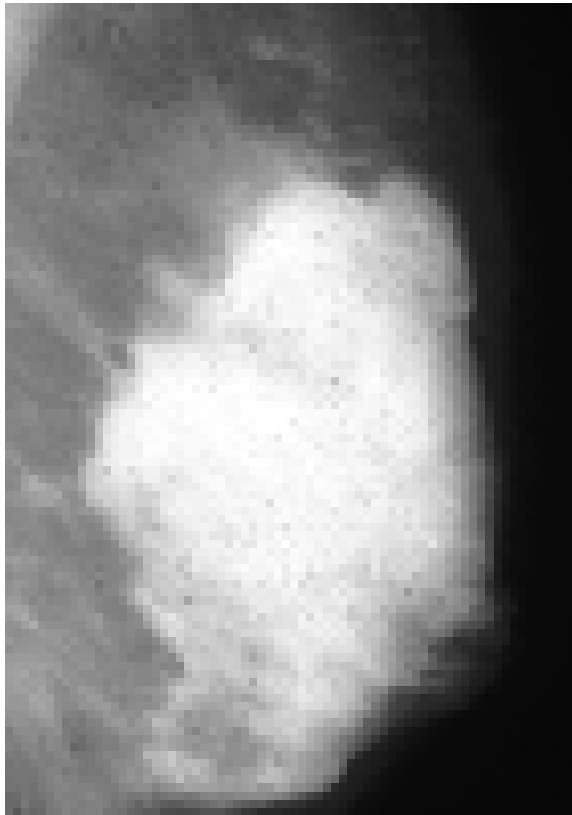


DIAGNOSTIC ?

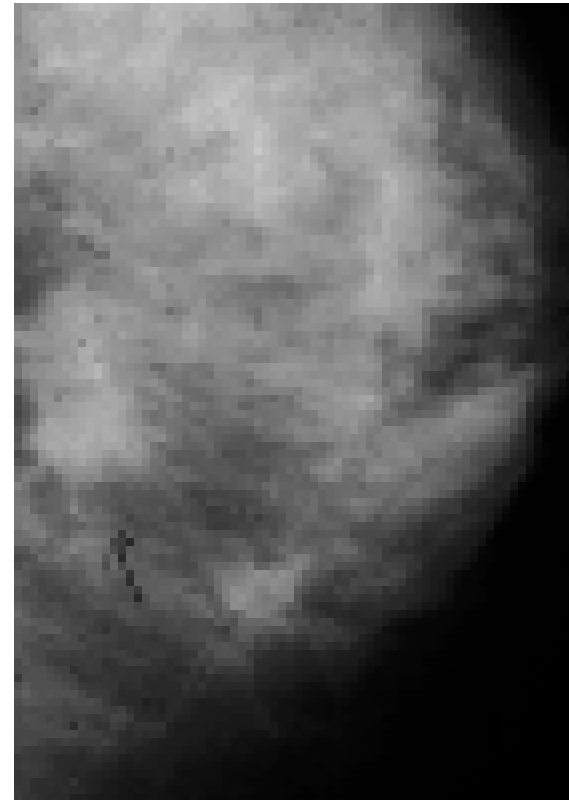
CANCER DUCTAL INFILTRATIV, COD 2/5



48 DE ANI, EXAMEN DE RUTINĂ



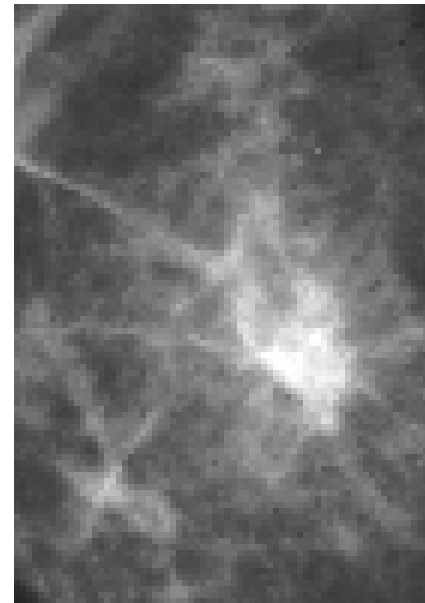
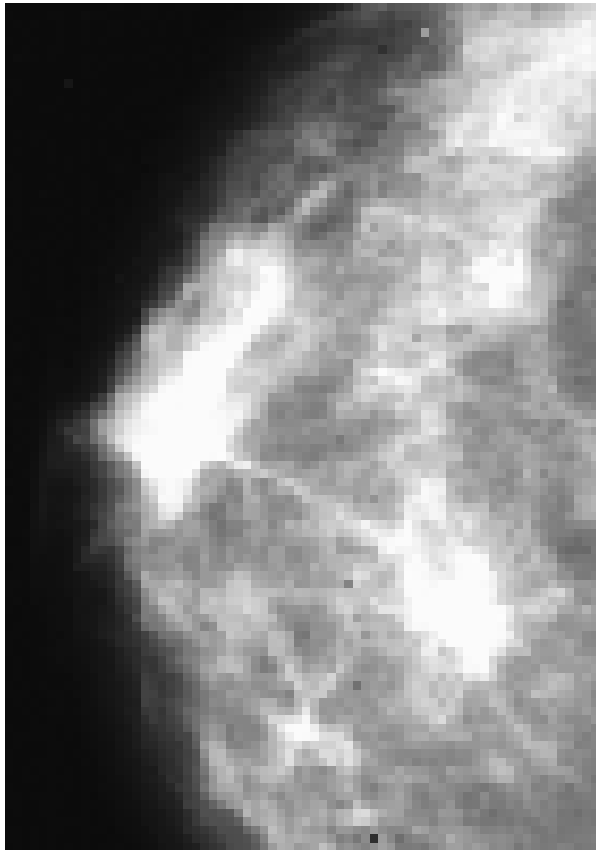
DIAGNOSTIC ?



SÂN DENS, COD 4/0



48 DE ANI, EXAMEN DE RUTINĂ

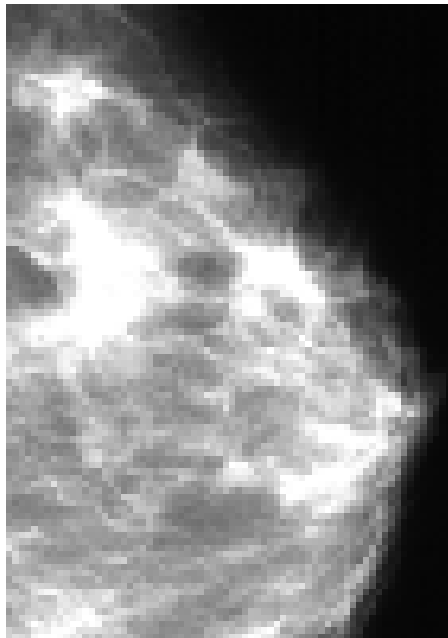


DIAGNOSTIC ?

CCI, COD 3/5

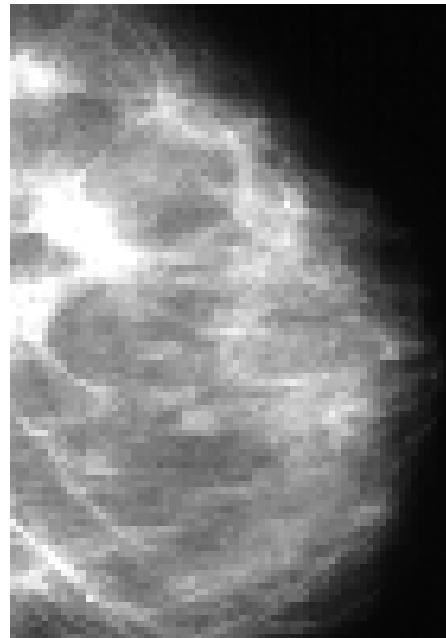


50 DE ANI, EXAMEN DE RUTINĂ



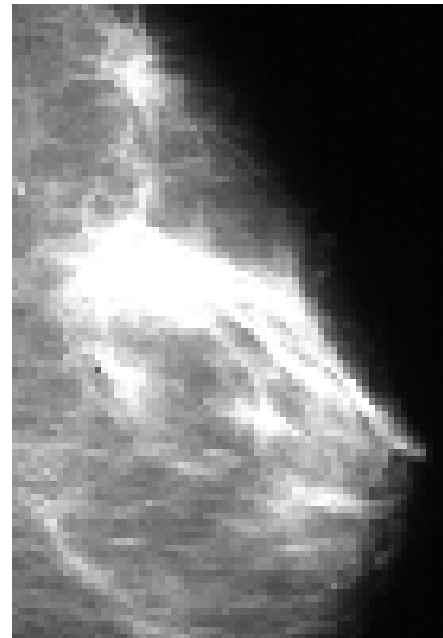
CC-2000

DIAGNOSTIC ?

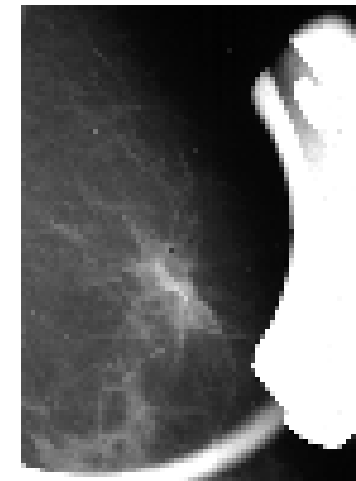


CC 2001

CCI, COD 3/5

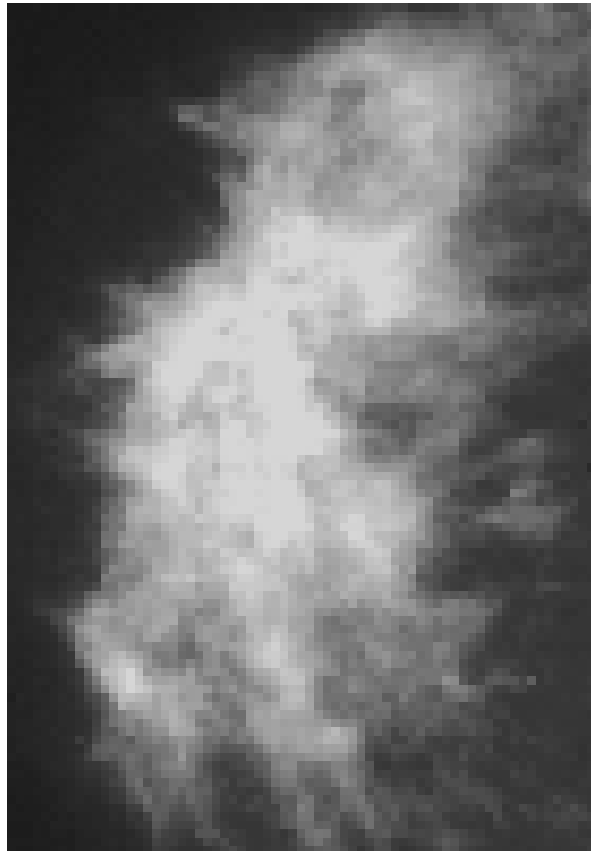


ML 2001





45 DE ANI, ÎMPĂSTARE A CADRANULUI
SUPEROEXTERN SÂN DREPT

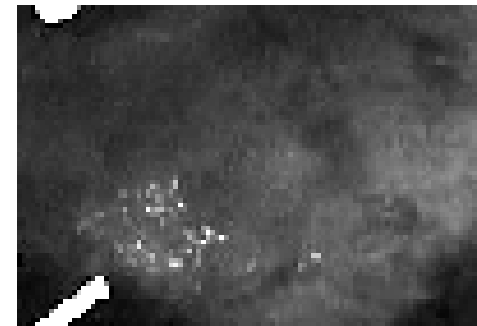
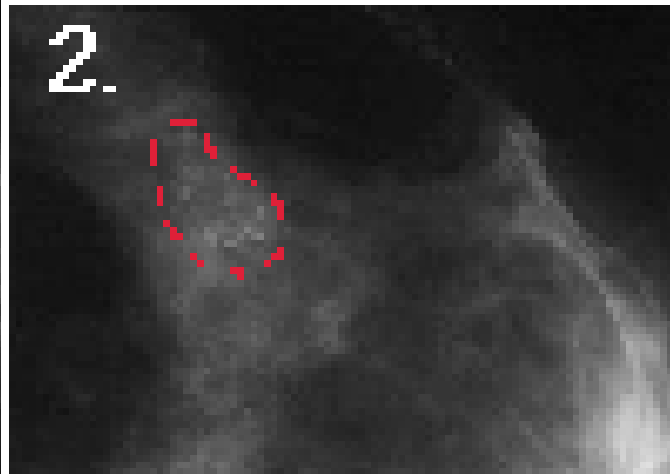
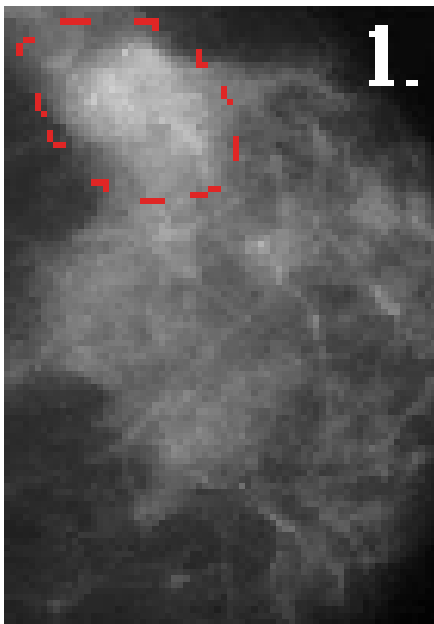


DIAGNOSTIC ?

CLI, COD 3/5



42DE ANI, ASIMPTOMATICĂ, ÎN AHC 2
CAZURI DE CANCER DE SÂN

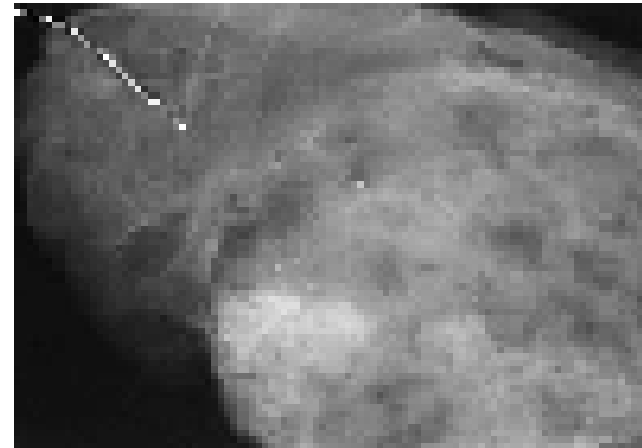
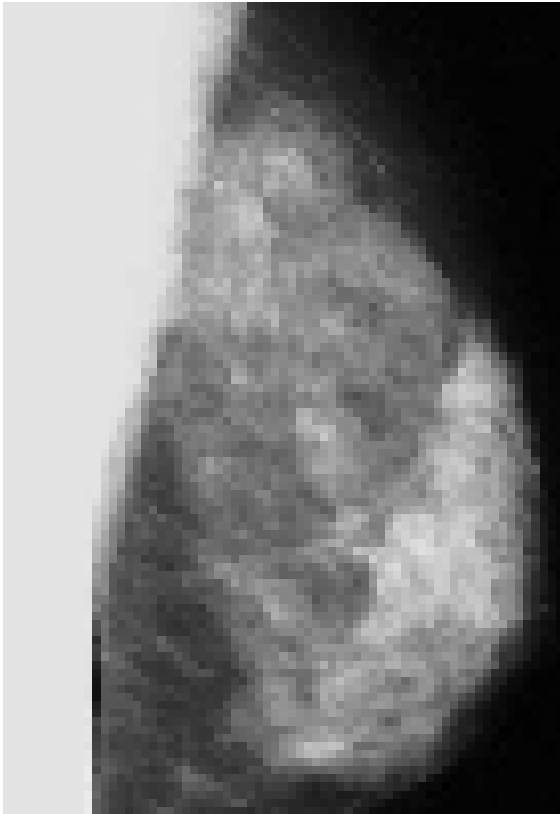


DIAGNOSTIC ?

CCI, COD 3/5



62 DE ANI, ASIMPTOMATICĂ, THS


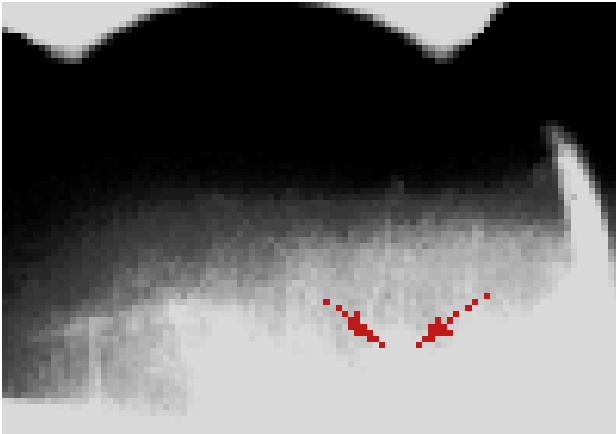


DIAGNOSTIC ?

CCI, COD 3/5



62 DE ANI, CCI TRATAT ÎN URMĂ CU 4 ANI

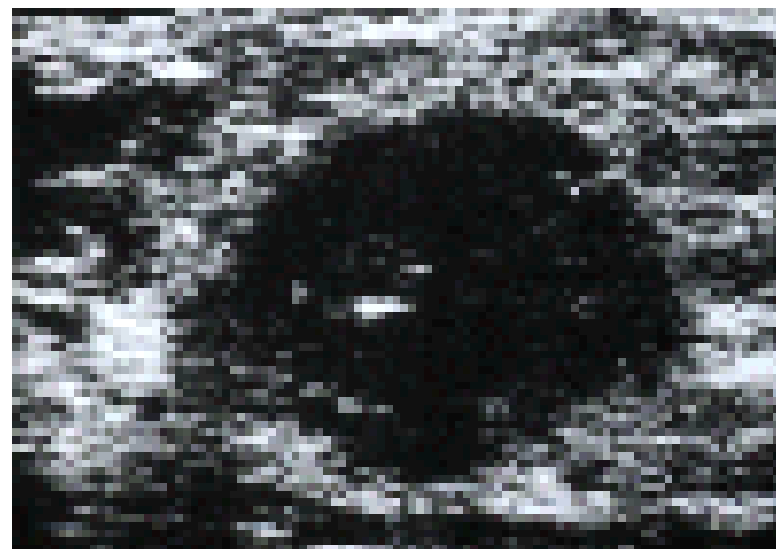
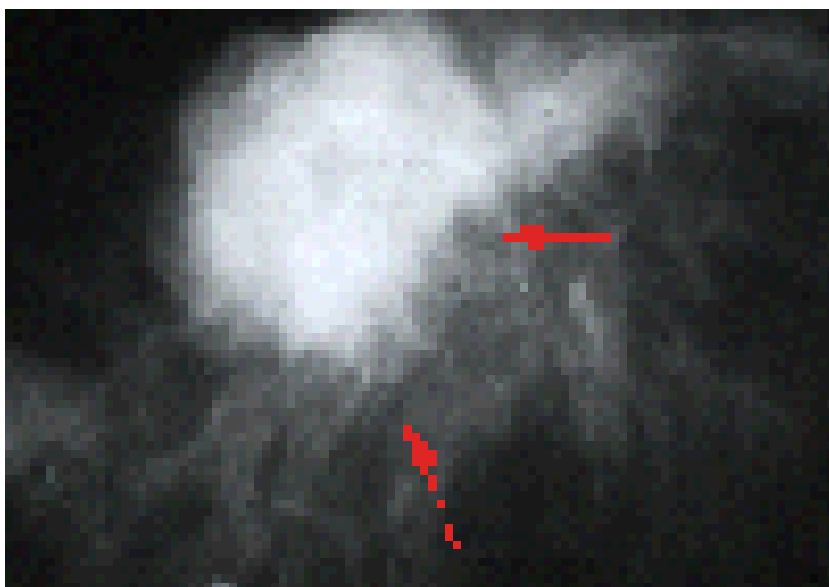


DIAGNOSTIC ?

RECIDIVĂ CCI, COD 3/5



**48 DE ANI, TUMORĂ PALPABILĂ
RETROAREOLAR, MOBILĂ, NEDUREROASĂ**

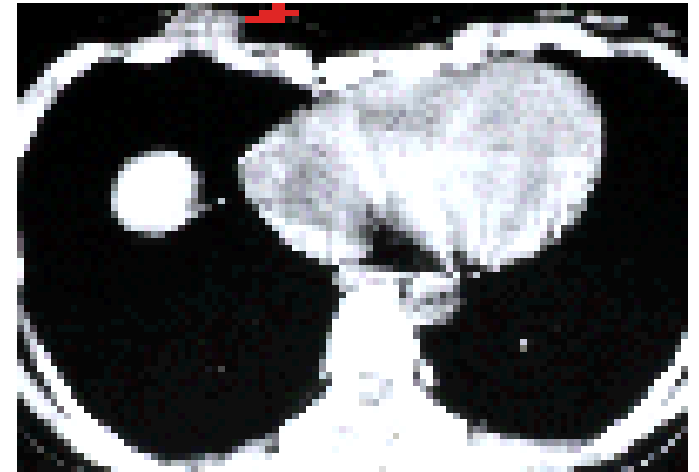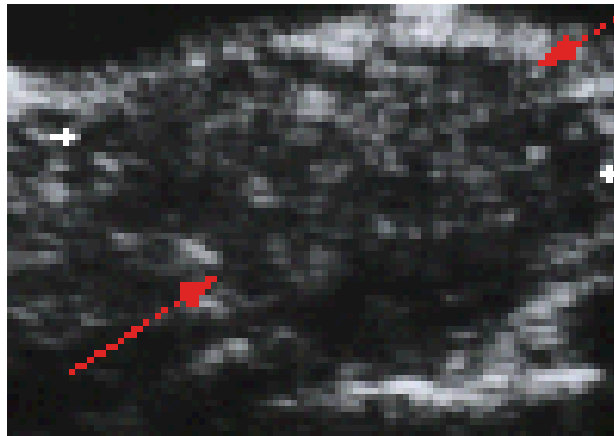
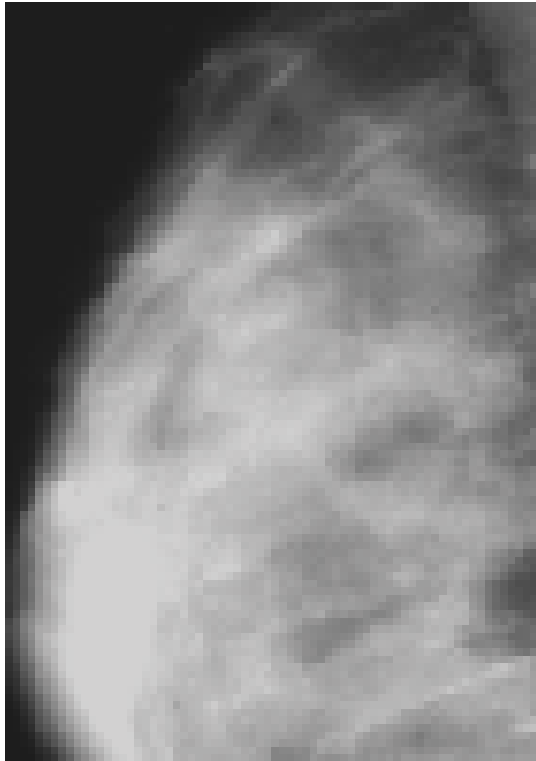


DIAGNOSTIC ?

TUMORĂ PHILODĂ MALIGNĂ, COD 2/5



31 DE ANI, TUMORĂ PALPABILĂ ÎN ȘANTUL
SUBMAMAR DREPT, IMOBILĂ,
NEDUREROASĂ

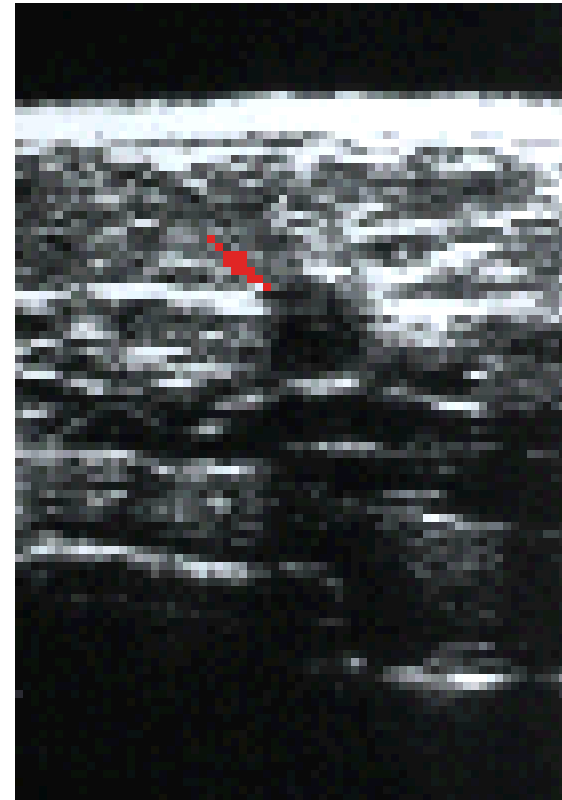
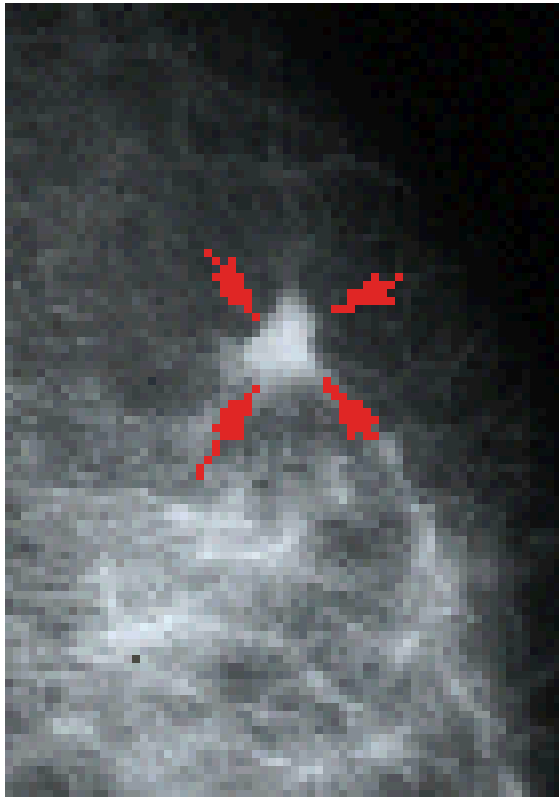


DIAGNOSTIC ?

FĂRĂ LEZIUNI FOCALE, COD 4/1
MIOSARCOM DE PECTORAL DREPT



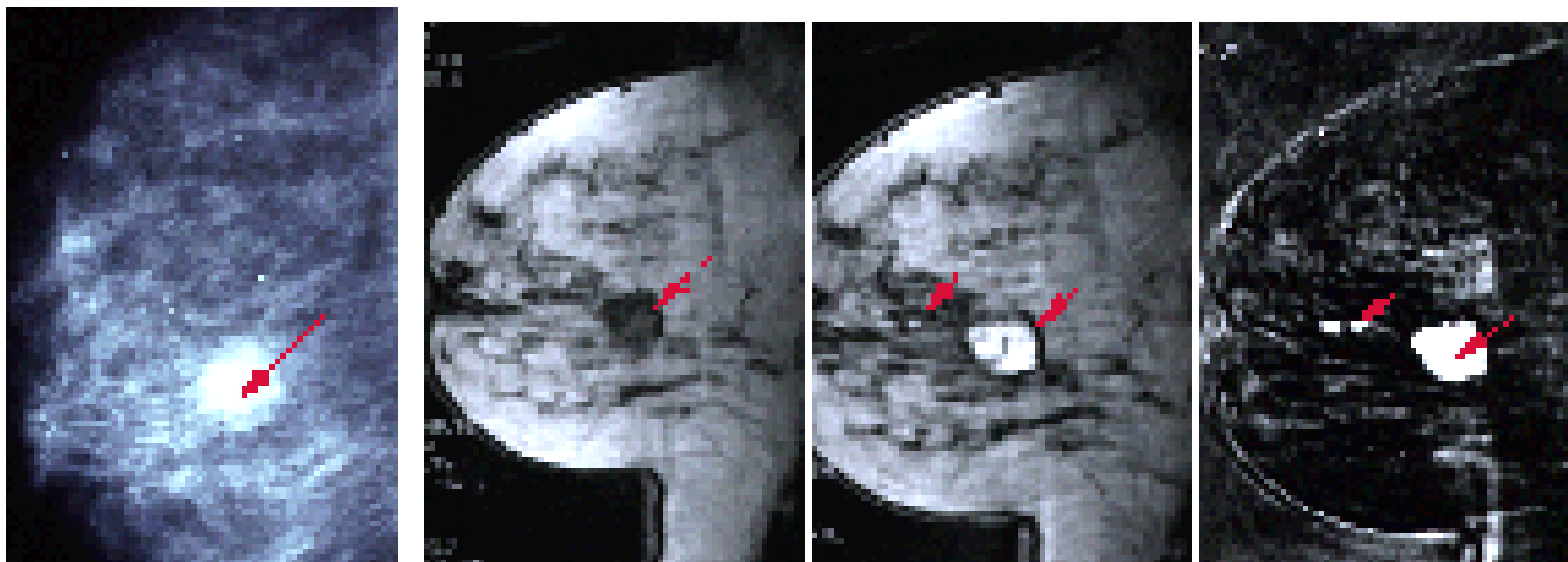
63 DE ANI, TUMORĂ PALPABILĂ ÎN SÂNUL STÂNG, IMOBILĂ, NEDUREROASĂ



DIAGNOSTIC ?

CCI, COD 3/5

**41 DE ANI, SÂN MARE, AHC DE CANCER
MAMAR**

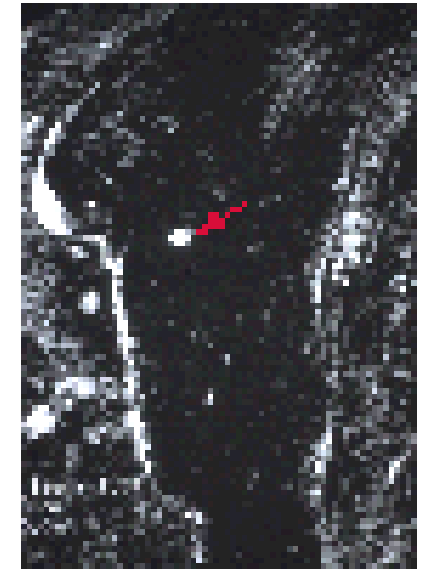
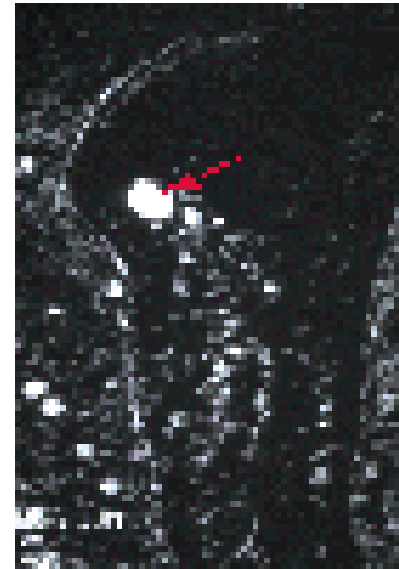
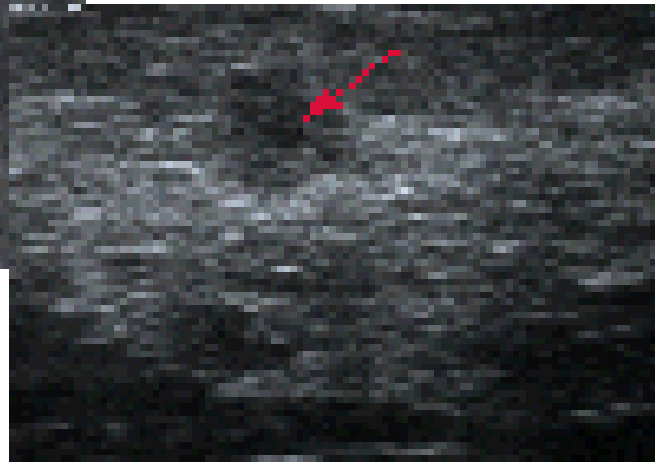
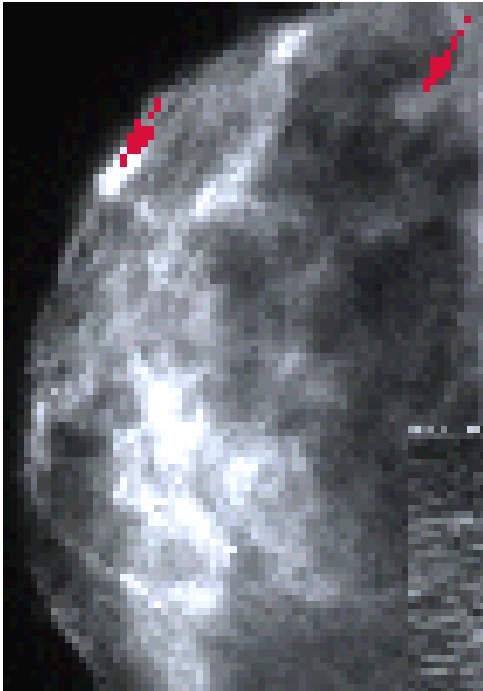

**IRM CUPĂ SAGITALĂ NATIVĂ, CU SDC
PRECOCE, CU SUBSTRACȚIE DE GRĂSIME**

DIAGNOSTIC ? CCI, COD 3/5



**42 DE ANI, OPERATĂ ȘI TRATATĂ PENTRU
UN CC DE SÂN**



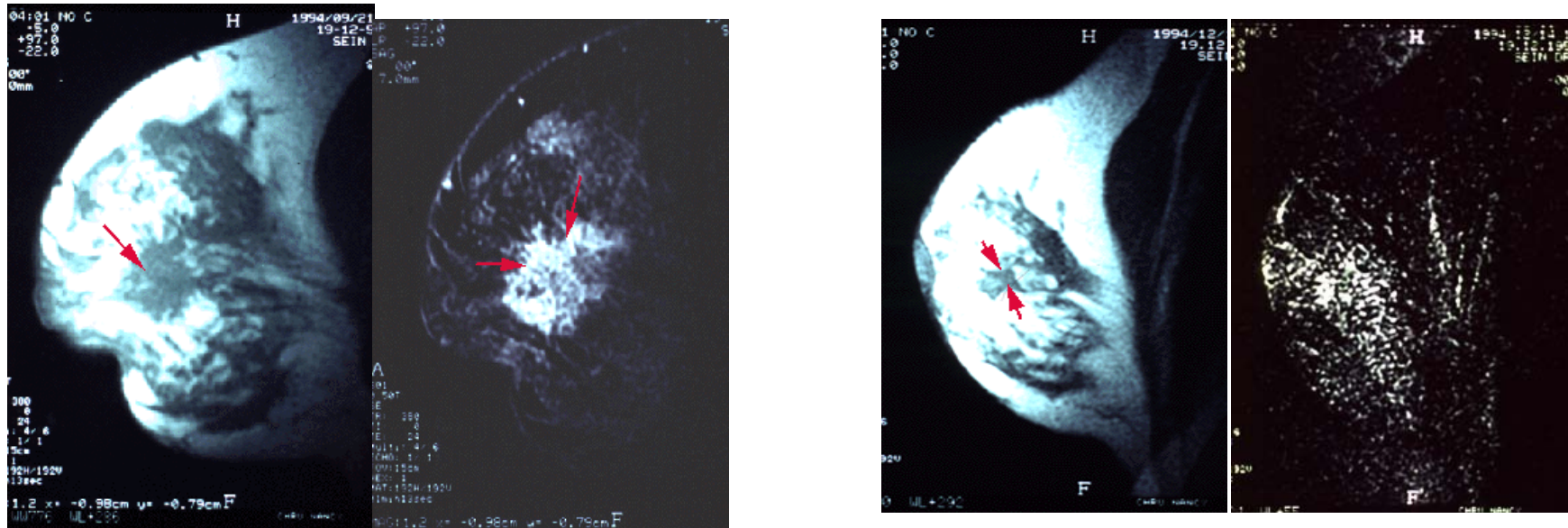
**IRM CUPE SAGITALE, CU SDC
PRECOCE, CU SUBTRACȚIE
DE GRĂSIME, ÎN PLANURI DIFERITE**

DIAGNOSTIC ?

RECIDIVĂ MULTIFOCALĂ, COD 2/5



62 DE ANI, THS, SÂN MARE ȘI DENS, TUMORĂ PALPABILĂ, CU RETRAȚIE DE PIELE



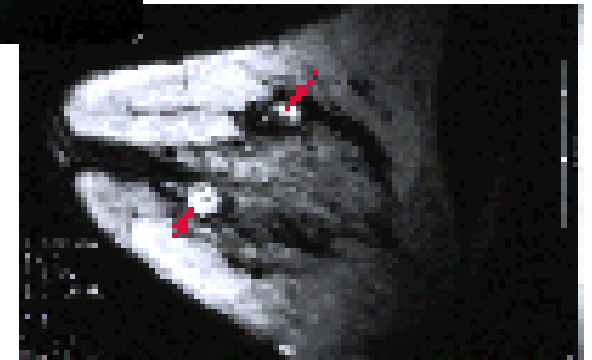
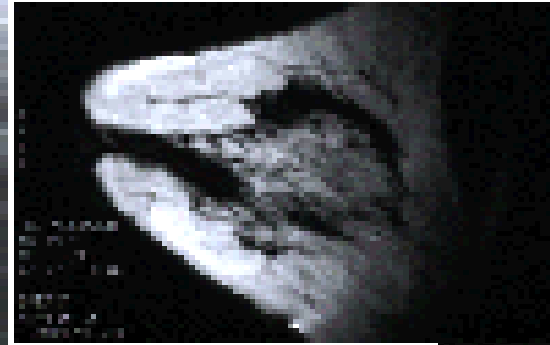
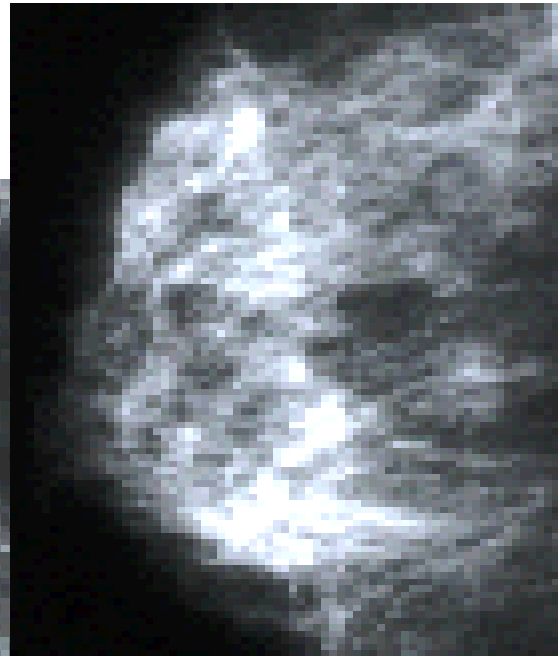
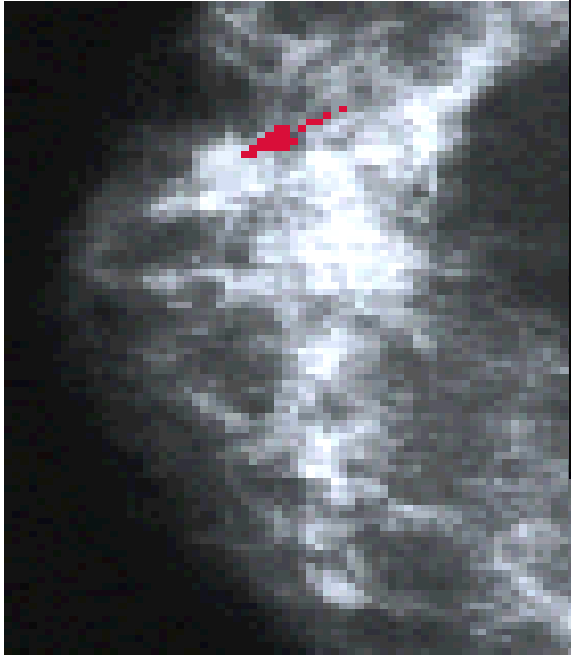
IRM CUPE SAGITALE NATIV ȘI CU SDC PRECOCE, CU SUBSTRACȚIE DE GRĂSIME, ÎNAINTE ȘI DUPĂ CHIMIOTERAPIE NEOADJUVANTĂ

DIAGNOSTIC ?

CARCINOM DUCTAL INFILTRATIV RECONVERTIT
ÎN ST.II



58 DE ANI, THS, SÂN MARE ȘI DENS



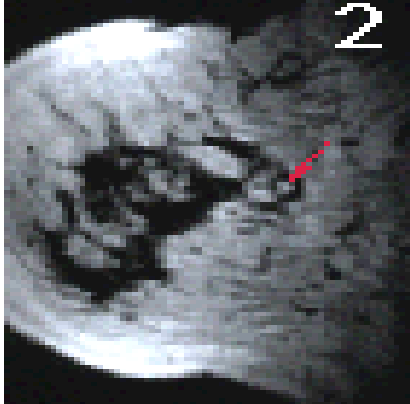
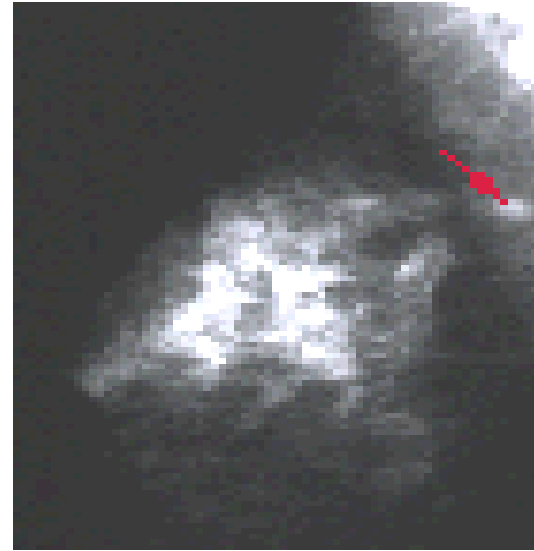
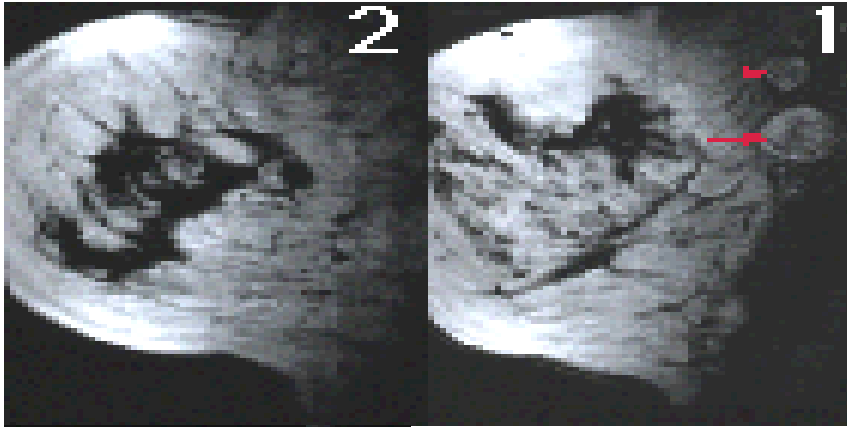
IRM CUPE SAGITALE NATIV ȘI CU SDC
PRECOCE,

DIAGNOSTIC ?

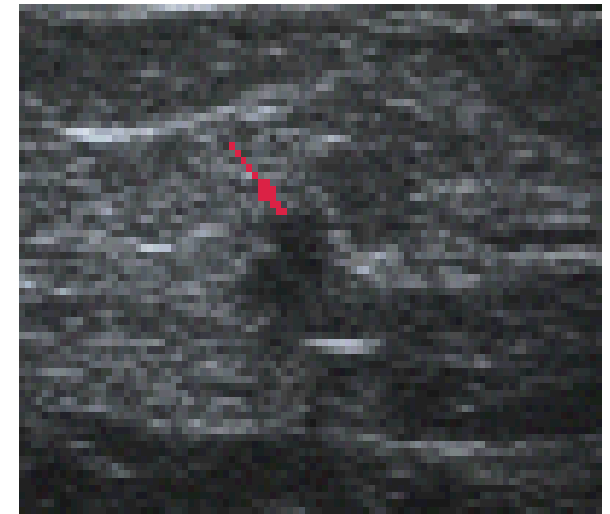
CARCINOM DUCTAL INFILTRATIV MULTICENTRIC
COD 3/5



51 DE ANI, ADENOPATIE CU CELULE DE CANCER MAMAR



IRM CUPE SAGITALE
NATIV ȘI CU SDC PRECOCE,

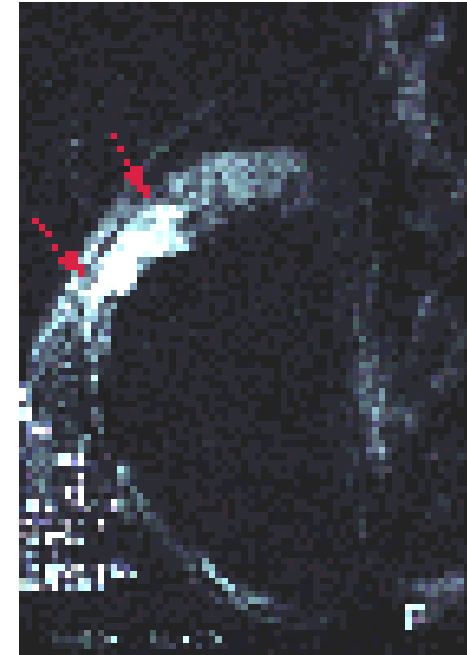
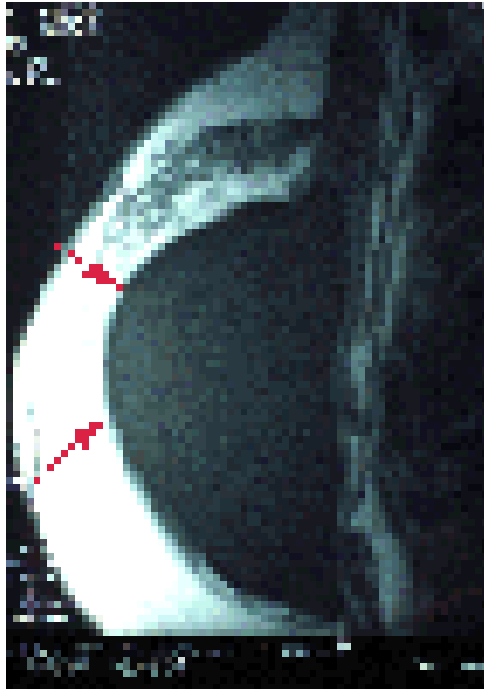


DIAGNOSTIC ?

PRIMA MAMOGRAFIE NORMALA
CARCINOM DUCTAL INFILTRATIV
COD 3/5



53 DE ANI, OPERATĂ CU CCI CU PROTEZĂ ȘI LAMBOU MUSCULAR

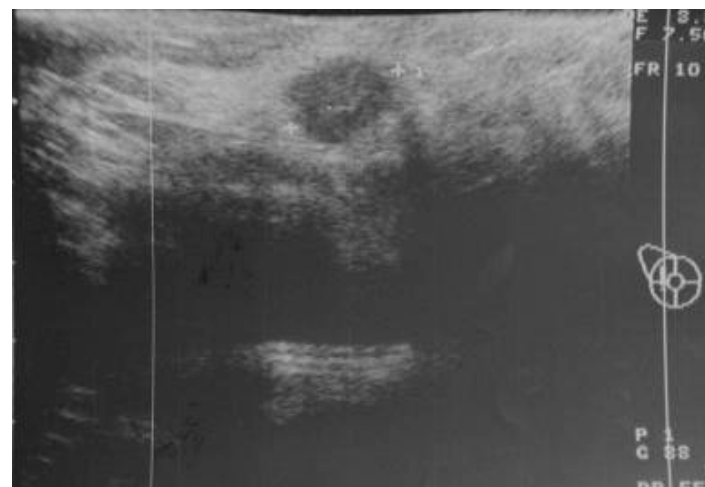
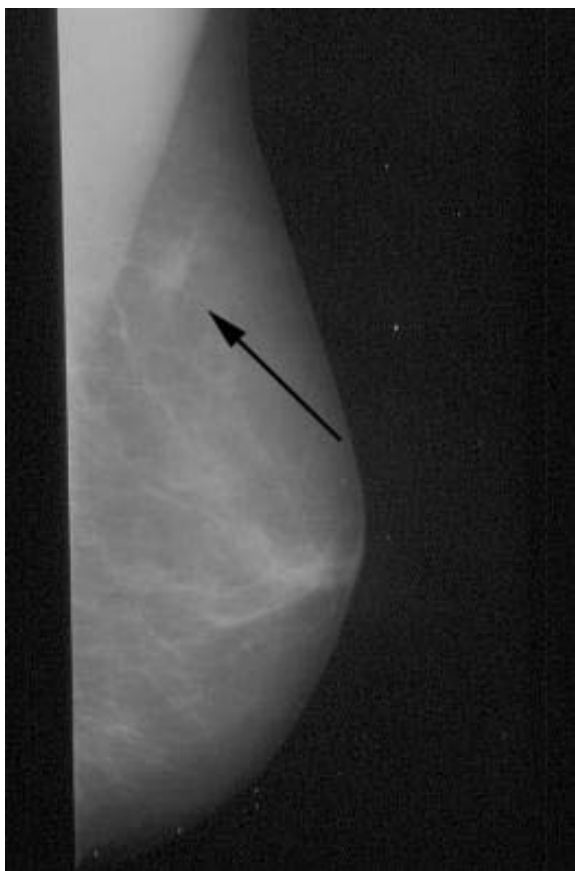


IRM CUPĂ SAGITALĂ NATIV ȘI CU SDC PRECOCE CU SUBSTRAȚIE DE GRĂSIME

DIAGNOSTIC ? RECIDIVĂ TUMORALĂ



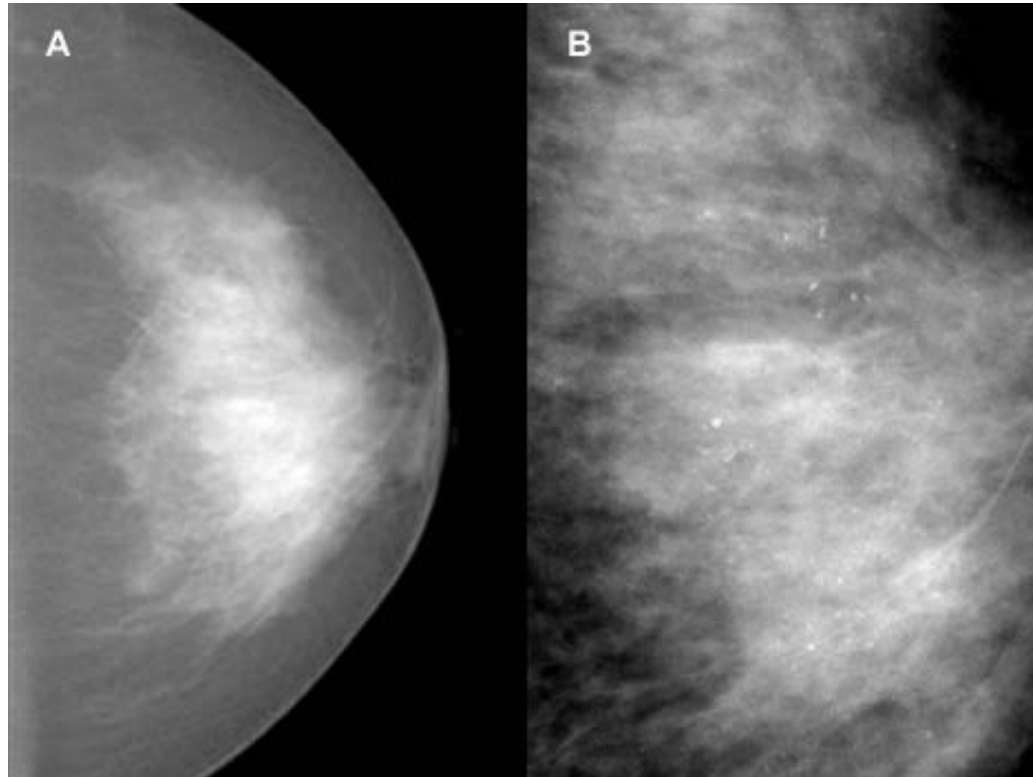
51 DE ANI, CONTROL PERIODIC



DIAGNOSTIC ? CCI, COD 1/5



54 ANI, THS, SÂN DENS ȘI DUR

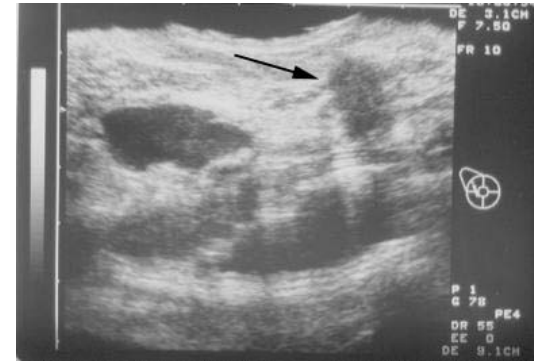
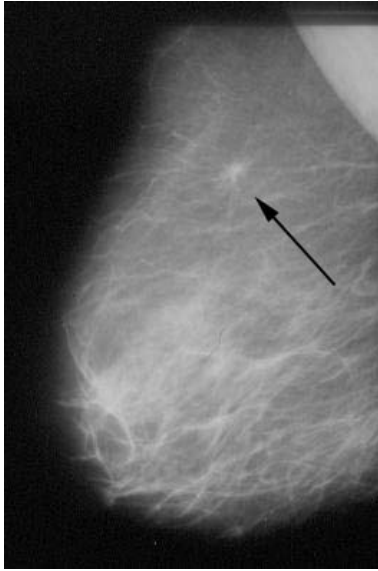


DIAGNOSTIC ?

CARCINOM DUCTAL EXTENSIV, COD 3/5



41 ANI, ÎN CONTROL PENTRU LEZIUNI BENIGNE

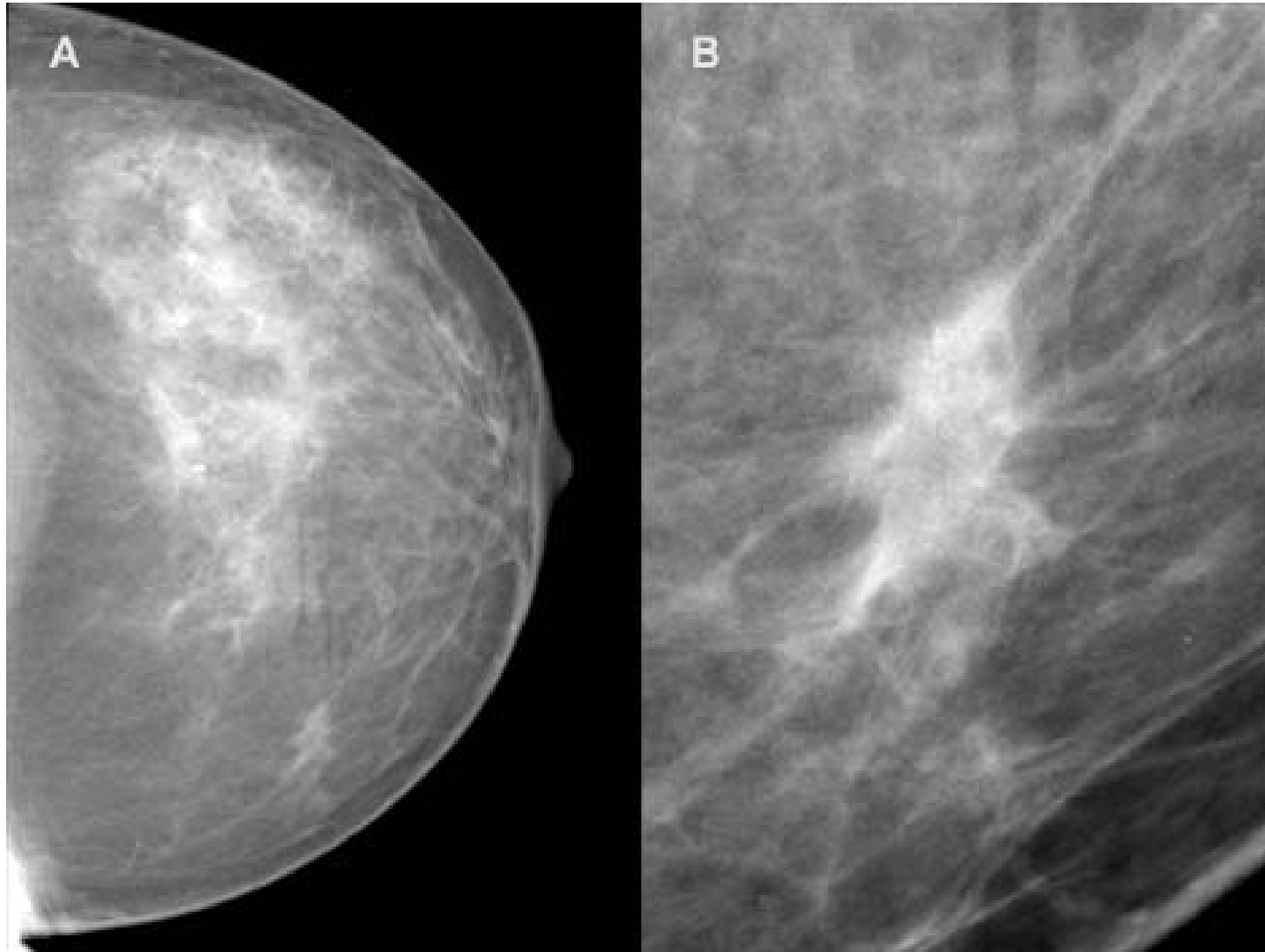


DIAGNOSTIC ?

CCI, COD 2/5



46 ANI, ÎN CONTROL DUPĂ CCIS OPERAT DE 5 ANI



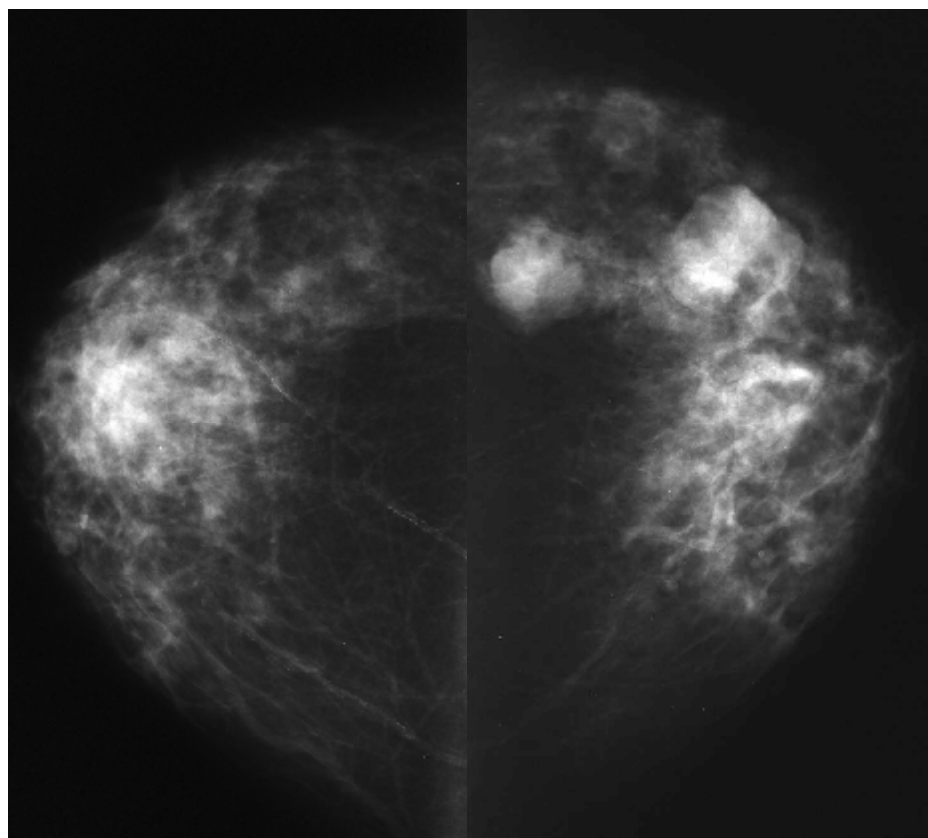
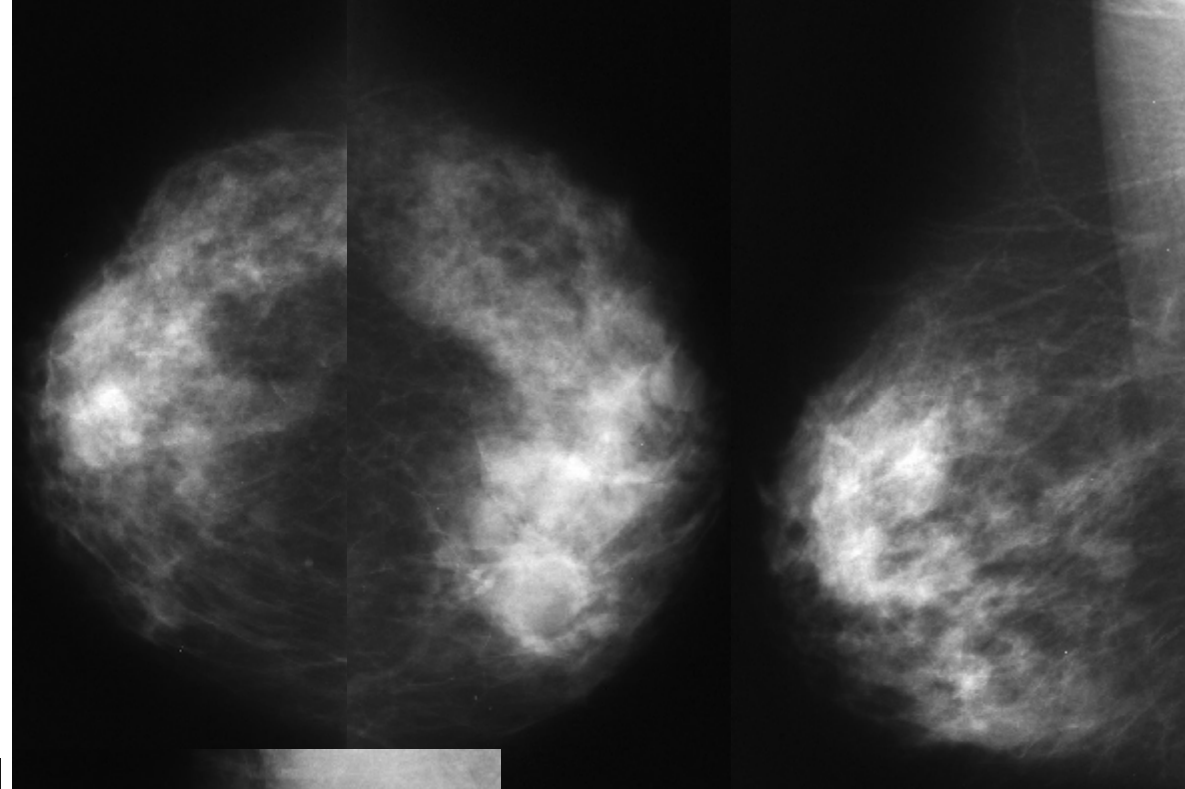
DIAGNOSTIC ?

RECIDIVĂ, COD 2/5

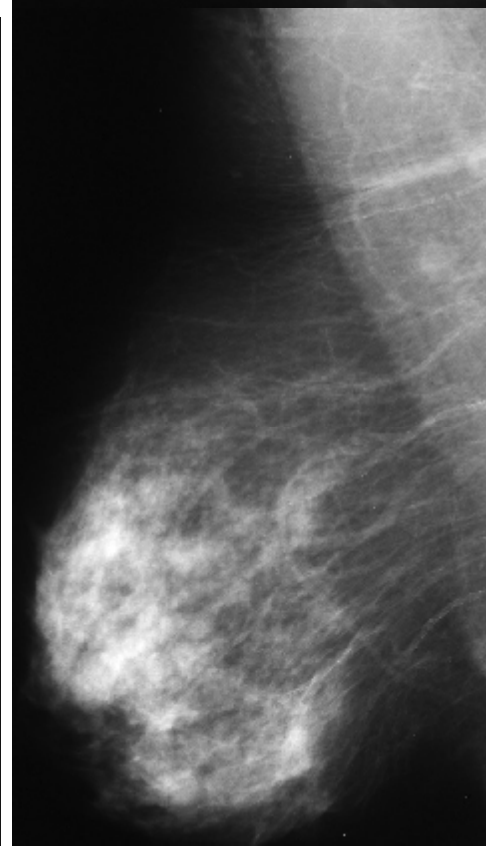


41ANI, ÎN AHC MAMA
CU CCI LA 46 ANI

MAMOGRAFII ÎN
1998



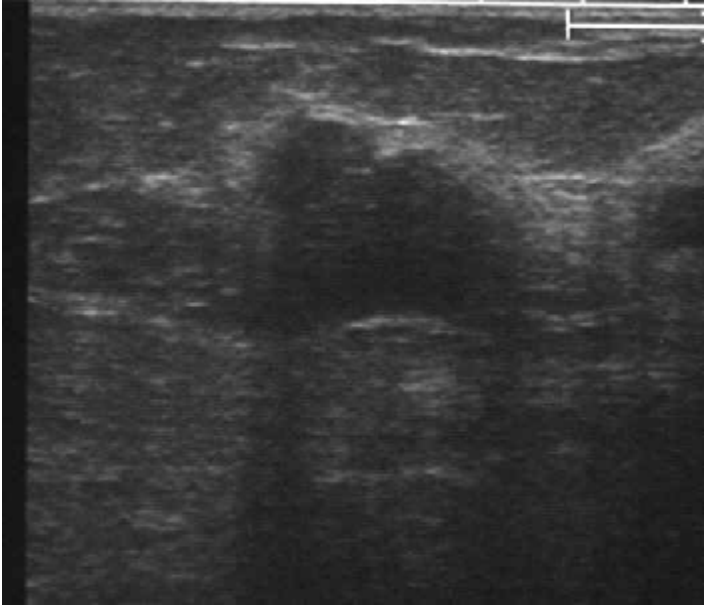
MAMOGRAFII ÎN
1999



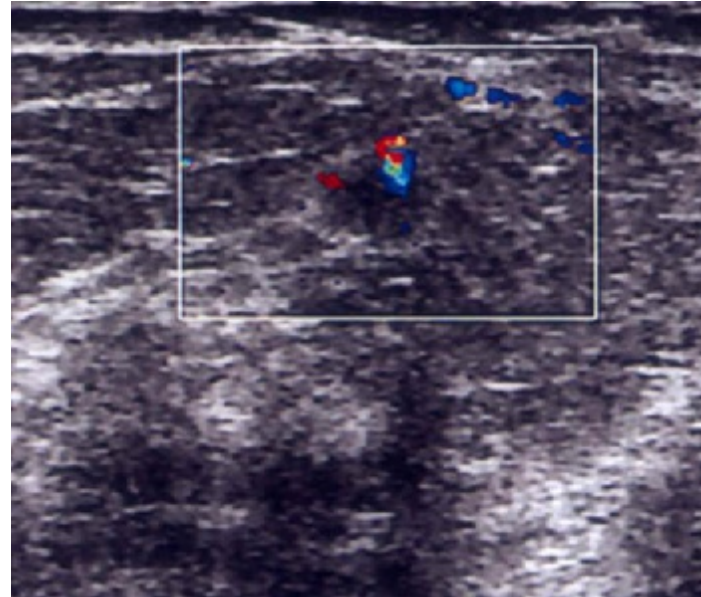
CDI, COD 3/5



41 ANI, AHC - MAMA CCI LA 46 ANI



SAN DR



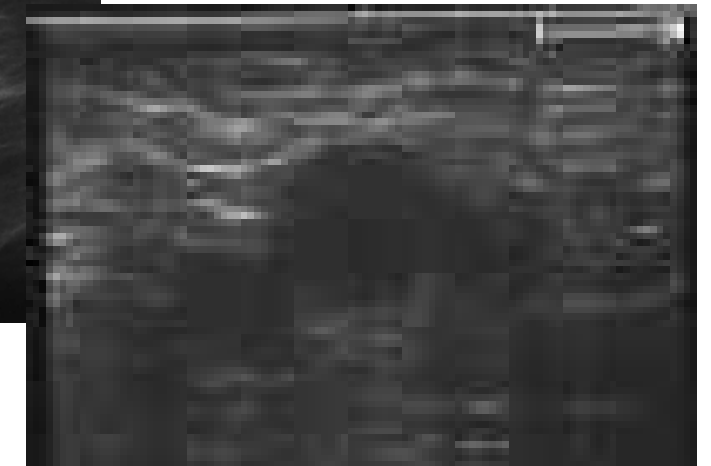
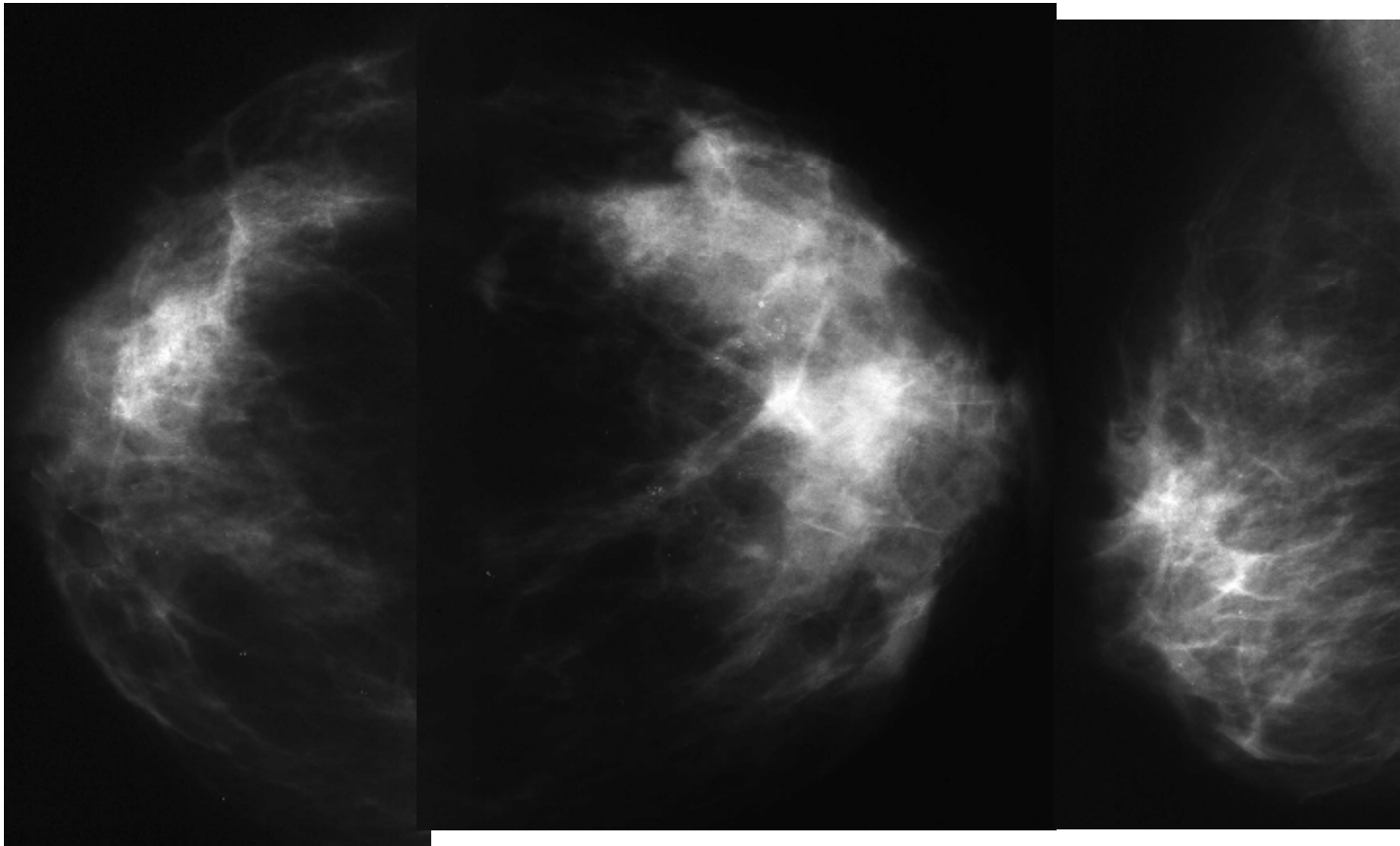
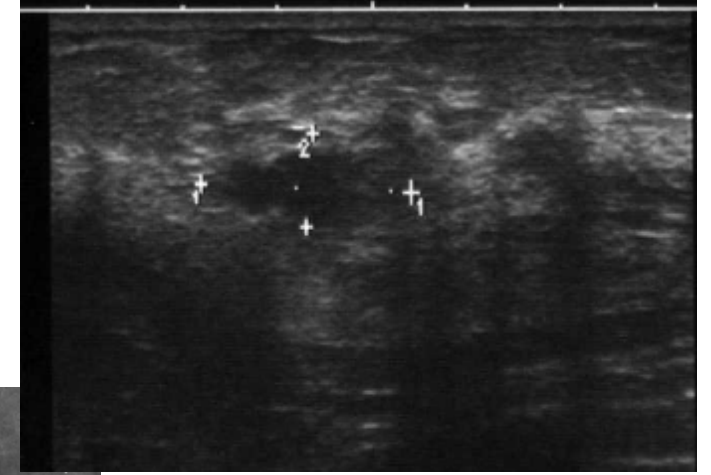
SAN STG

DIAGNOSTIC ?

CCI MULTIFOCAL, COD 3/5



41 ANI, AHC - MAMA CCI
LA PREMENOPAUZĂ



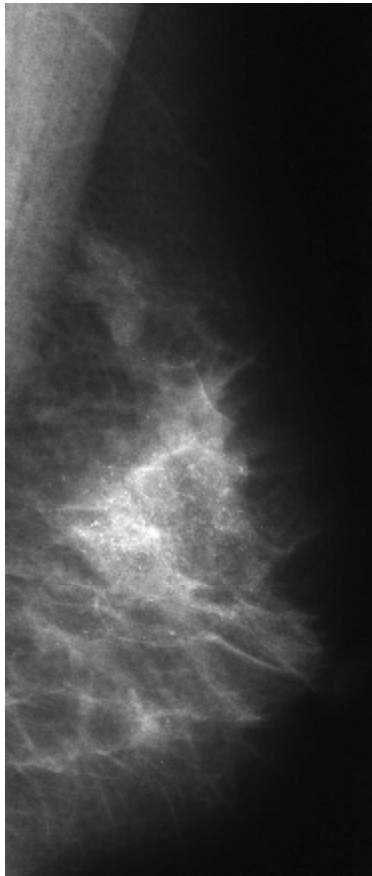
DIAGNOSTIC ?

CCI MULTIFOCAL, CU ADENOPATIE
SECUNDARĂ DR. COD 2/5

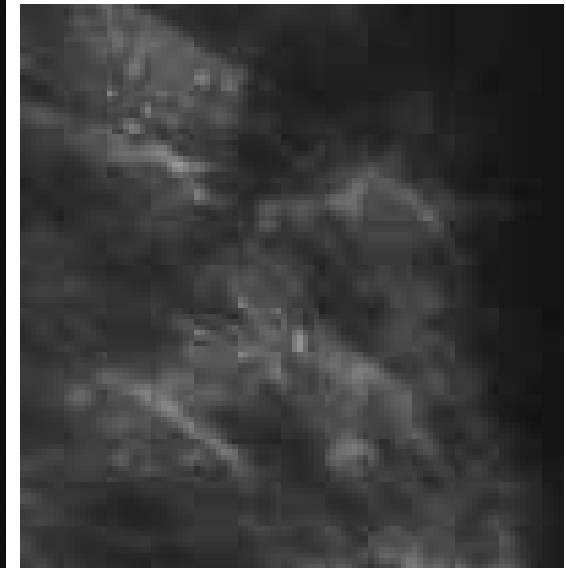
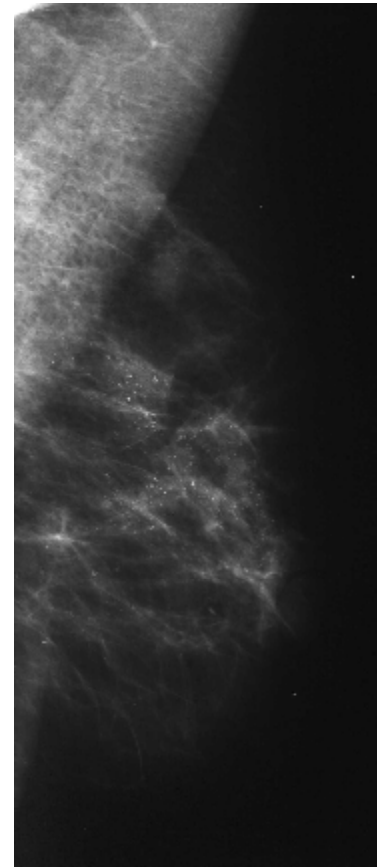


47 ANI, ASIMPTOMATICĂ, FĂRĂ AHC

1997



2000

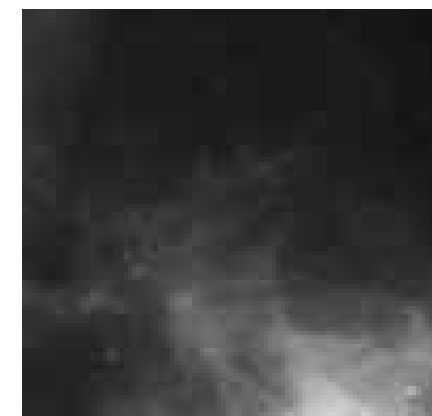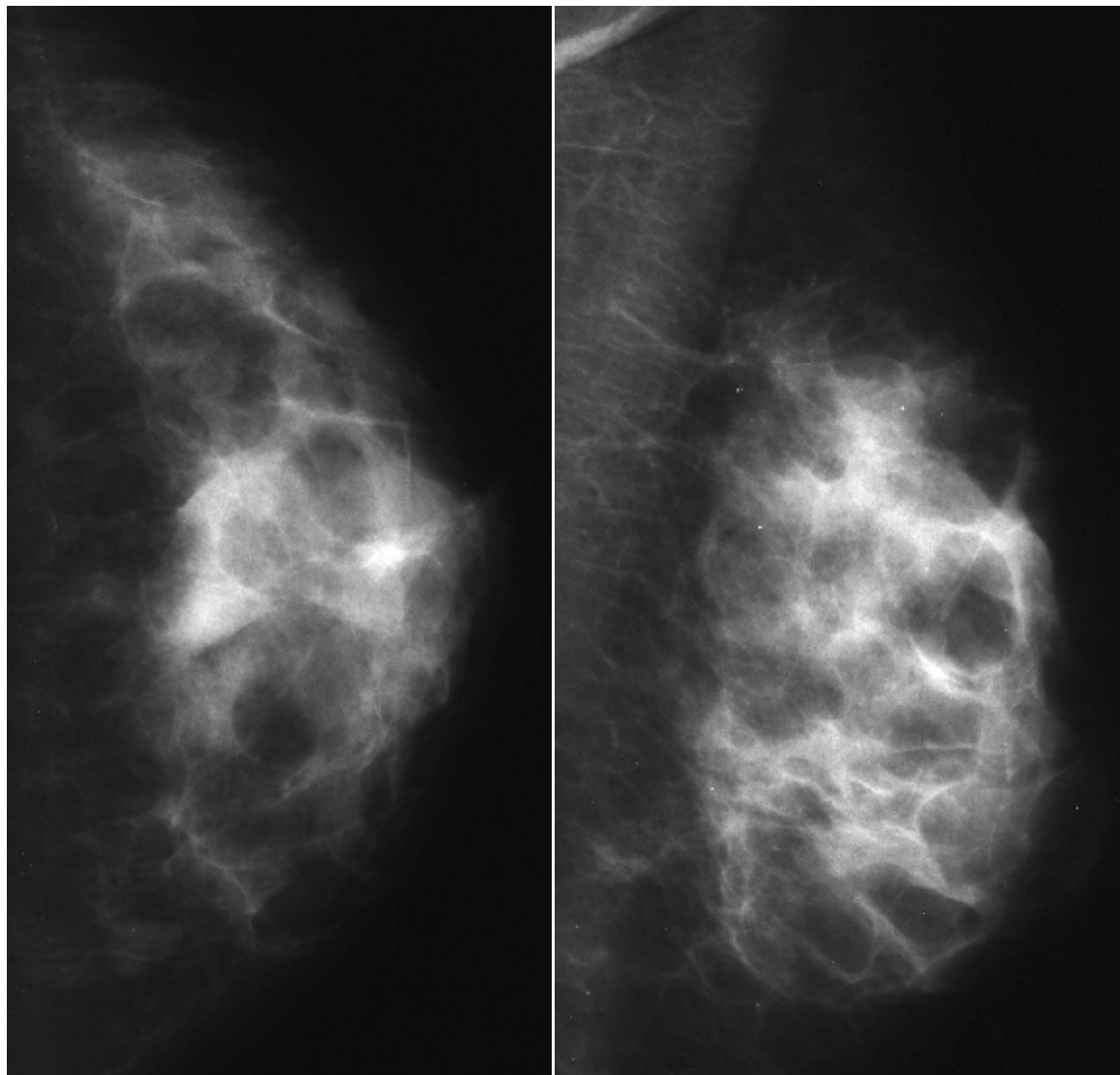


DIAGNOSTIC ?

MASTOZĂ FIBROCHISTICĂ
COD 2/2



45 ANI, ASIMPTOMATICĂ, AHC- MAMA CCI LA 56 ANI

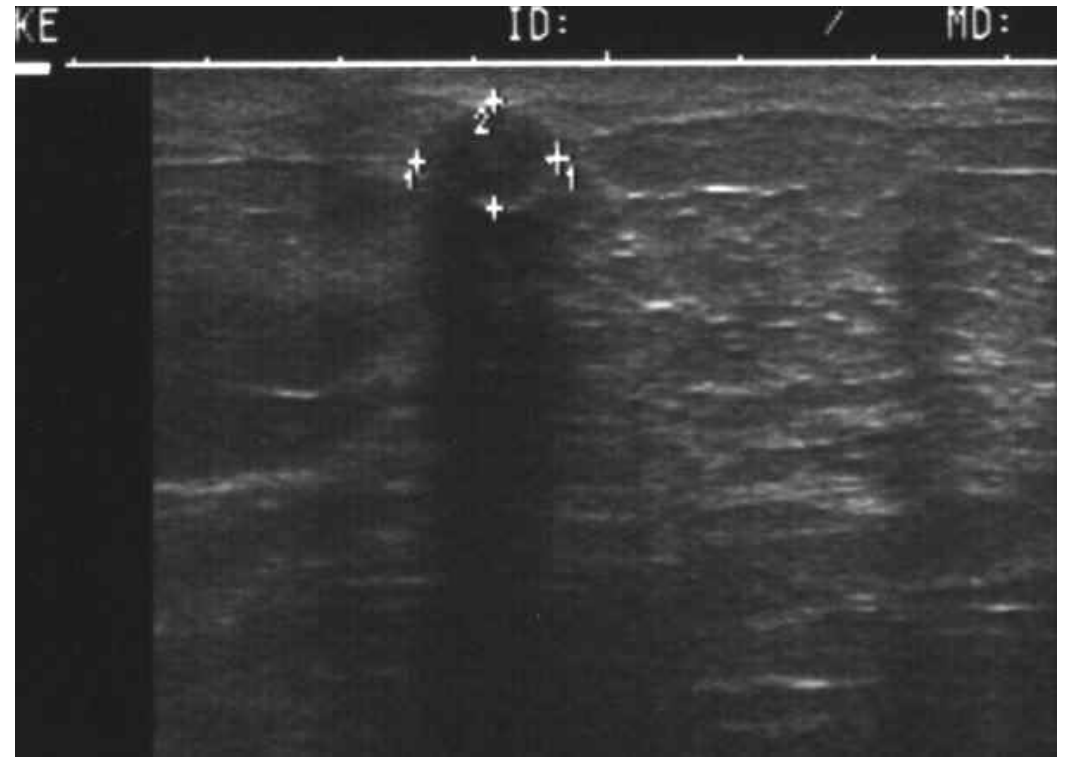
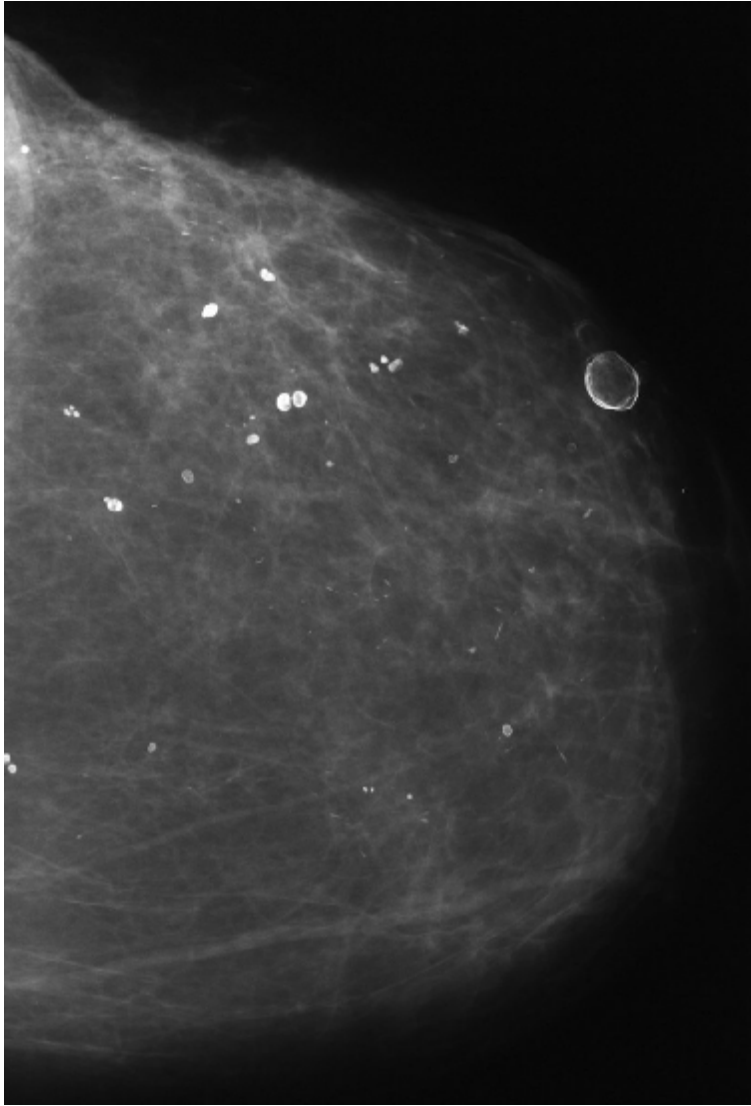


DIAGNOSTIC ?

CCIS, COD 3/5



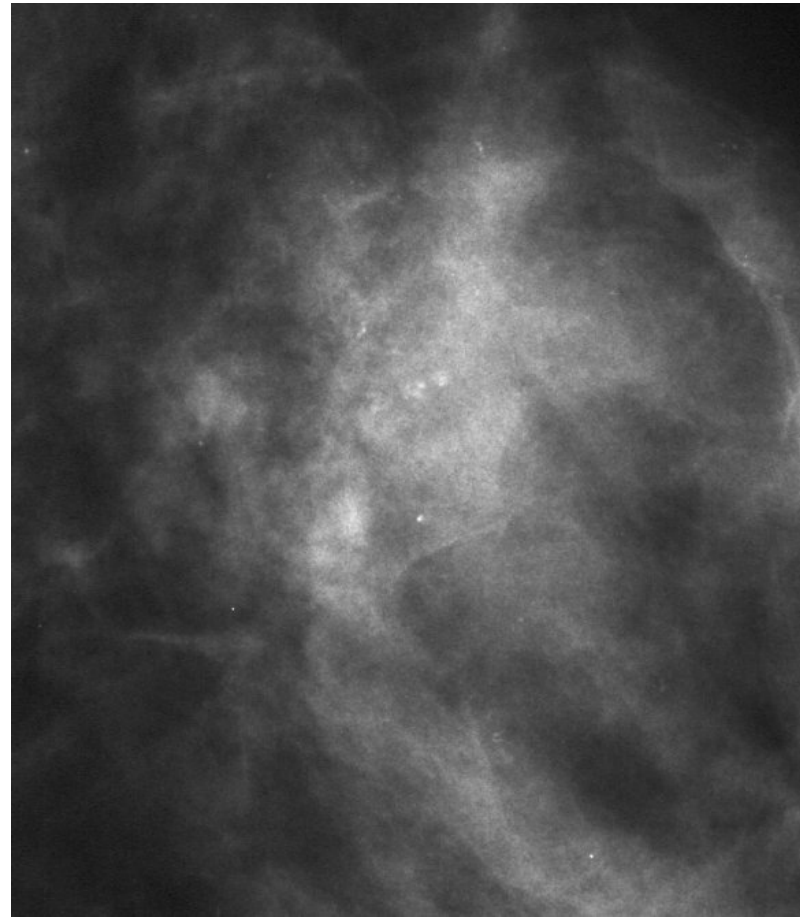
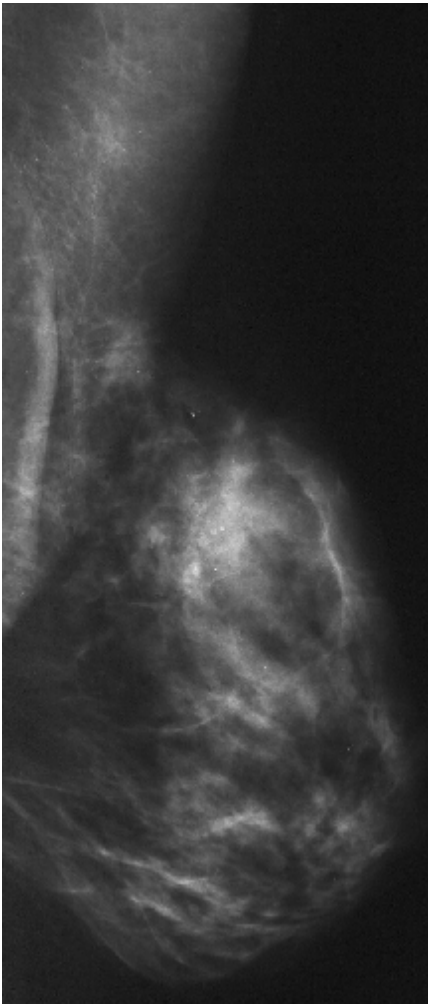
64 ANI, ASIMPTOMATICĂ, AHC- VARĂ CU CCI LA 51 ANI



DIAGNOSTIC ? CITOSTEATONECROZĂ
MASTITĂ PLASMOCITARĂ



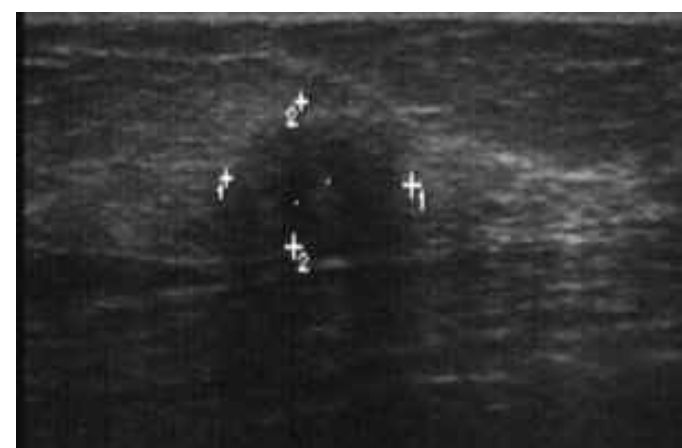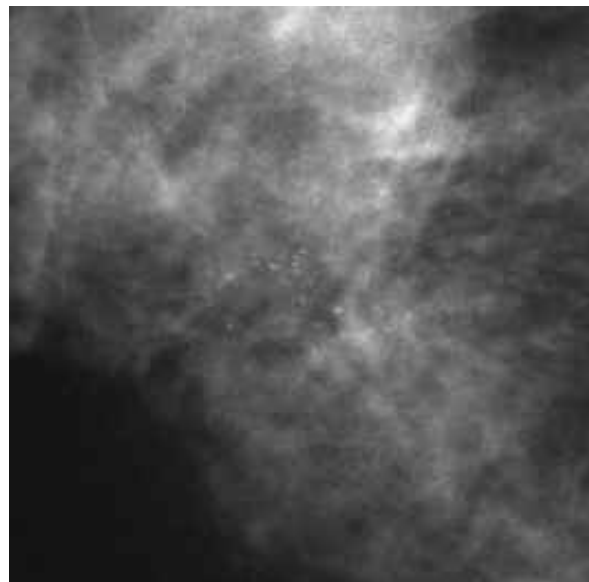
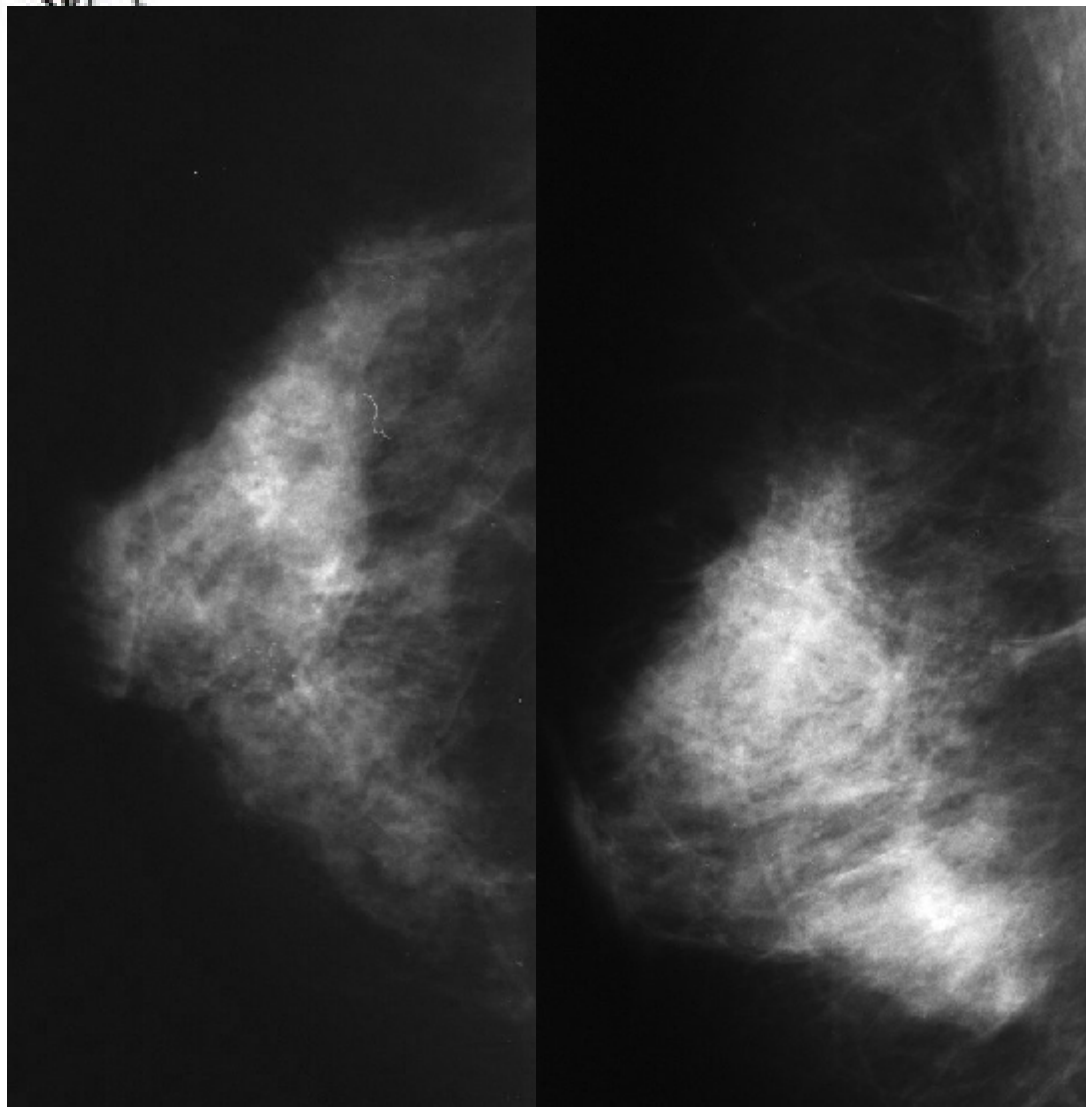
61 ANI, ASIMPTOMATICĂ



DIAGNOSTIC ? CCI, COD 2/5



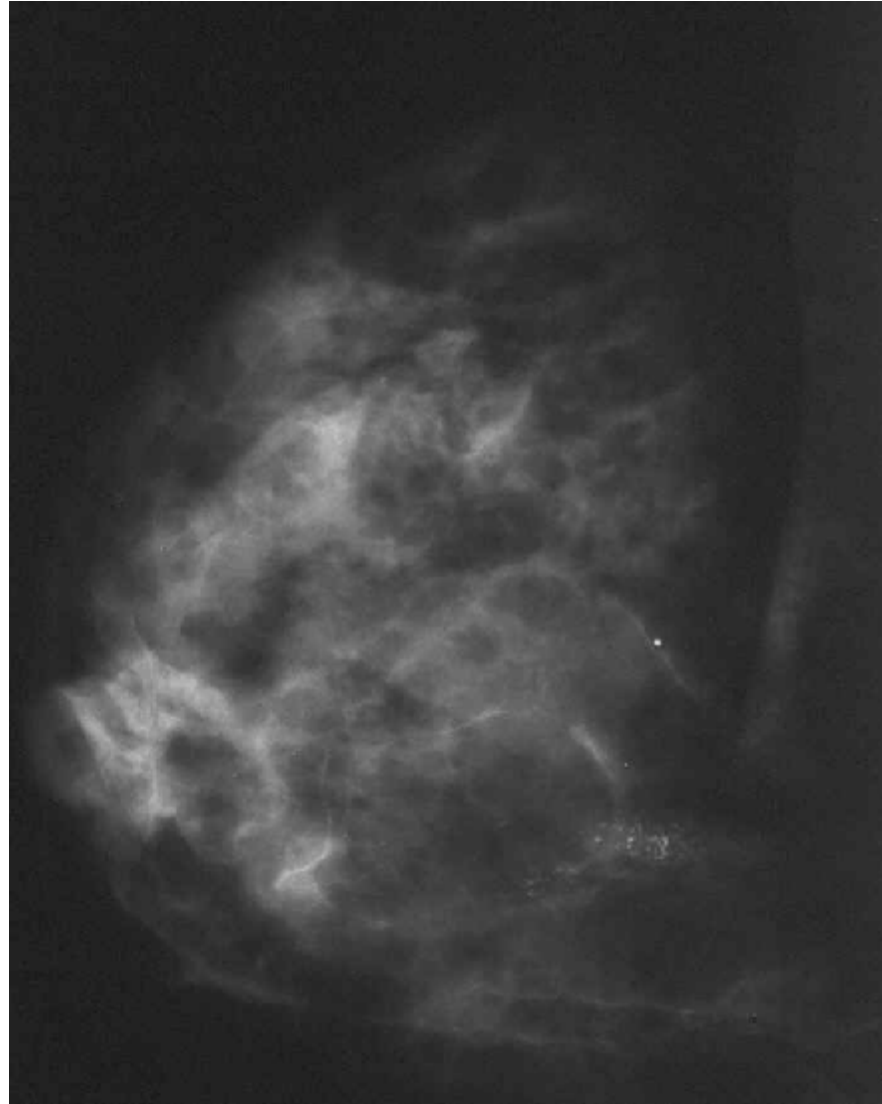
61 ANI, ASIMPTOMATICĂ



DIAGNOSTIC ? CCI, COD 3/5



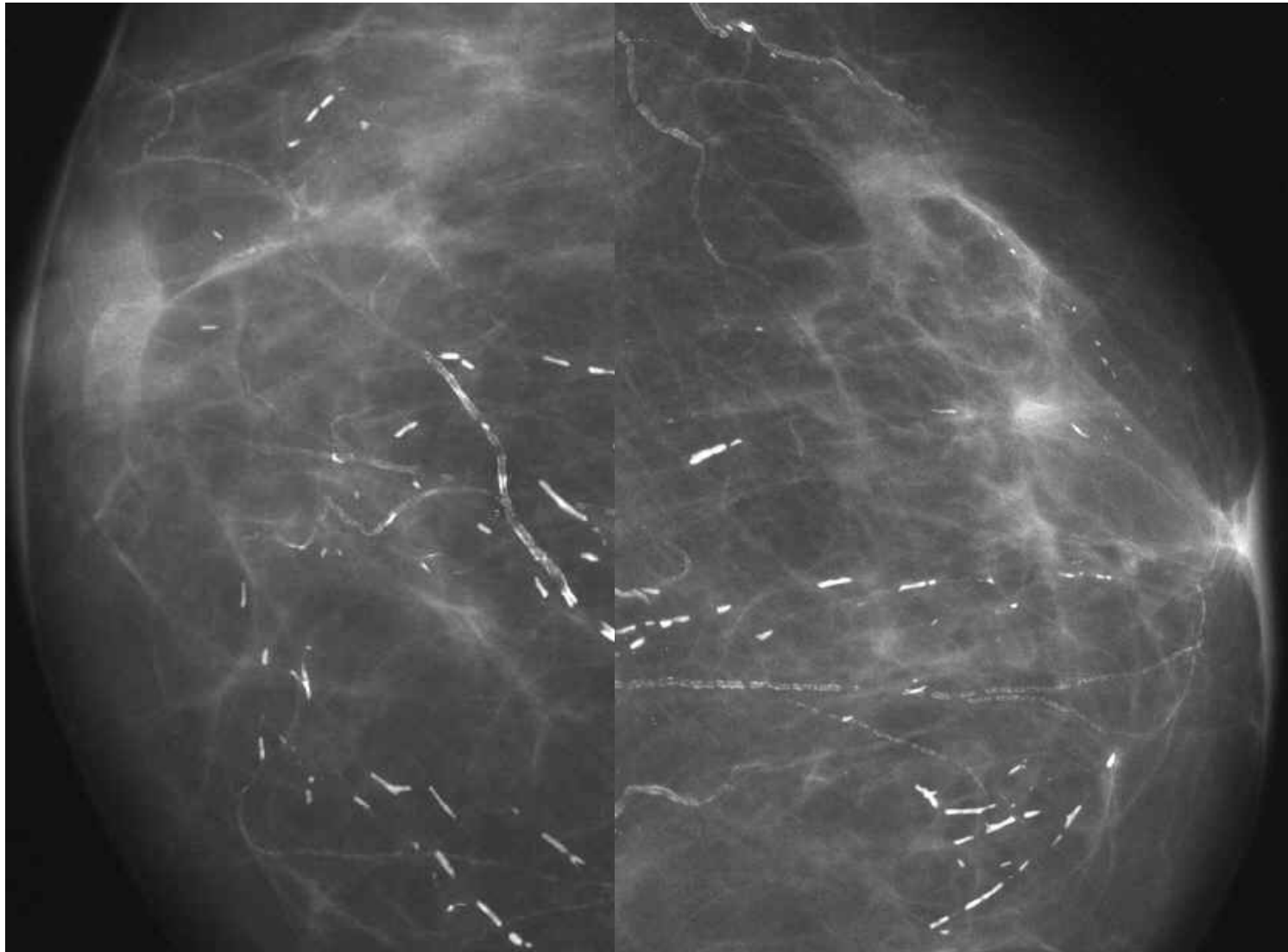
62 ANI, ASIMPTOMATICĂ



DIAGNOSTIC ? CCI, COD 2/5



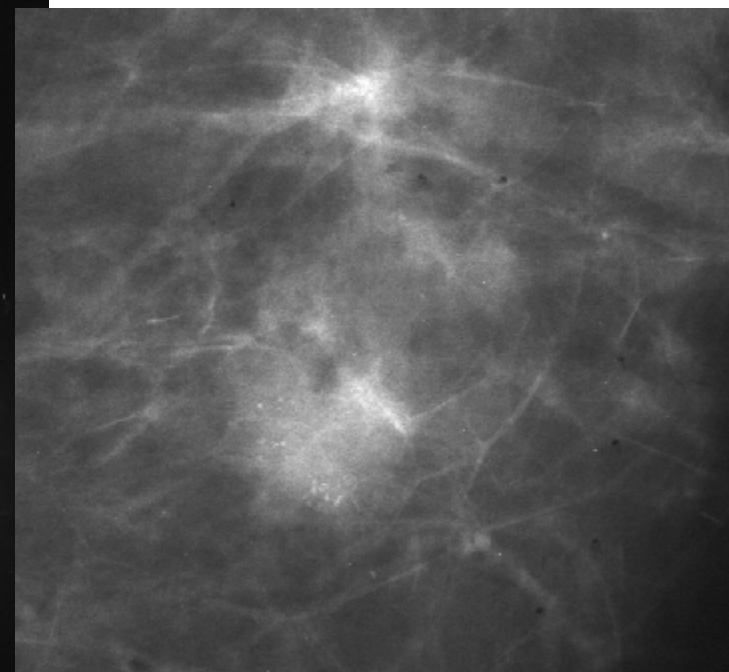
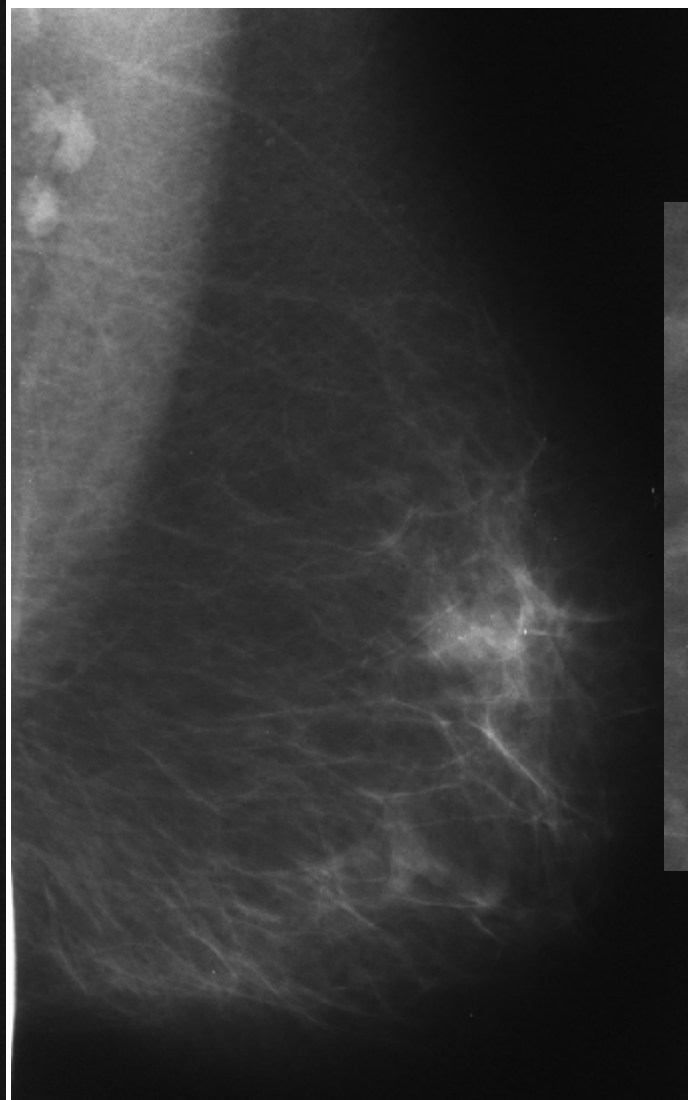
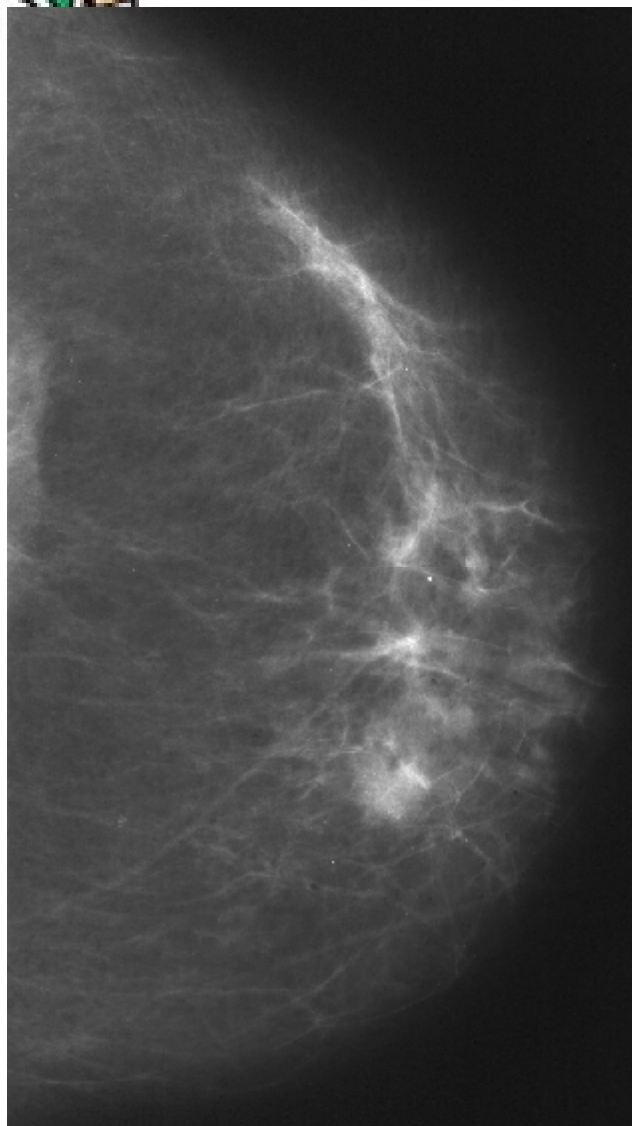
62 ANI, INDURARE RETROAREOLARĂ



DIAGNOSTIC ? COMEDO CARCINOM DR, MASTITĂ
PLASMOCITARĂ BILAT., COD 1/5; 1/2



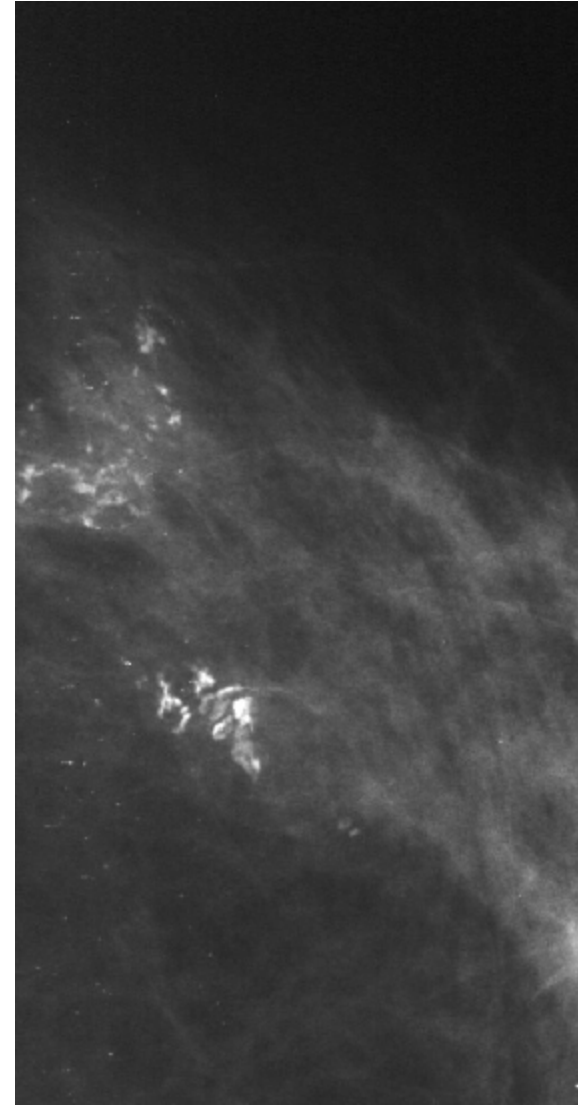
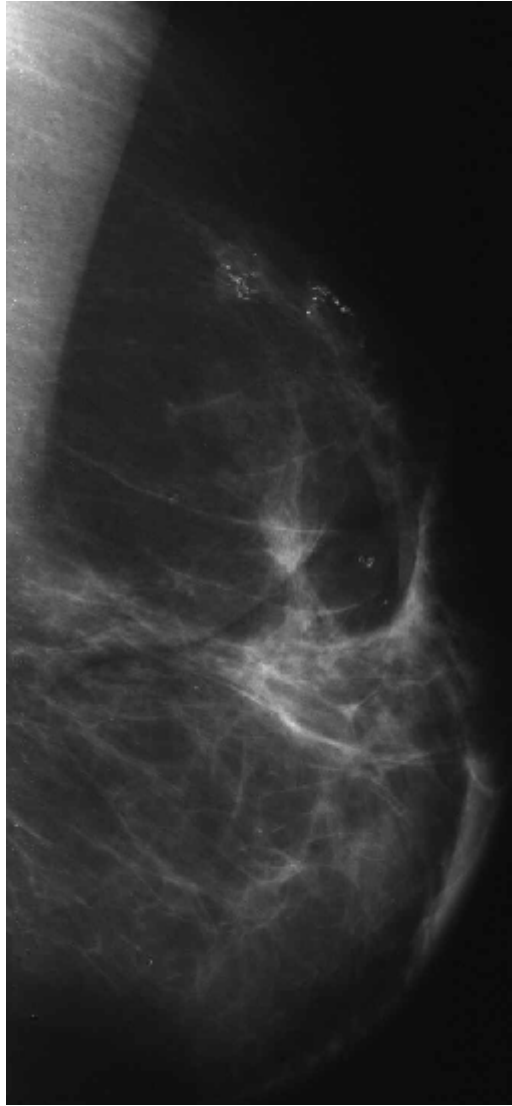
69 ANI, ASIMPTOMATICĂ - 1999



DIAGNOSTIC ? CCIS, COD 1/5;



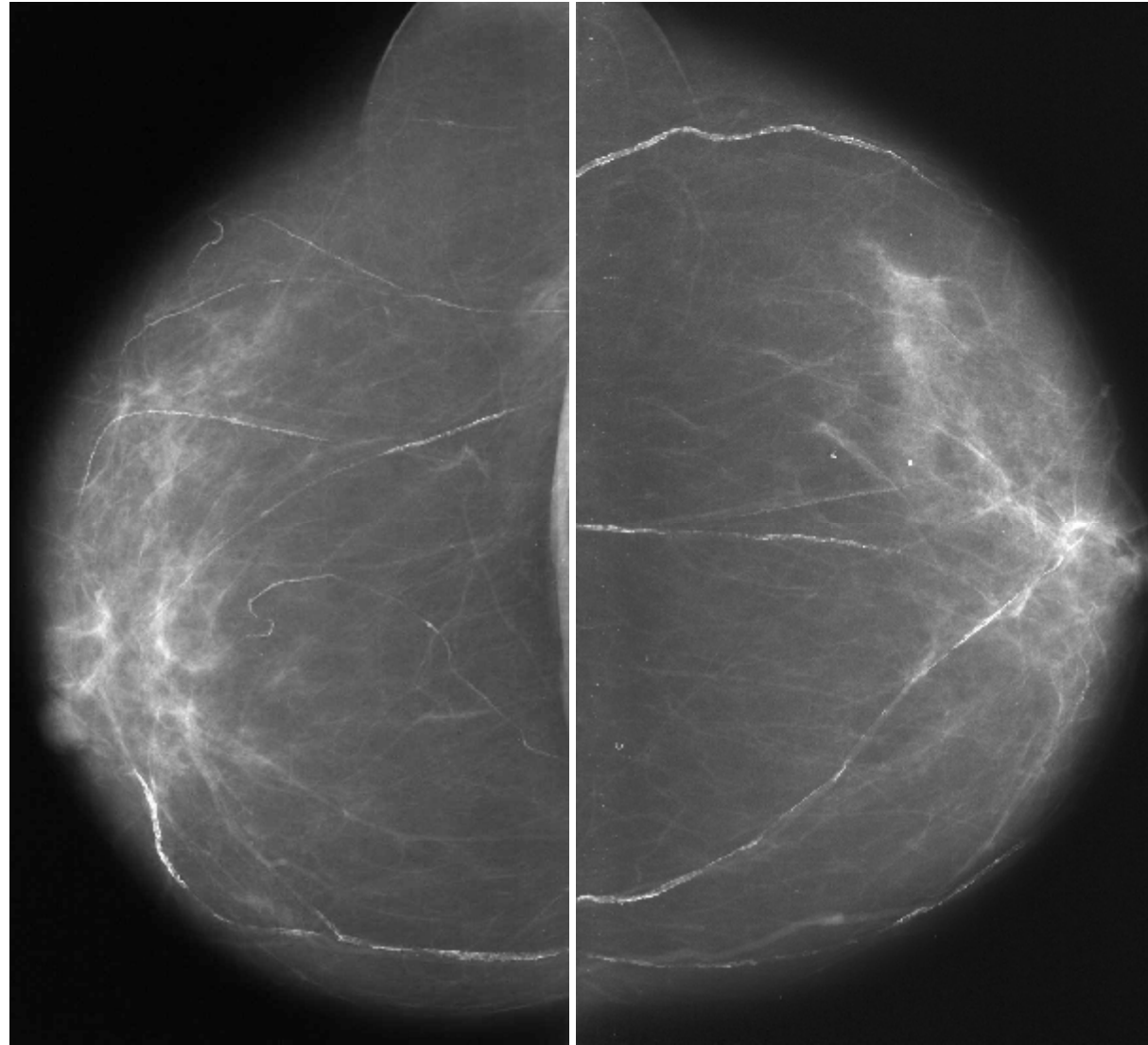
72 ANI, ACEEAȘI PACIENTĂ - 2002



DIAGNOSTIC ? CITOSTEATONECROZĂ
CALCIFICĂRI CICATRICIALE, COD 2/2;



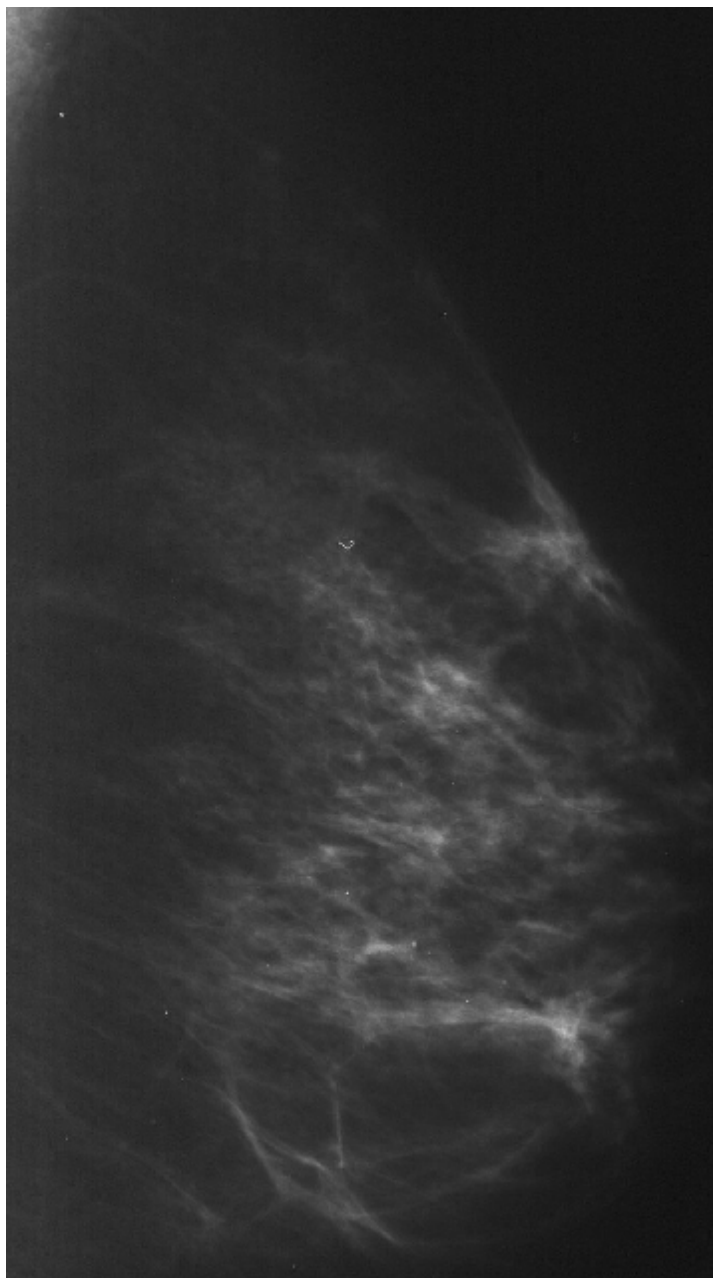
72 ANI, 8 ANI THS, 12 ANI DE DIALIZĂ



DIAGNOSTIC ? CALCIFICĂRI ARTERIALE, COD 2/2;



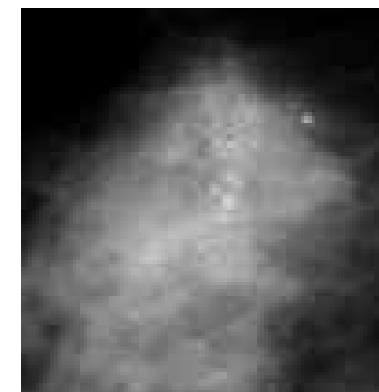
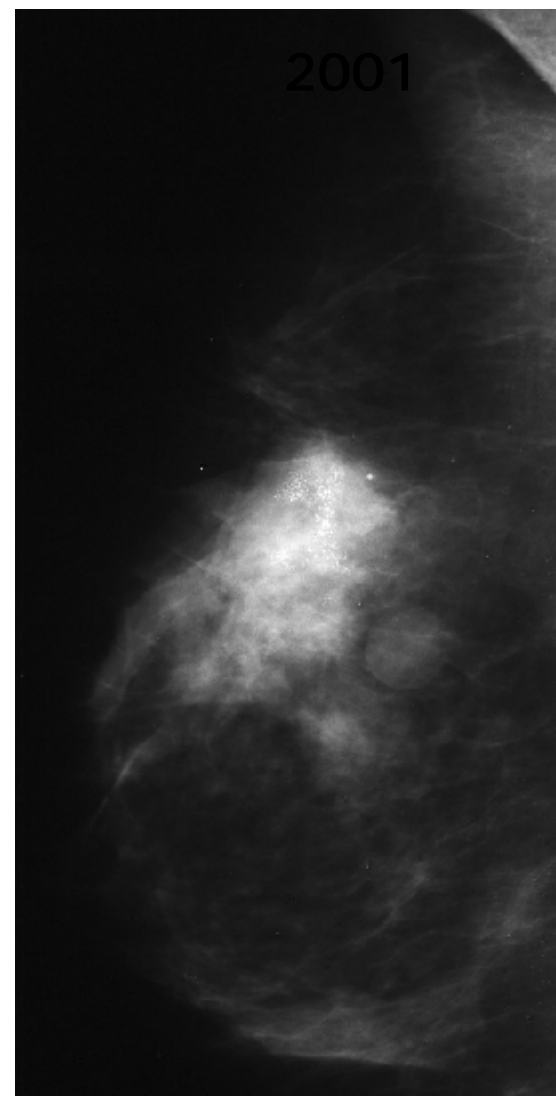
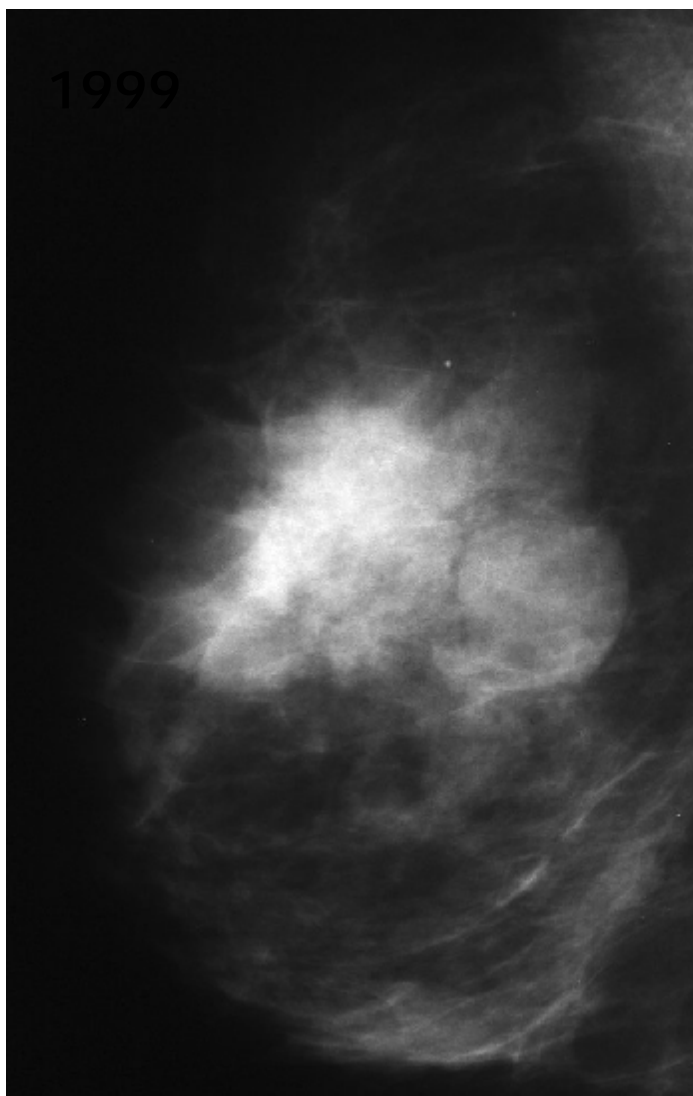
67 ANI, BUNICA CU CANCER ÎN POST MENOPAUZĂ



DIAGNOSTIC ? CCIS, COD 2/5;



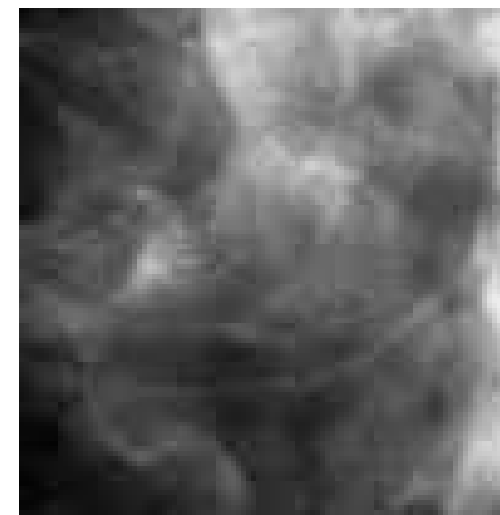
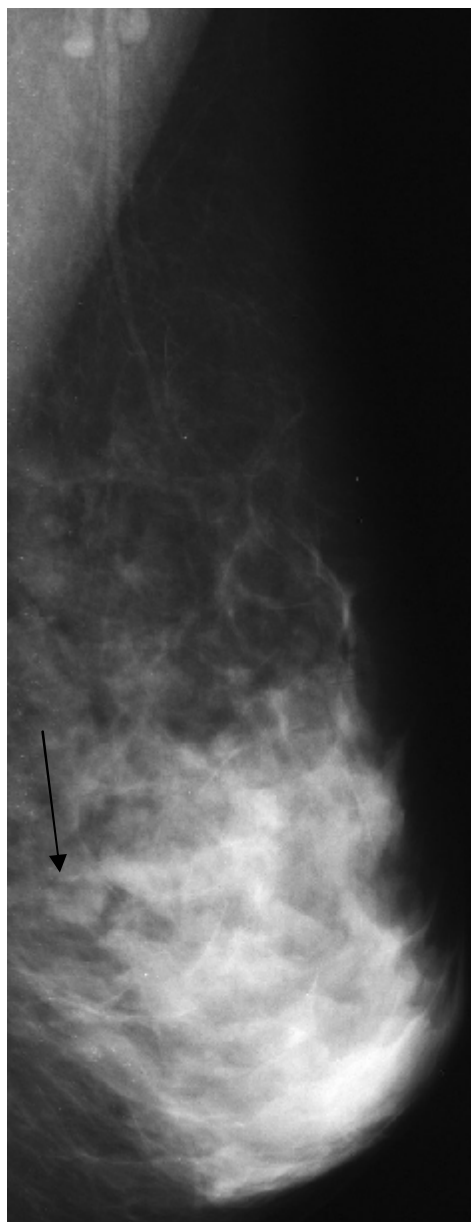
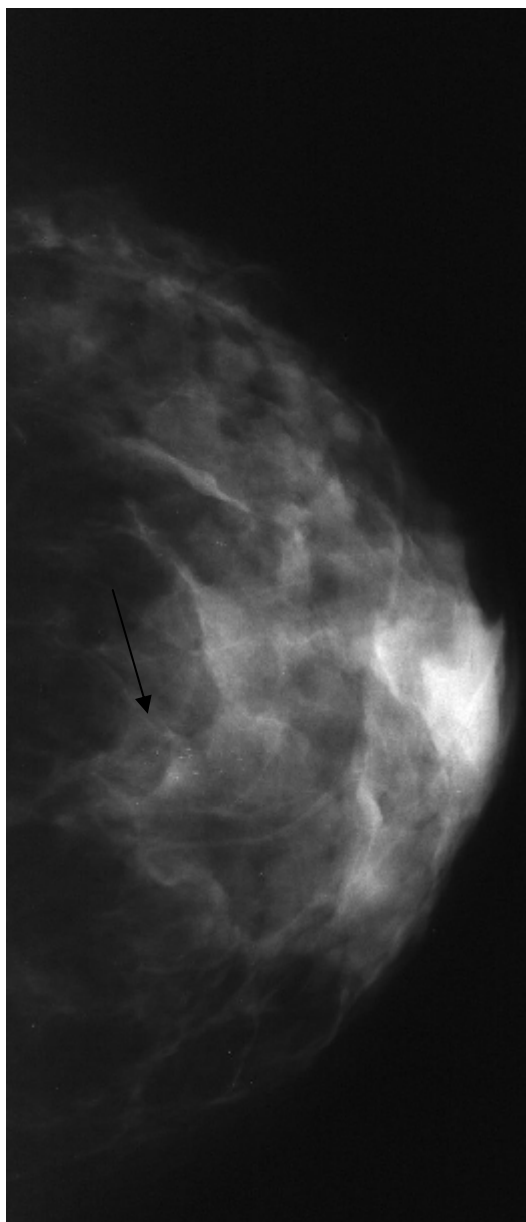
67 ANI, BUNICA CU CANCER ÎN POST MENOPAUZĂ



DIAGNOSTIC ? 1) MASTOZĂ FIBROCHISTICĂ
2) CCIS, COD 2/5;



67 ANI, BUNICA CU CANCER ÎN POST MENOPAUZĂ

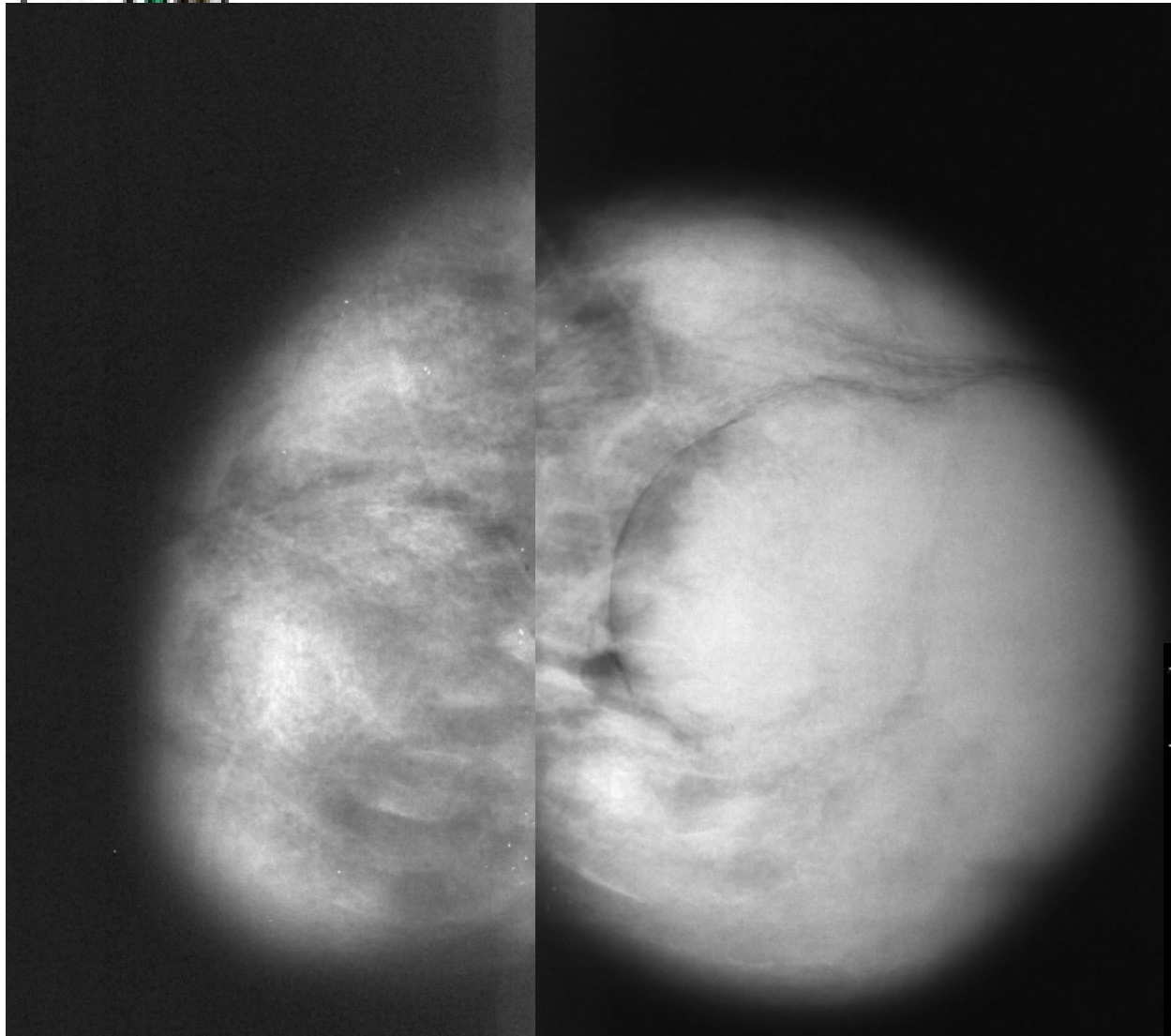


DIAGNOSTIC ?

CCIS, COD 3/5;

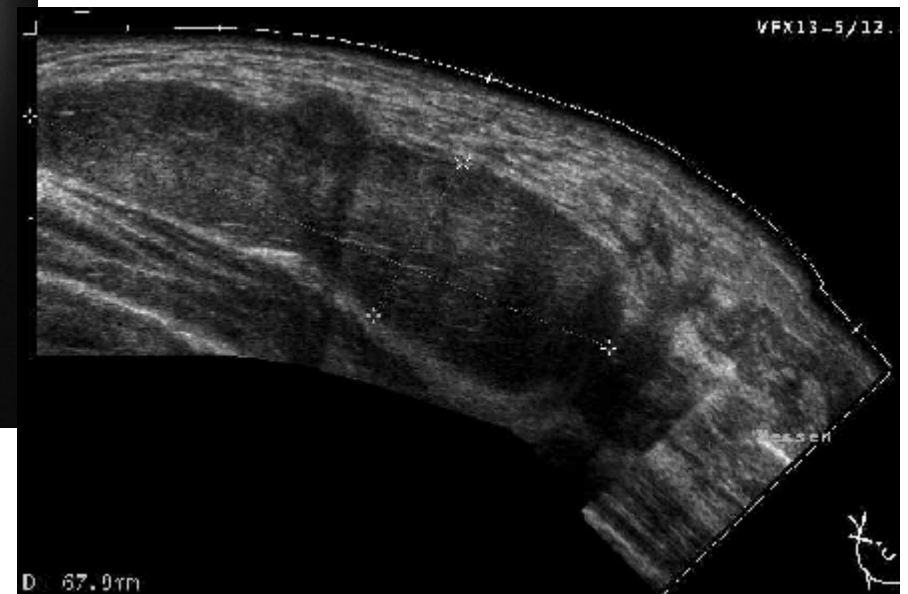

20 ANI, CREȘTERE RAPIDĂ A SÂNULUI STG.



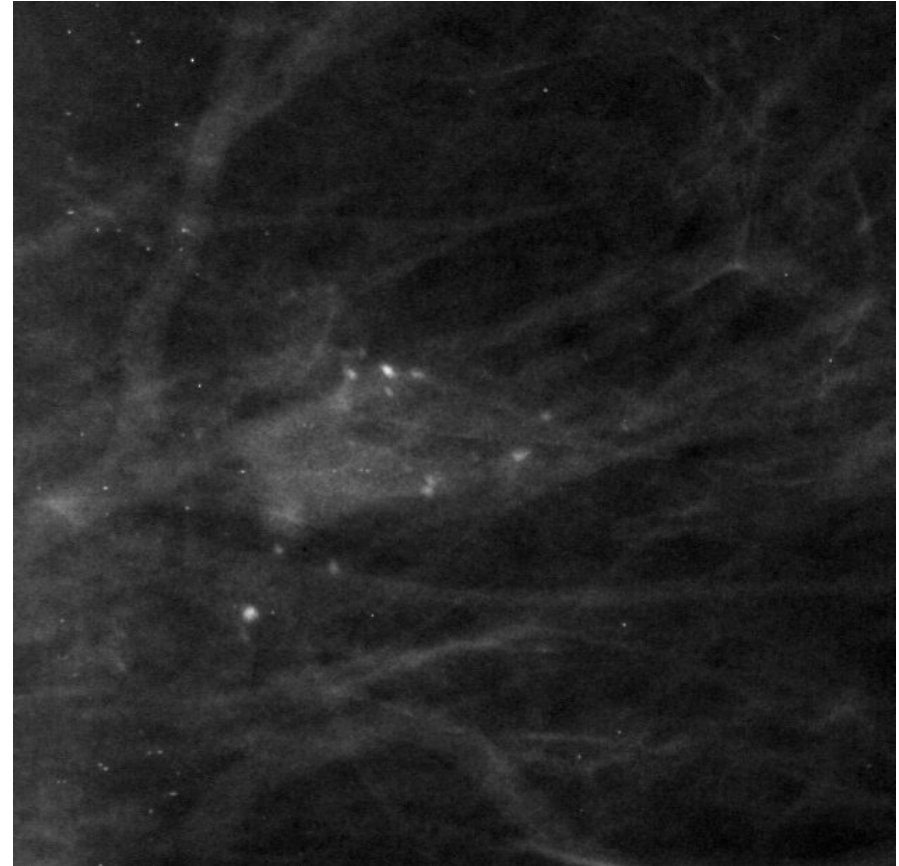
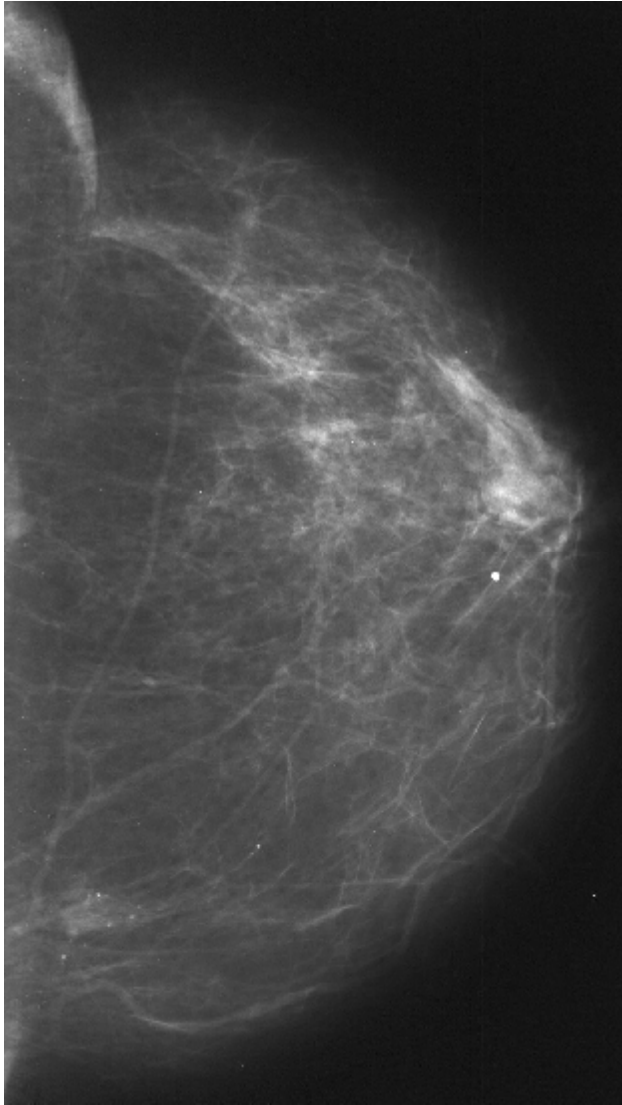
DD: TUMORĂ PHILODĂ
FIBROADENOM
COD 4/2

DIAGNOSTIC ?





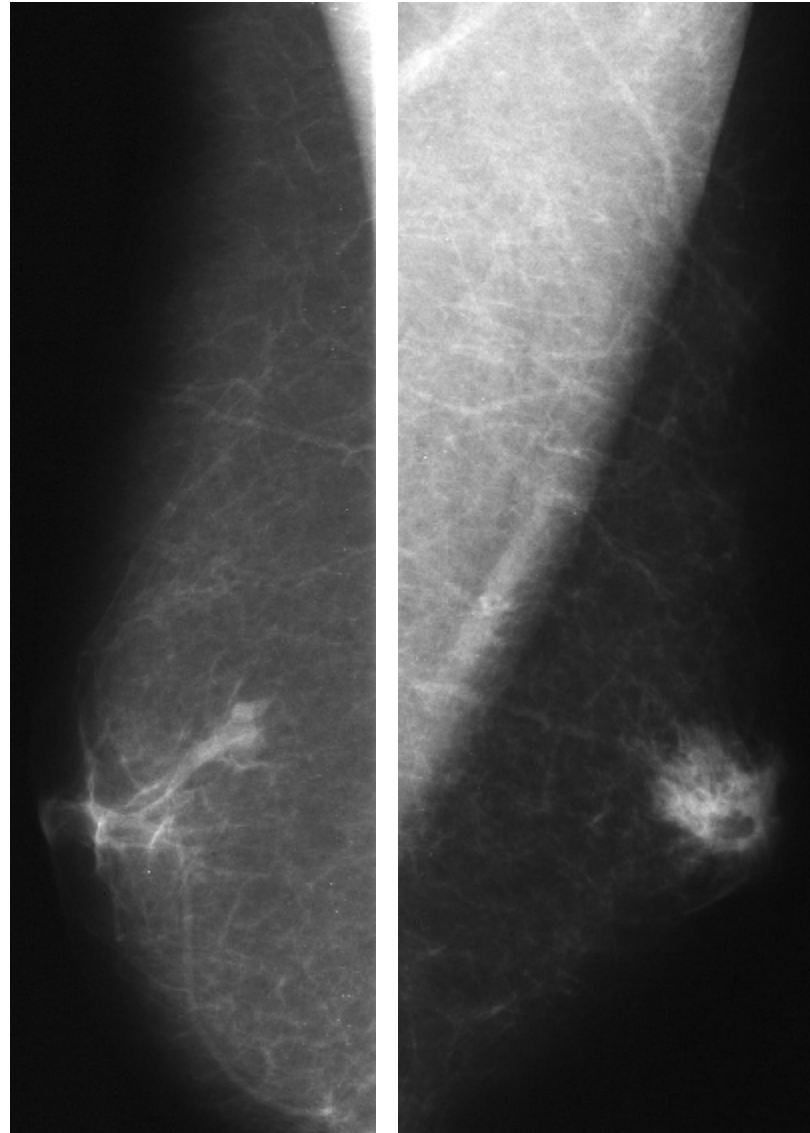
64 ANI, OPERATĂ ÎN URMĂ CU 4 ANI CU CCI, T1,N1,M0



DIAGNOSTIC ? CLIS, COD 2/5;



64 ANI, BĂRBAT, FĂRĂ HORMONOTERAPIE

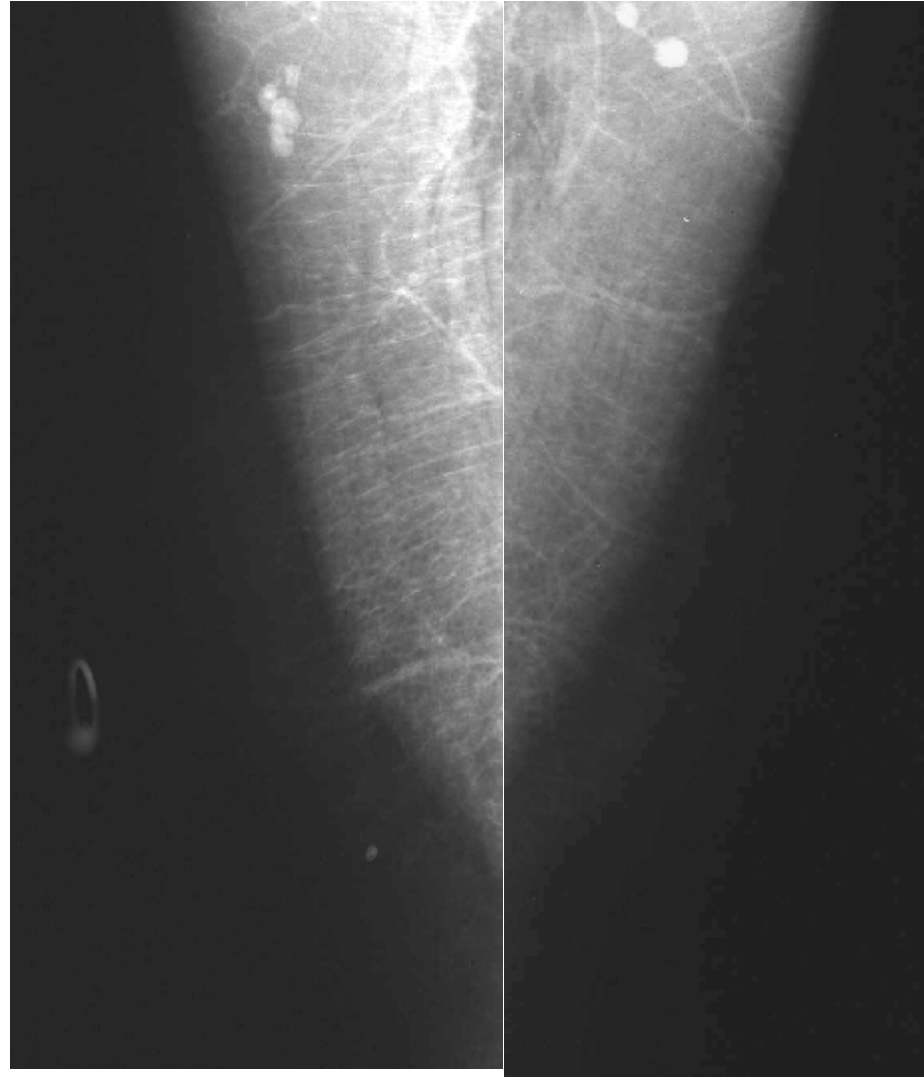

DIAGNOSTIC ?

GINECOMASTIE



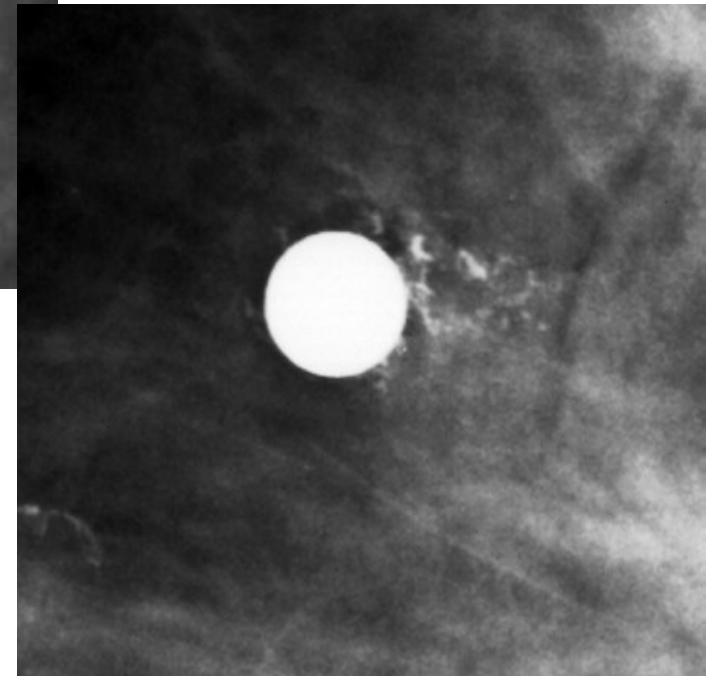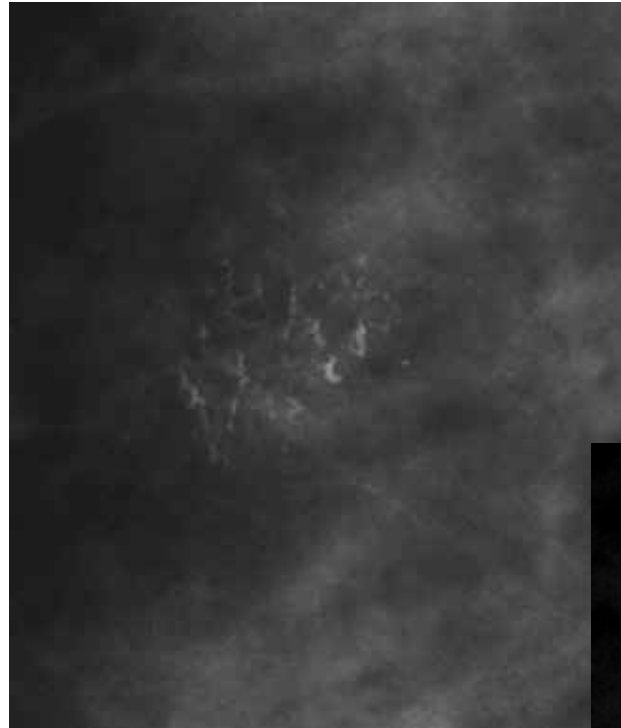
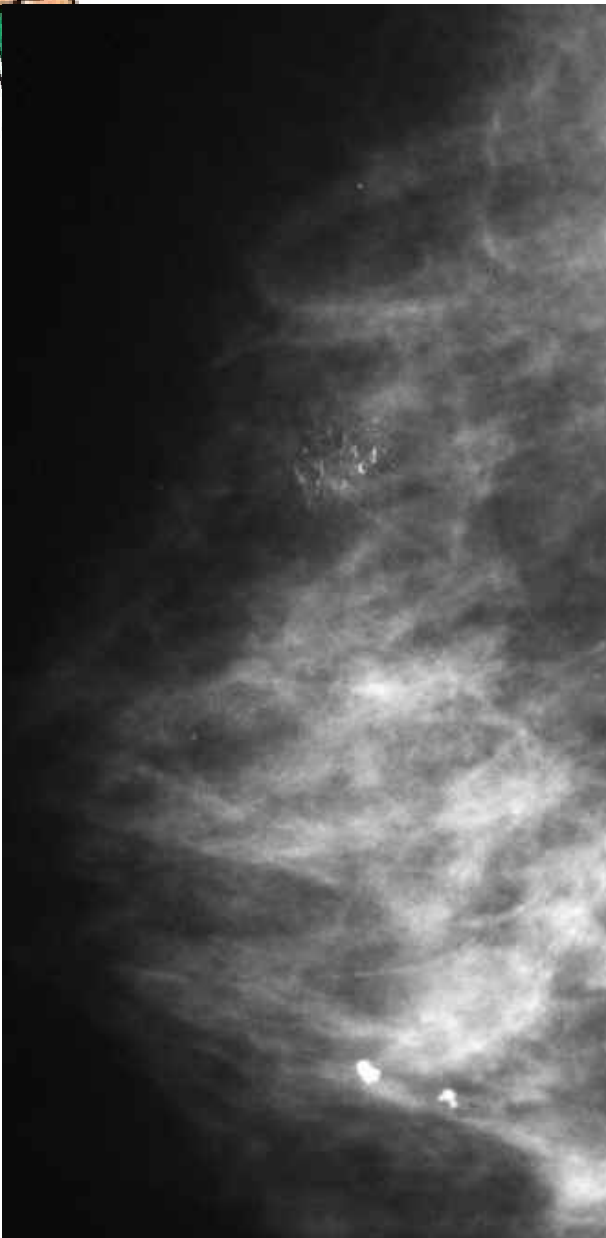56 ANI, BĂRBAT, 112 Kg LA 178cm



DIAGNOSTIC ? DISTROFIE ADIPOASĂ



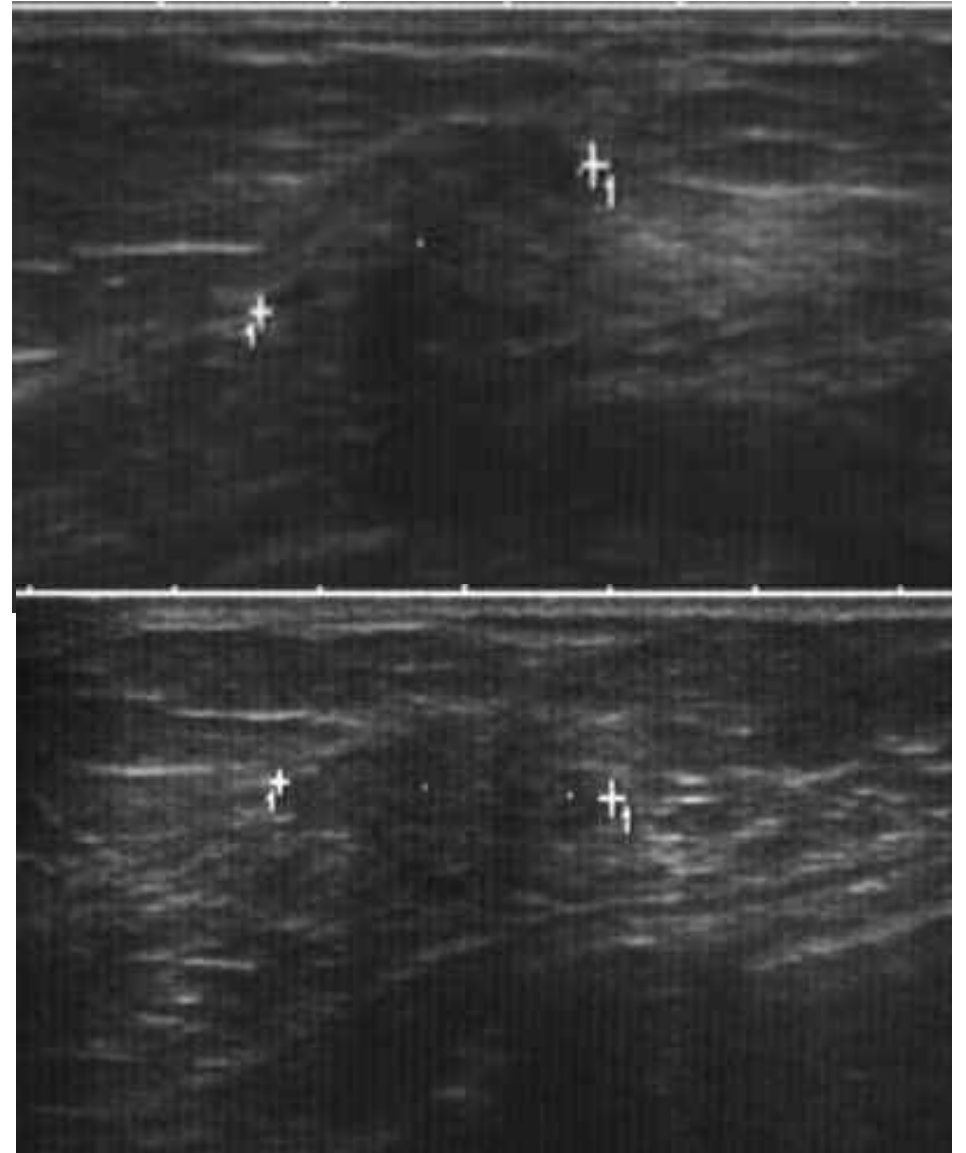
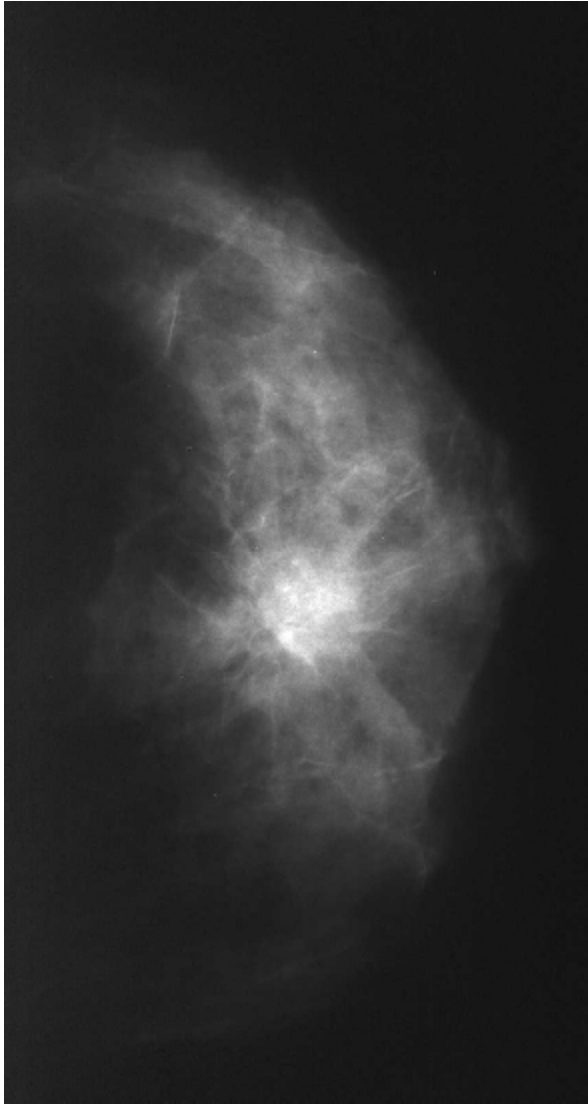
54 ANI, MASTECTOMIE STG. DE 2 ANI PENTRU T2,N1,G3



DIAGNOSTIC ? ADENOFIBROM, ALICE CU CSN
COD 3/2



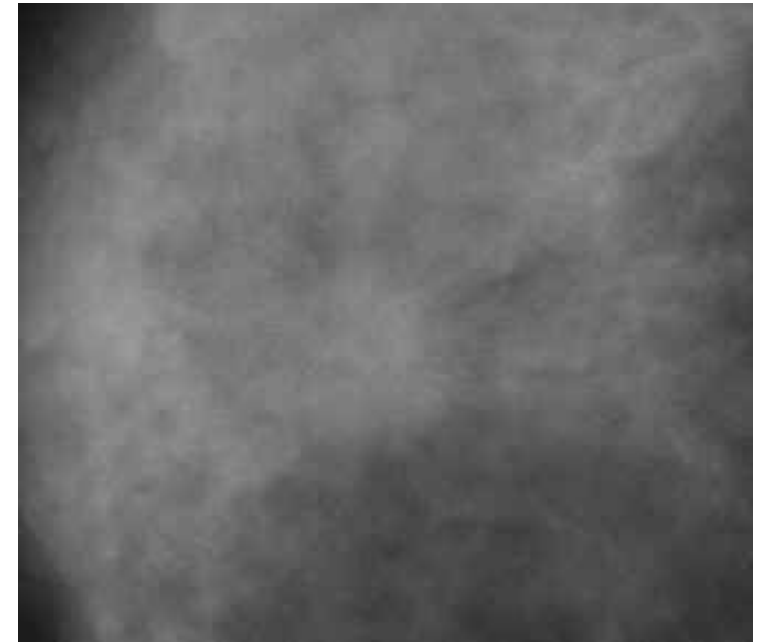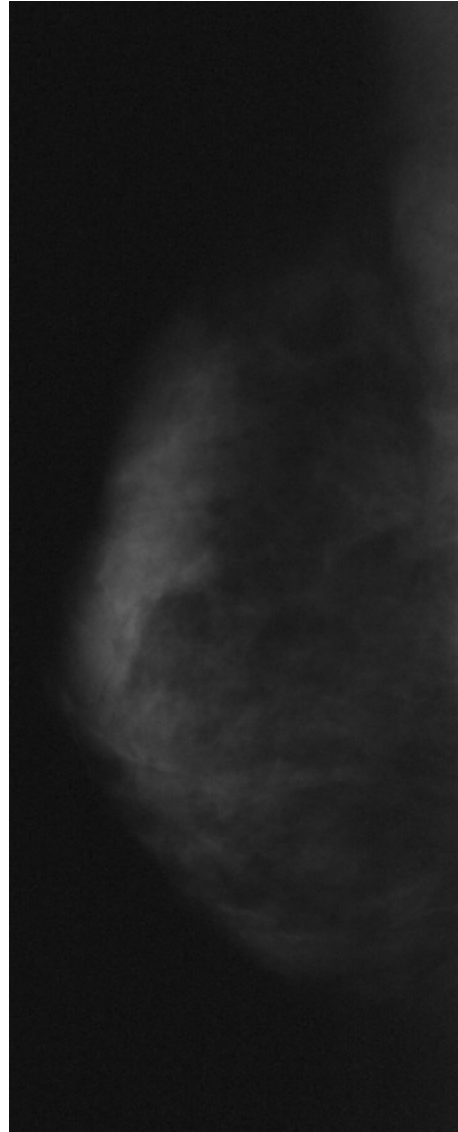
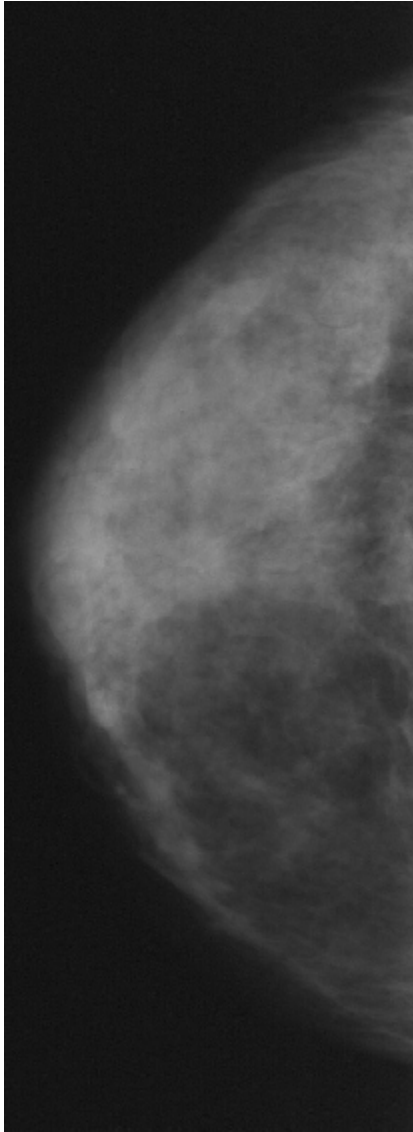
52 ANI, 16 ANI ANTICONCEPȚIONALE



DIAGNOSTIC ? CARCINOM DUCTAL INVAZIV COD 3/5



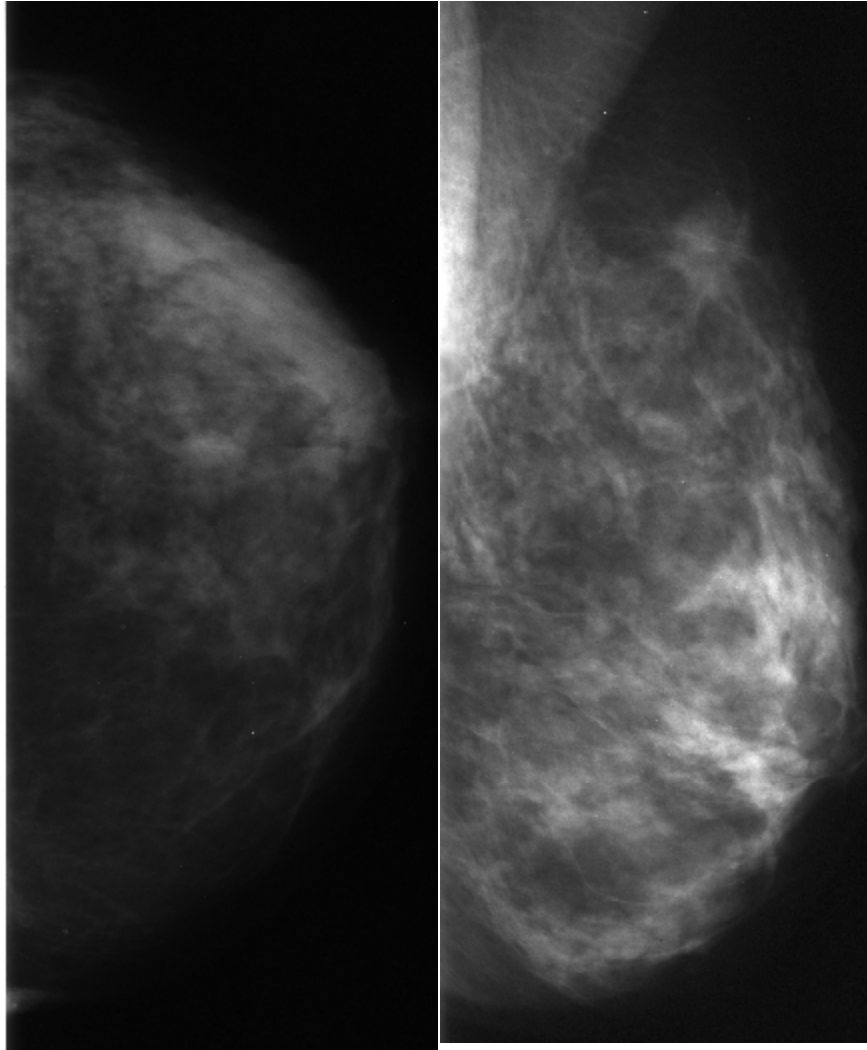
72 ANI - ÎN URMĂ CU 17 ANI



DIAGNOSTIC ? CARCINOM DUCTAL DR. INVAZIV COD 3/5



72 ANI, ÎN URMĂ CU 15 ANI 6 ANI ANTICONCEPȚIONALE

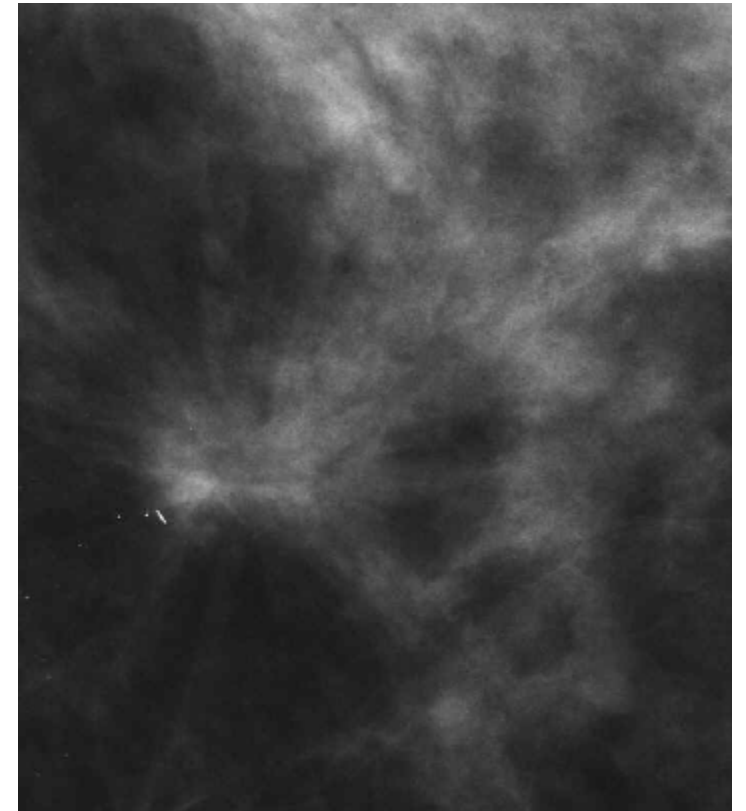
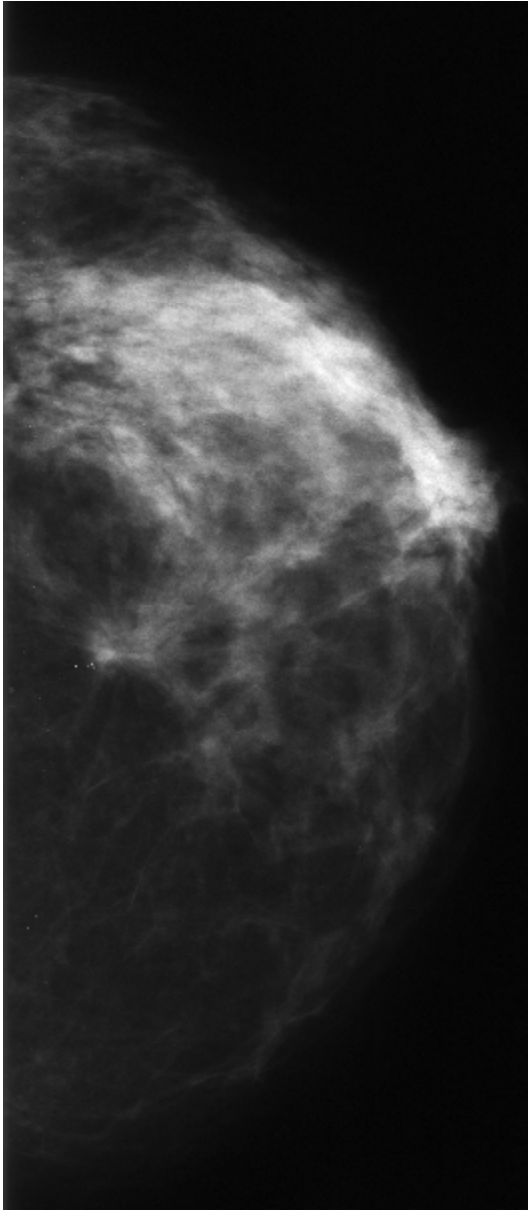


DIAGNOSTIC ?

CARCINOM DUCTAL STG. INVAZIV COD 2/5



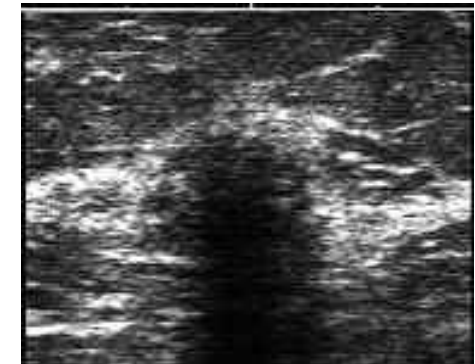
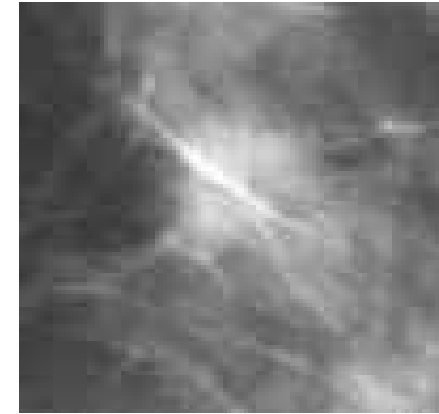
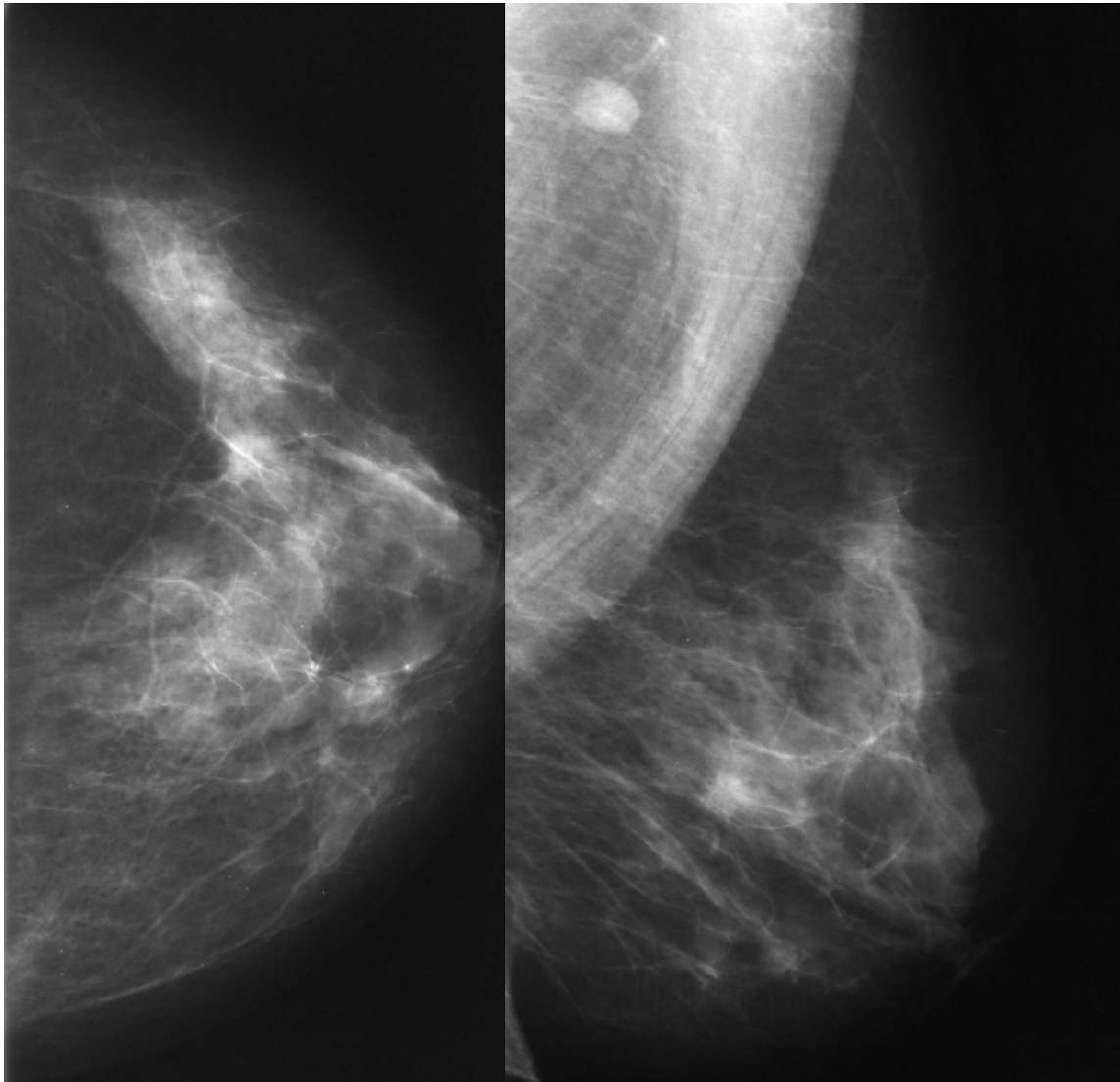
72 ANI, CARCINOM BILATERAL OPERAT



DIAGNOSTIC ? CICATRICE RADIARĂ COD 2/2



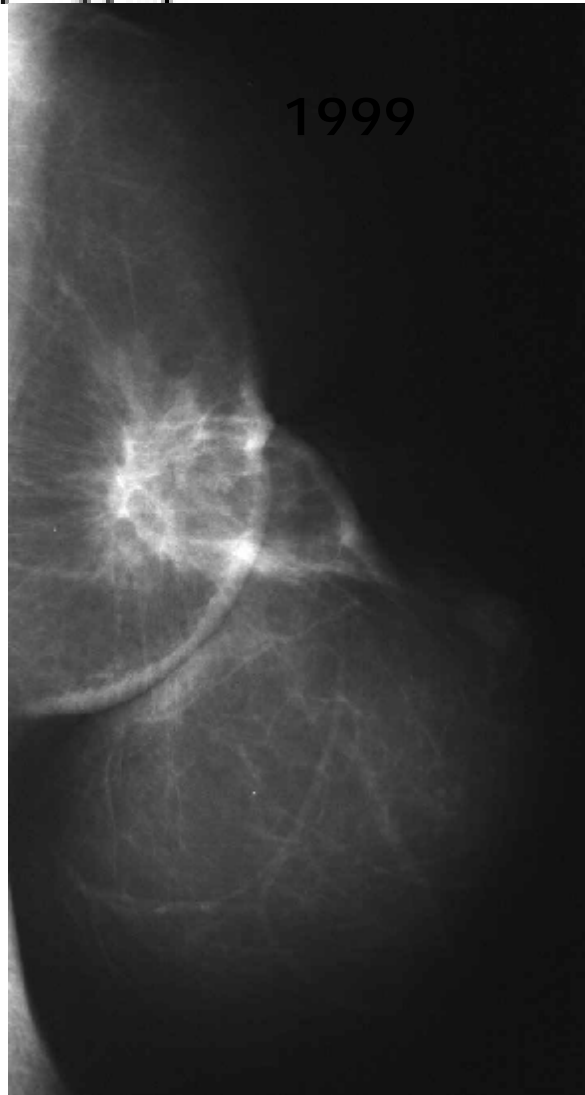
56 ANI, MENOPAUZĂ DE LA 53, FĂRĂ THS, FĂRĂ AHC



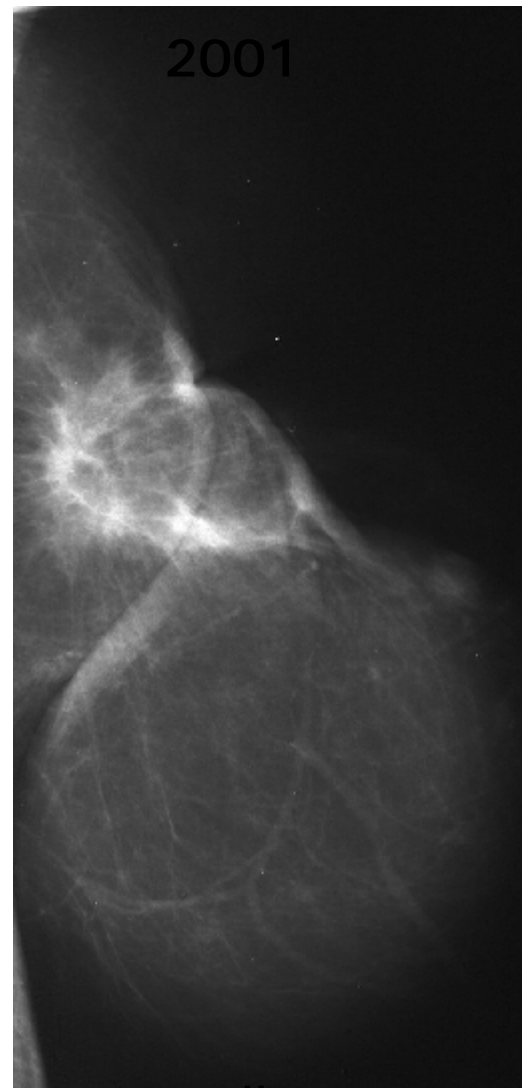
DIAGNOSTIC ? CARCINOM TUBULAR, T1,N0,G1, COD 2/5



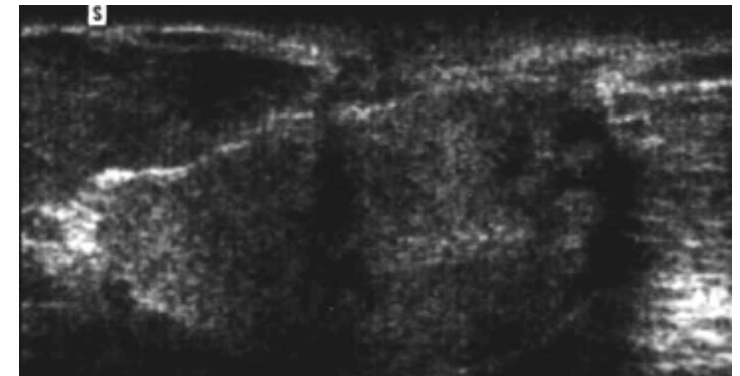
52 ANI, OPERATĂ ÎN 1998 T1,N0,MO,G2



DIAGNOSTIC ?

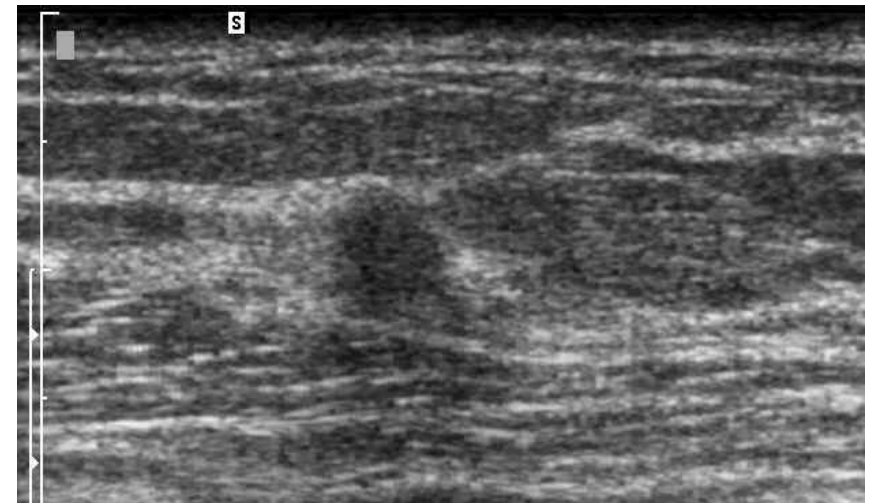
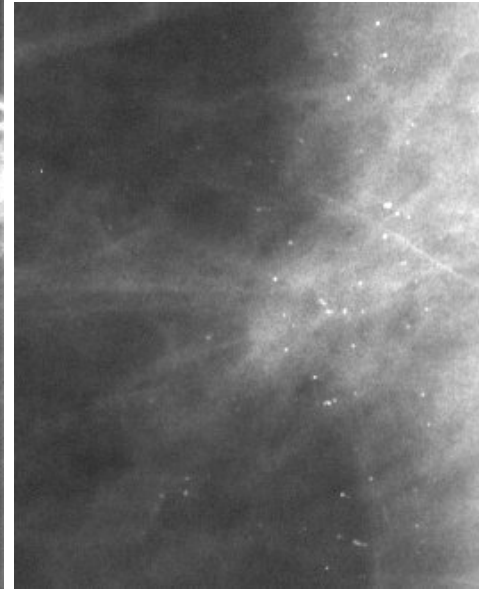
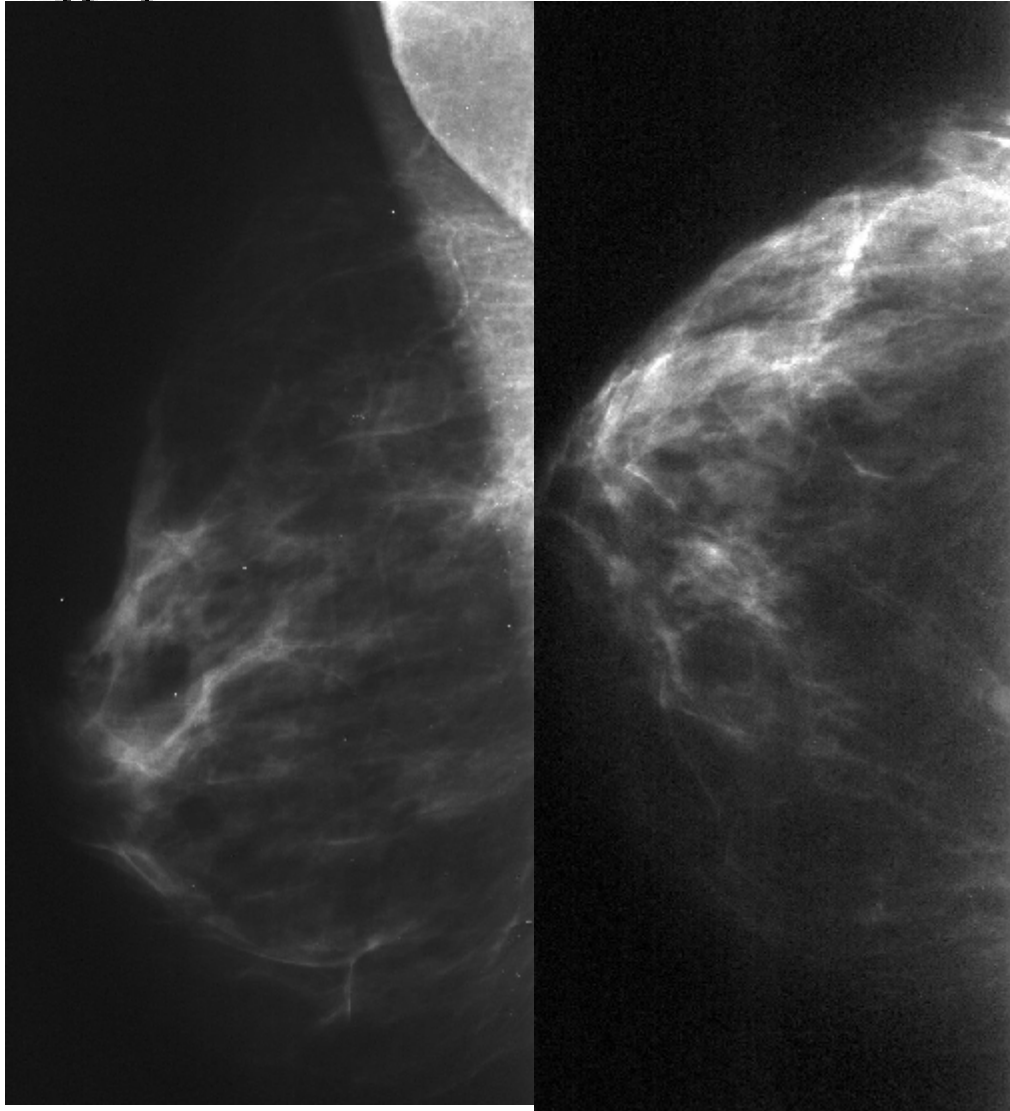


CITOSTEATONECROZĂ POSTOP., COD 1/2





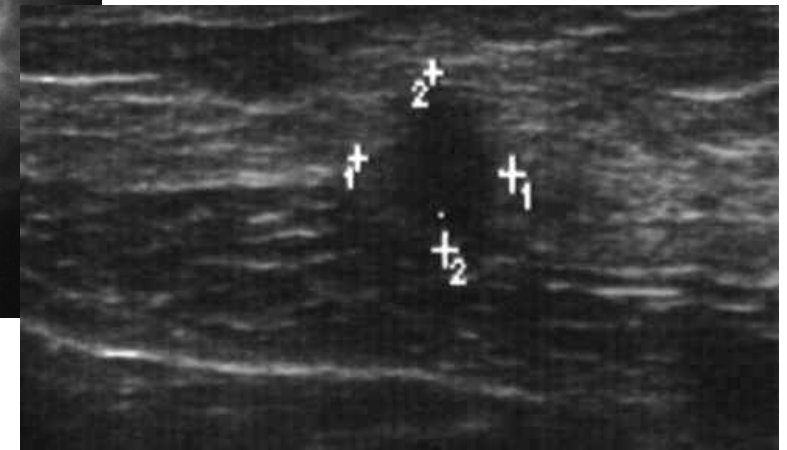
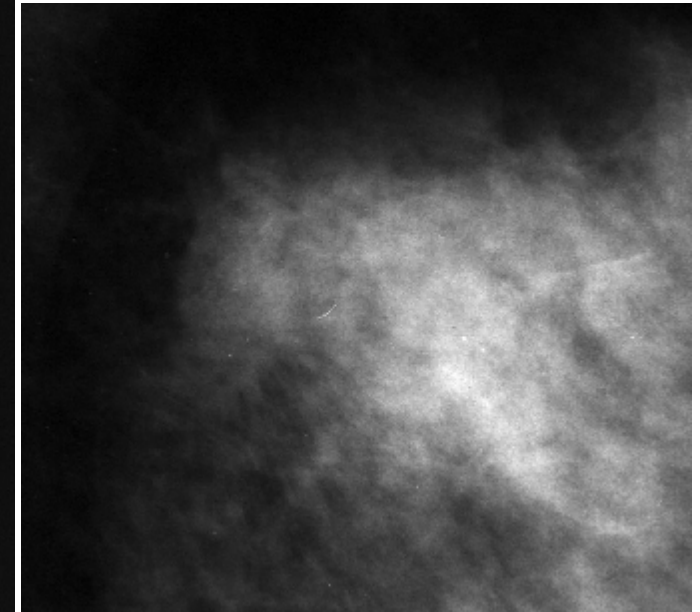
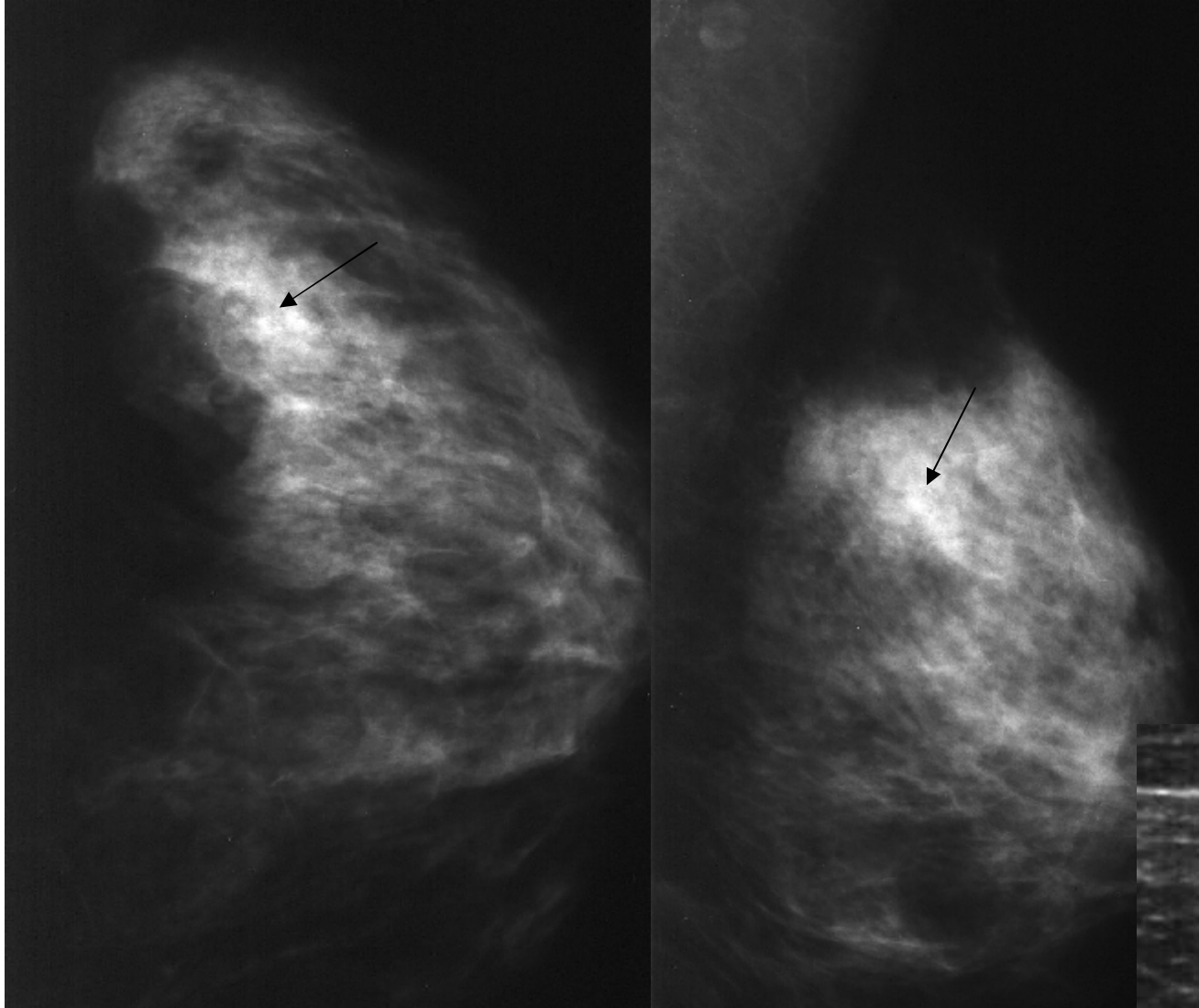
65 ANI, ASIMPTOMATICĂ, NULIGESTĂ



DIAGNOSTIC ? CCI, COD 2/5



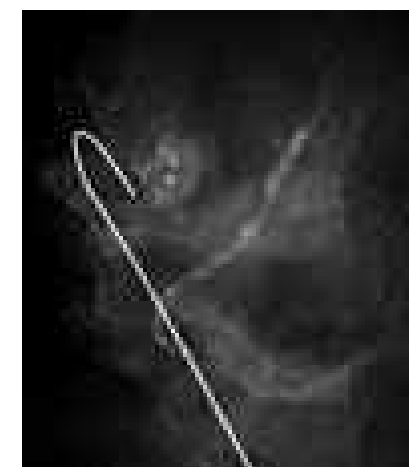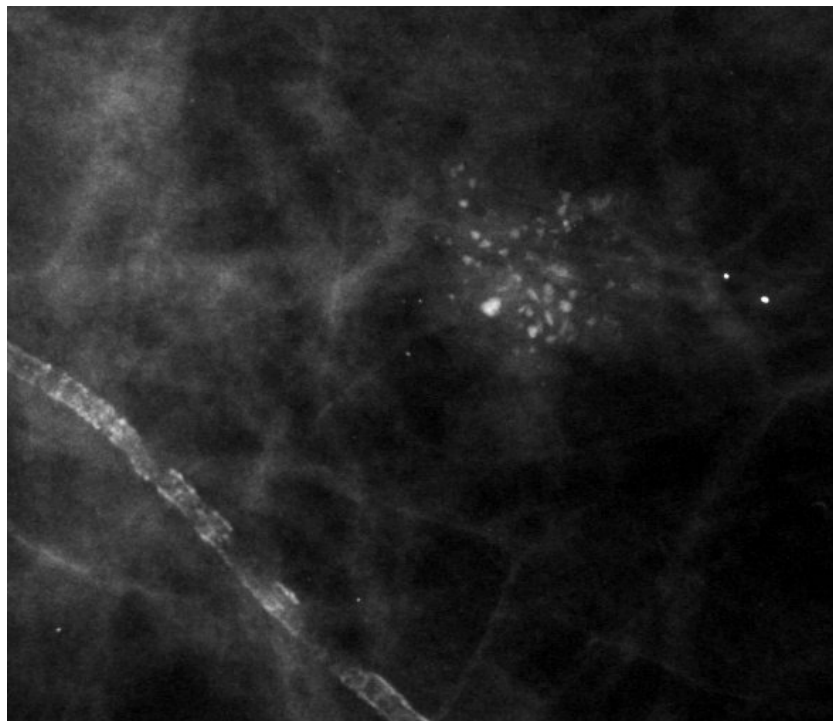
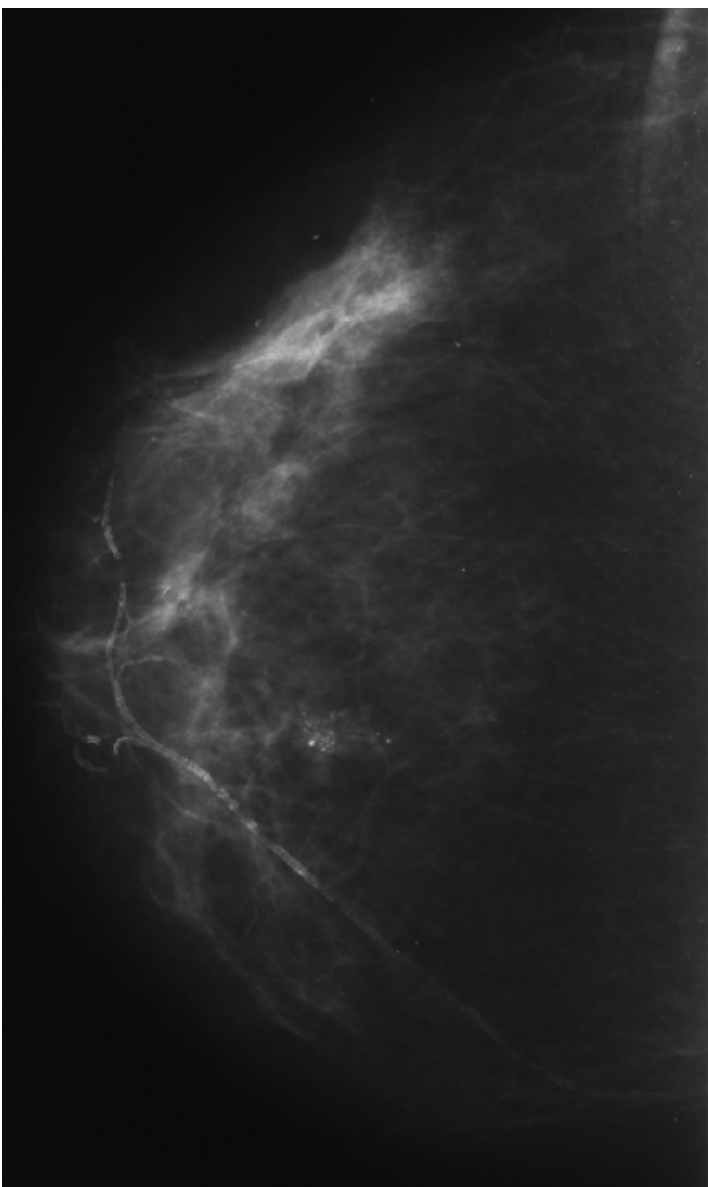
50 ANI, ASIMPTOMATICĂ, 2 COPII, FĂRĂ TRAT. HORMONAL



DIAGNOSTIC ? CCI, COD 3/5



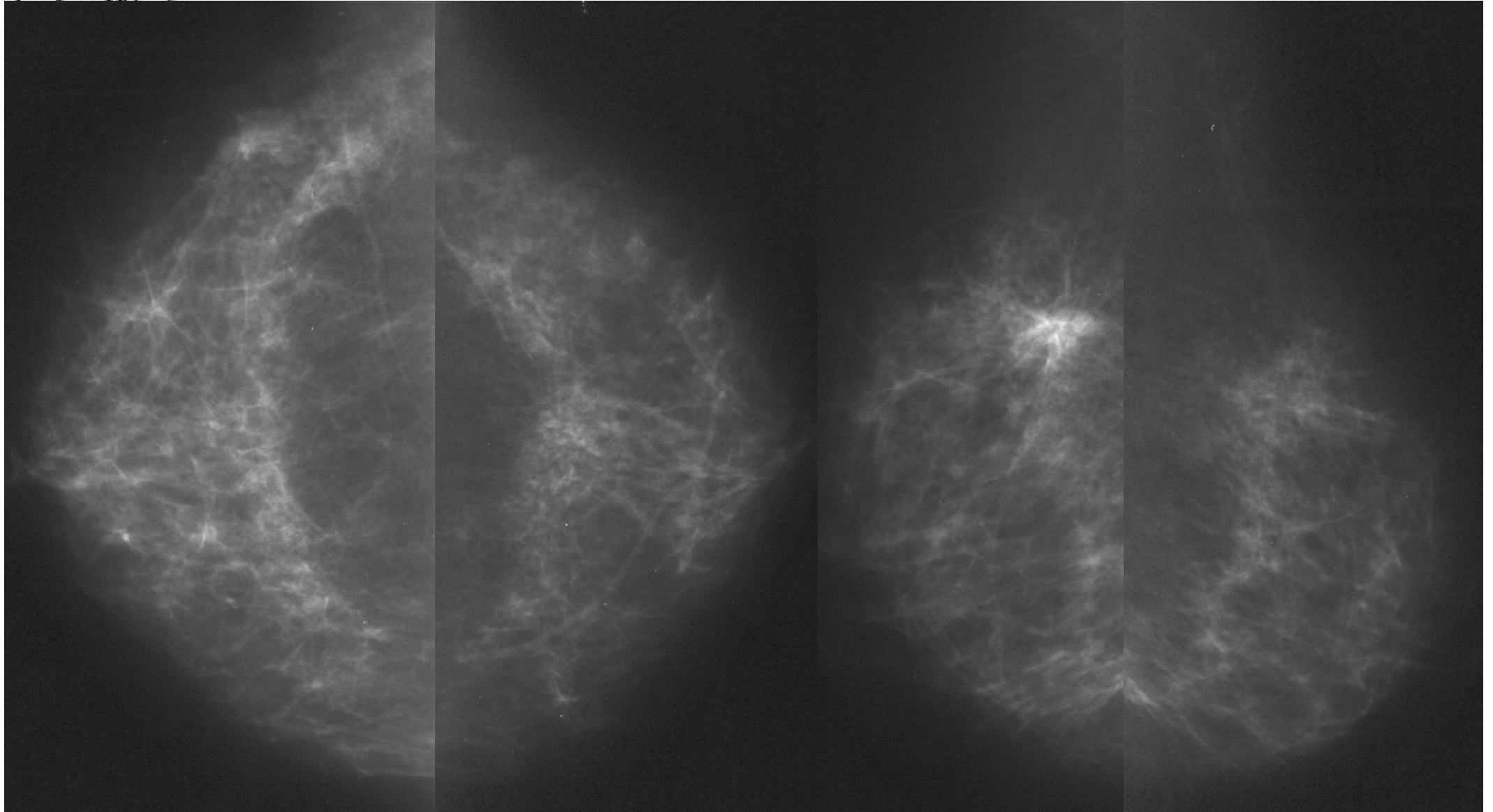
60 ANI, ASIMPTOMATICĂ, 1 COPIL, FĂRĂ TRAT. HORMONAL



DIAGNOSTIC ? CLI, COD 2/5



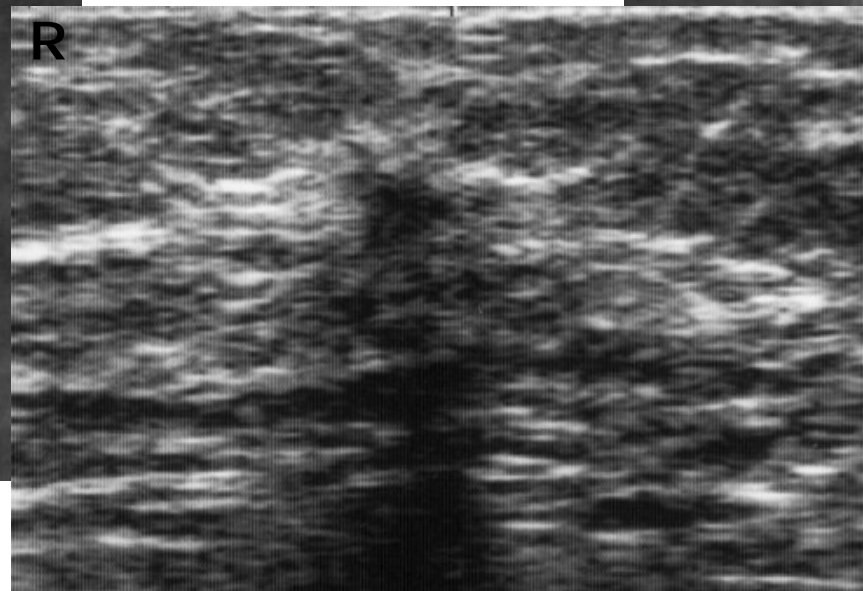
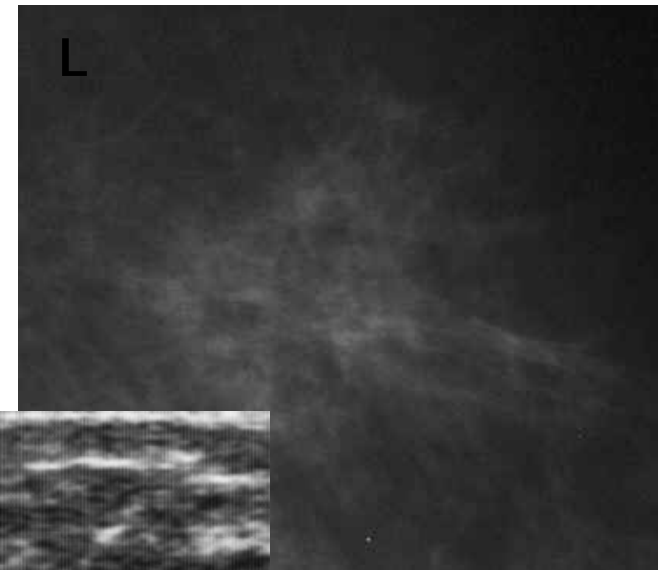
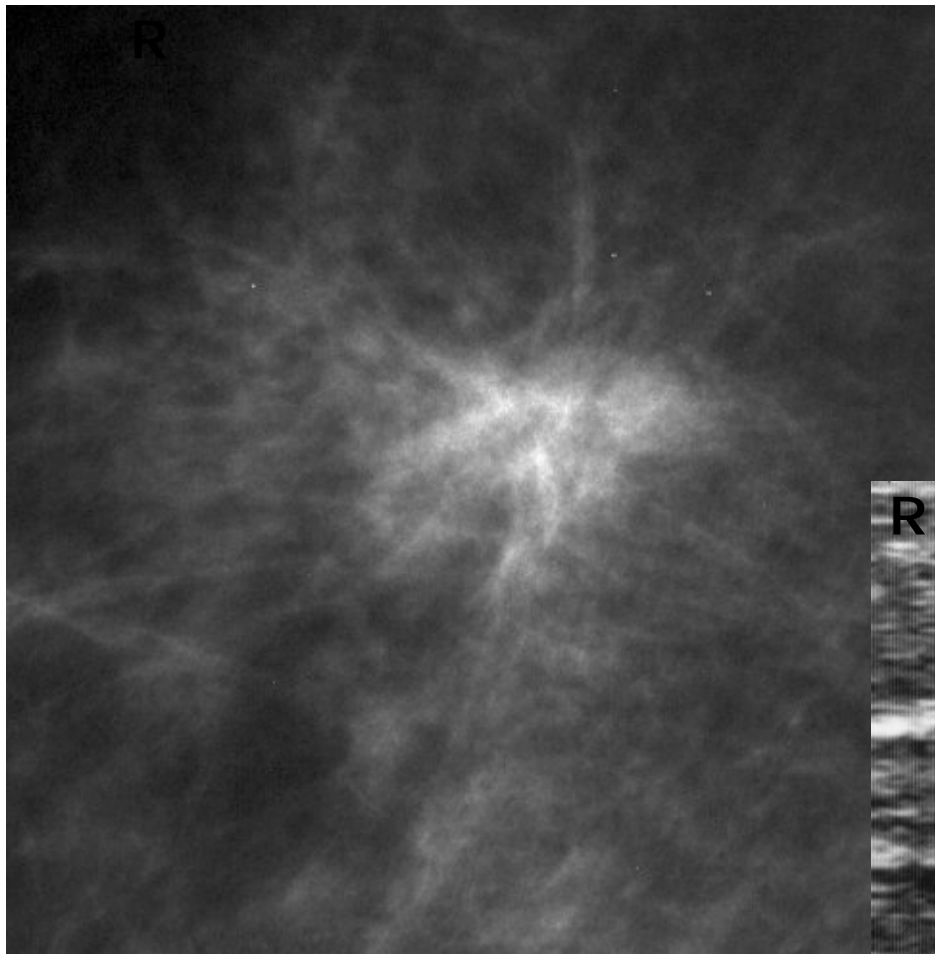
76 ANI, ASIMPTOMATICĂ, 8 ANI TRAT. HORMONAL



DIAGNOSTIC ? DR.- CCI, COD 2/5
STG.-HIPERPLAZIE EPITELIALĂ, COD 4/2



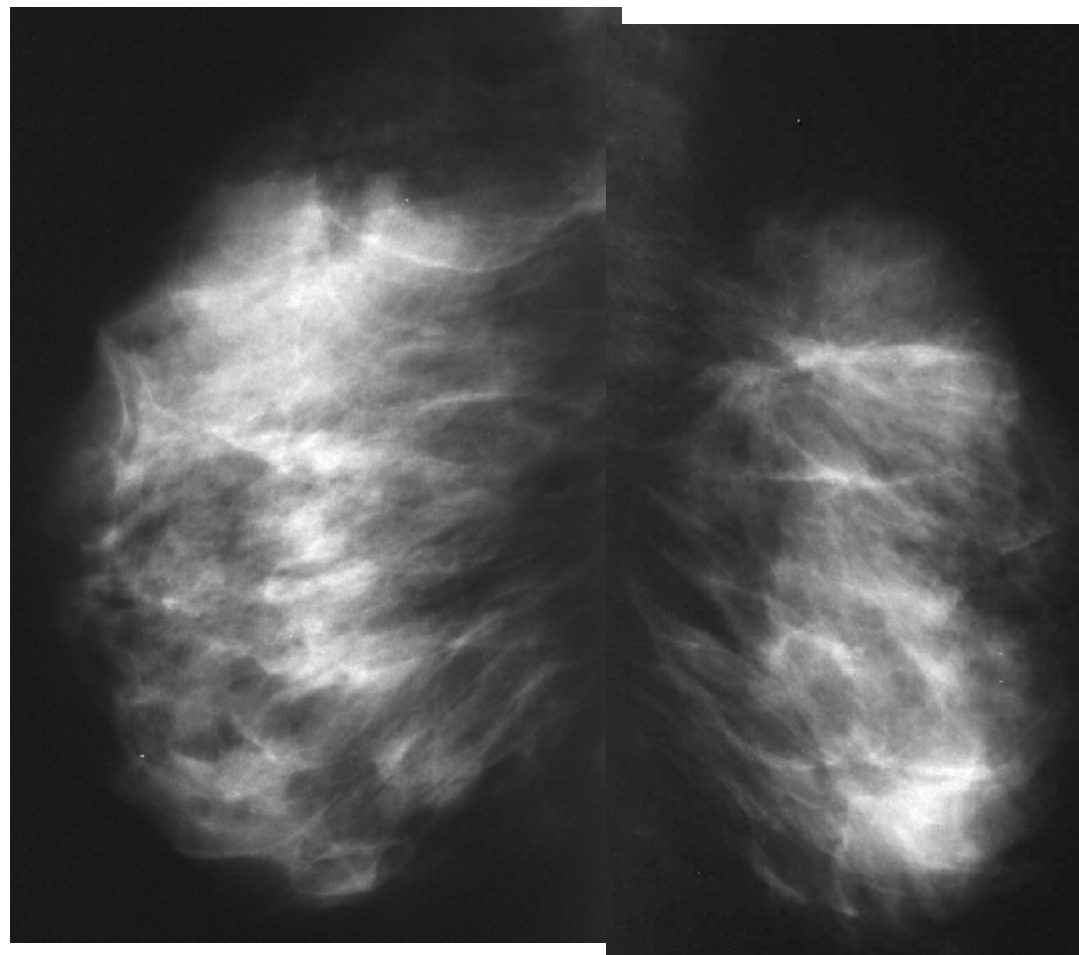
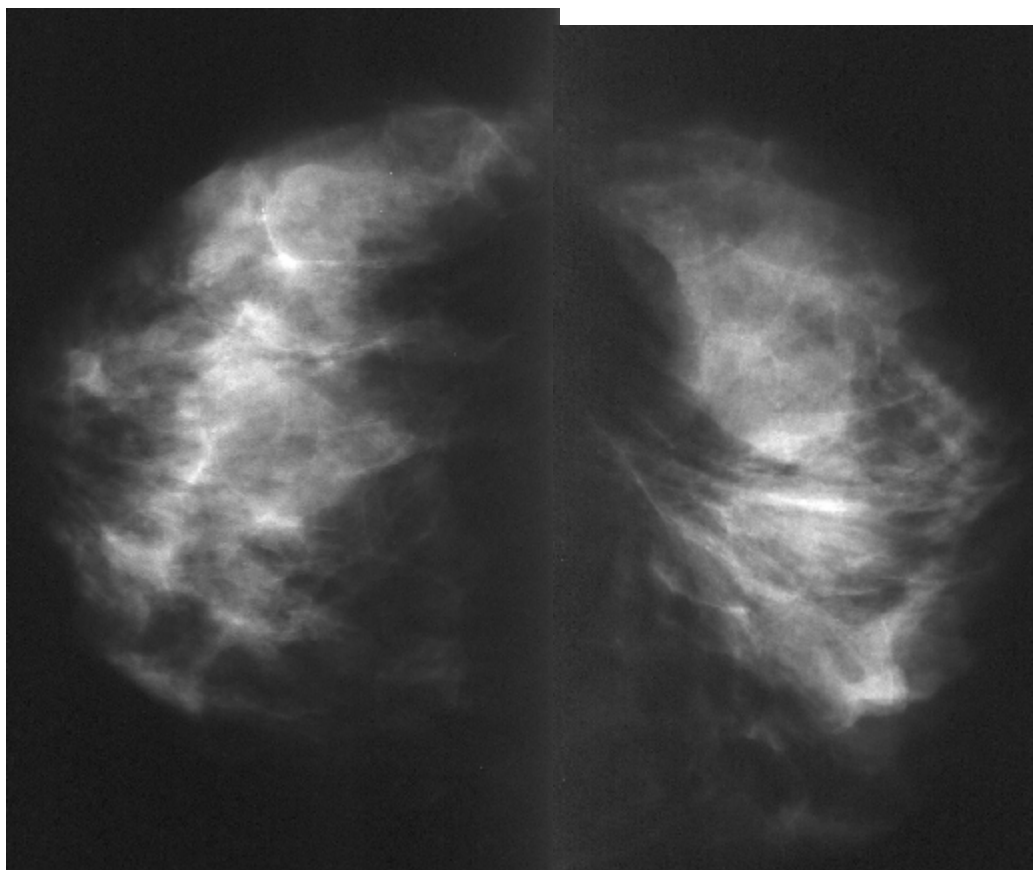
76 ANI, ASIMPTOMATICĂ, 8 ANI TRAT. HORMONAL



DIAGNOSTIC ? DR.- CCI, COD 2/5
STG.- HIPERPLAZIE EPITELIALĂ, COD 2/2



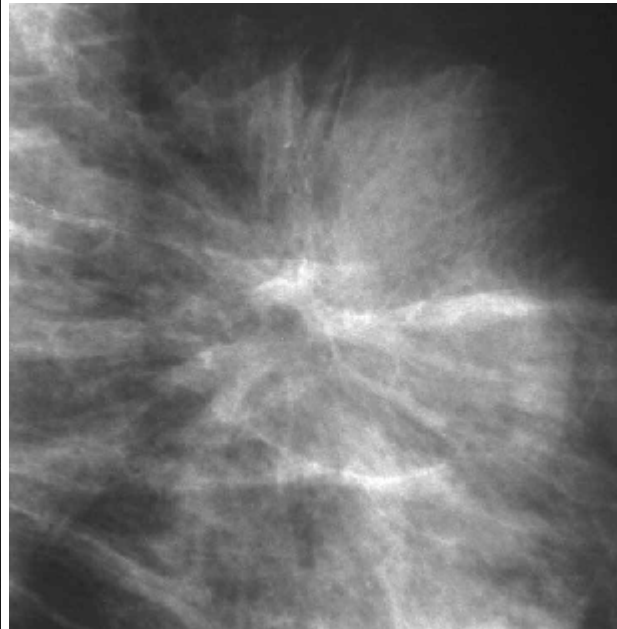
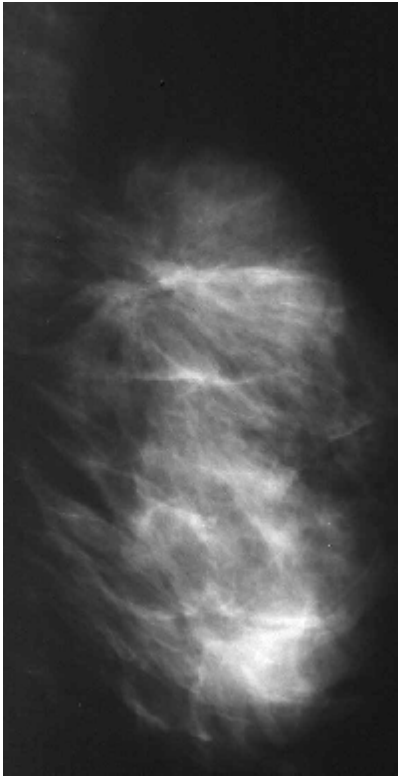
43 ANI, ASIMPTOMATICĂ, MAMA DECEDATĂ PRIN CCI



DIAGNOSTIC ?



43 ANI, ASIMPTOMATICĂ, MAMA DECEDATĂ PRIN CCI

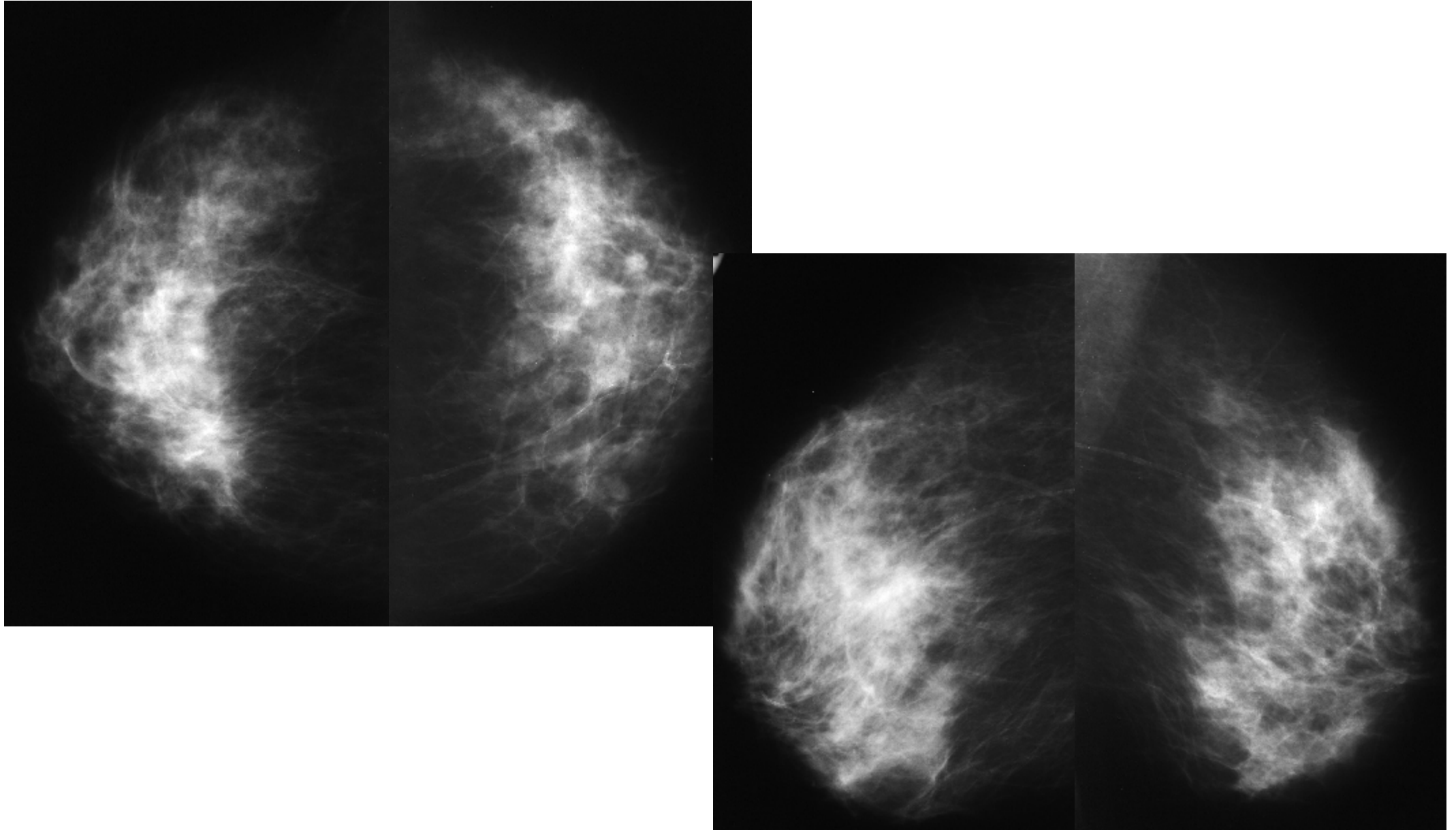


**ECOGRAFIE NORMALĂ
IRM - NORMAL**

DIAGNOSTIC ?

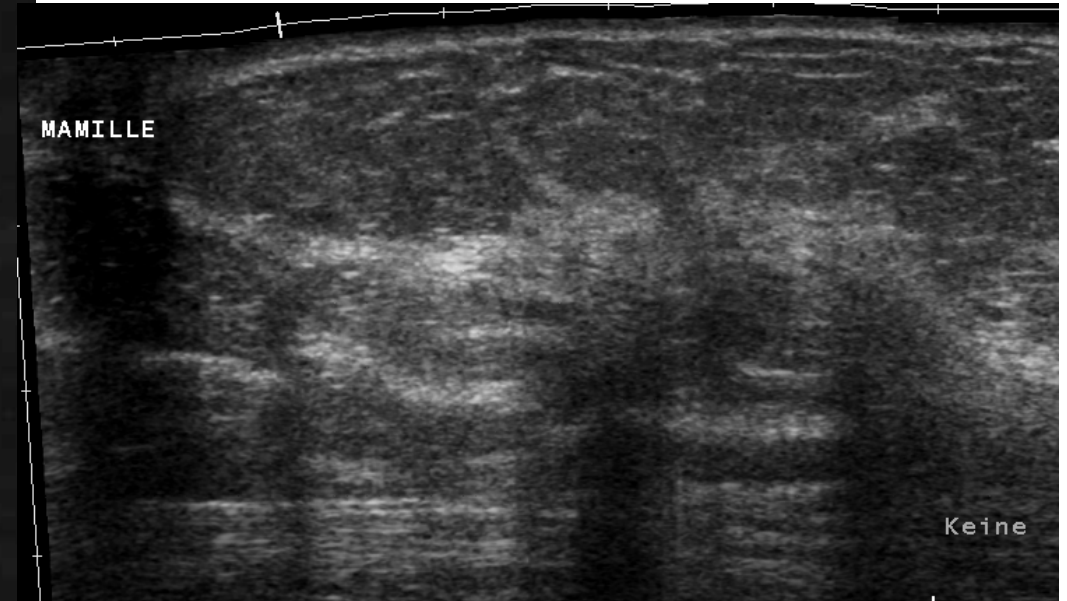
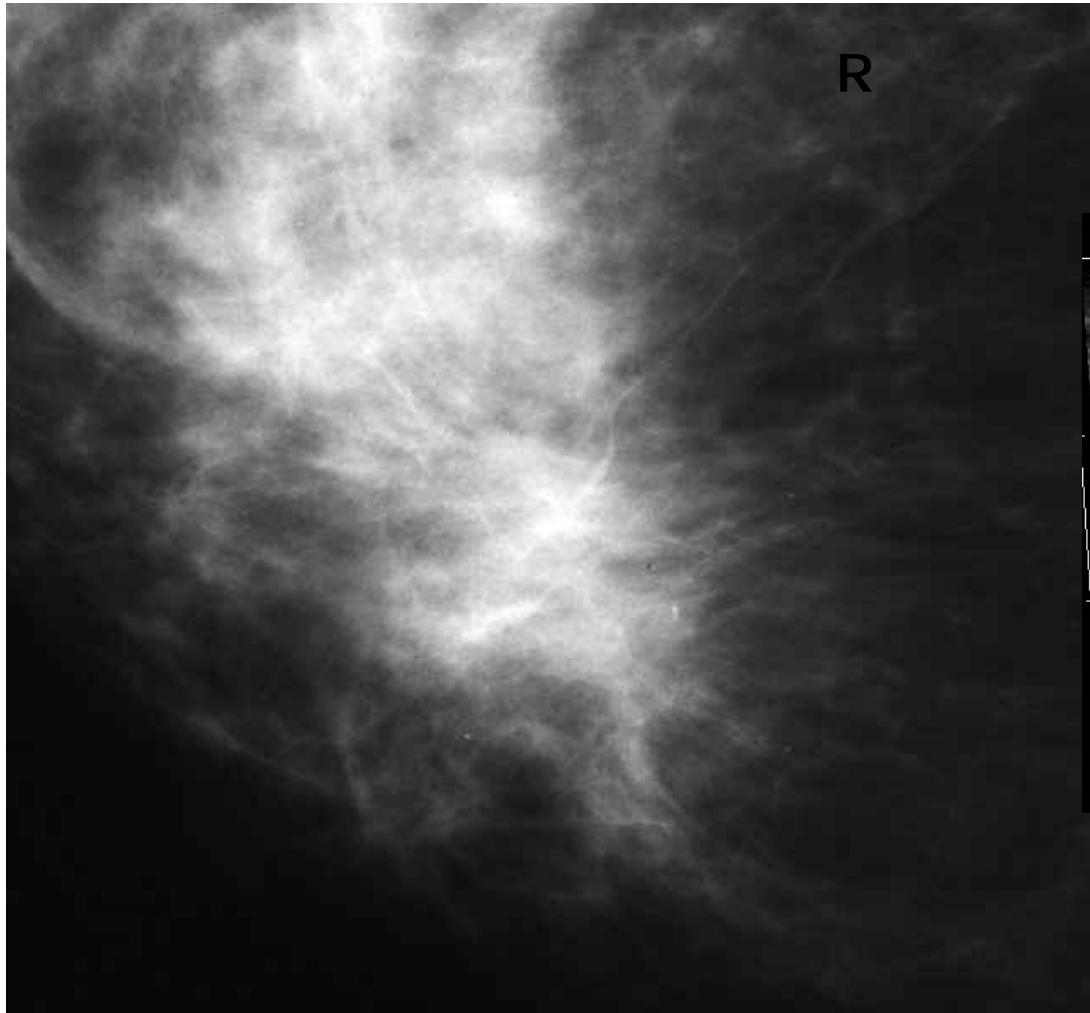
COD 3/3, CONTROL DUPĂ 6 LUNI, EVENTUAL ȘI IRM

70 ANI, OP. ÎN URMĂ CU 8 ANI CU CCI DR.,CHIMIO-,RADIOTERAPIE





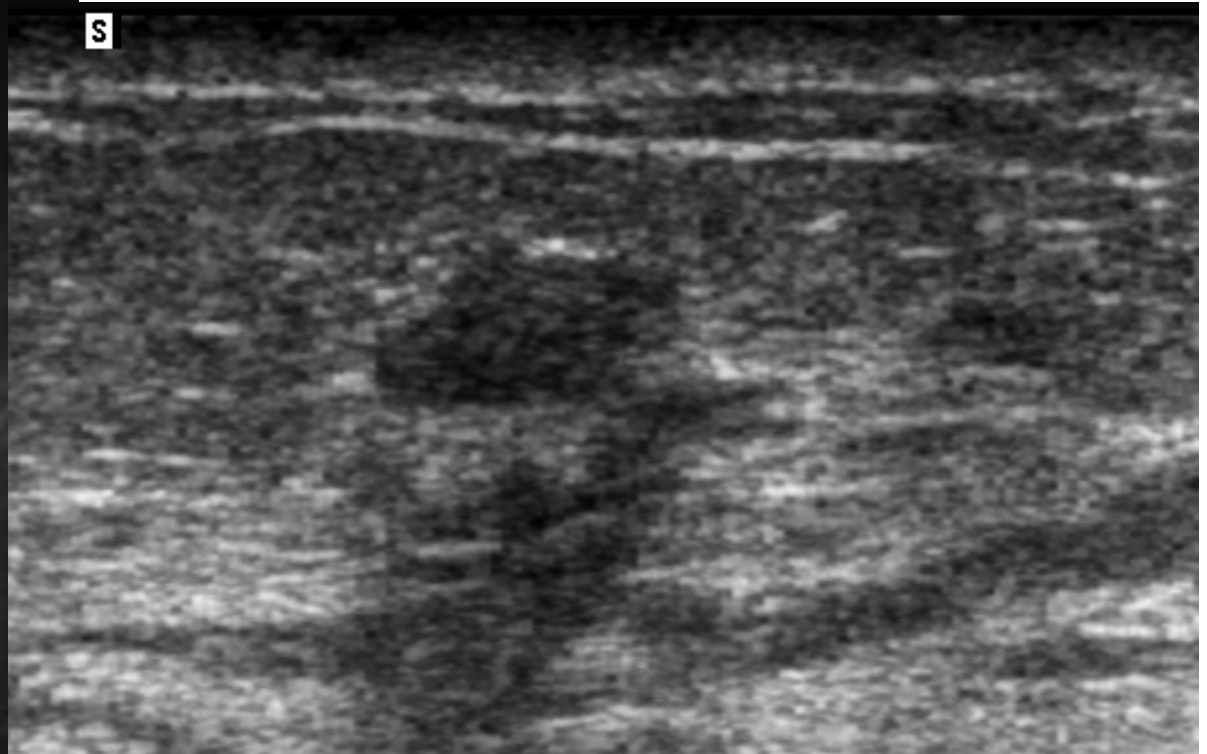
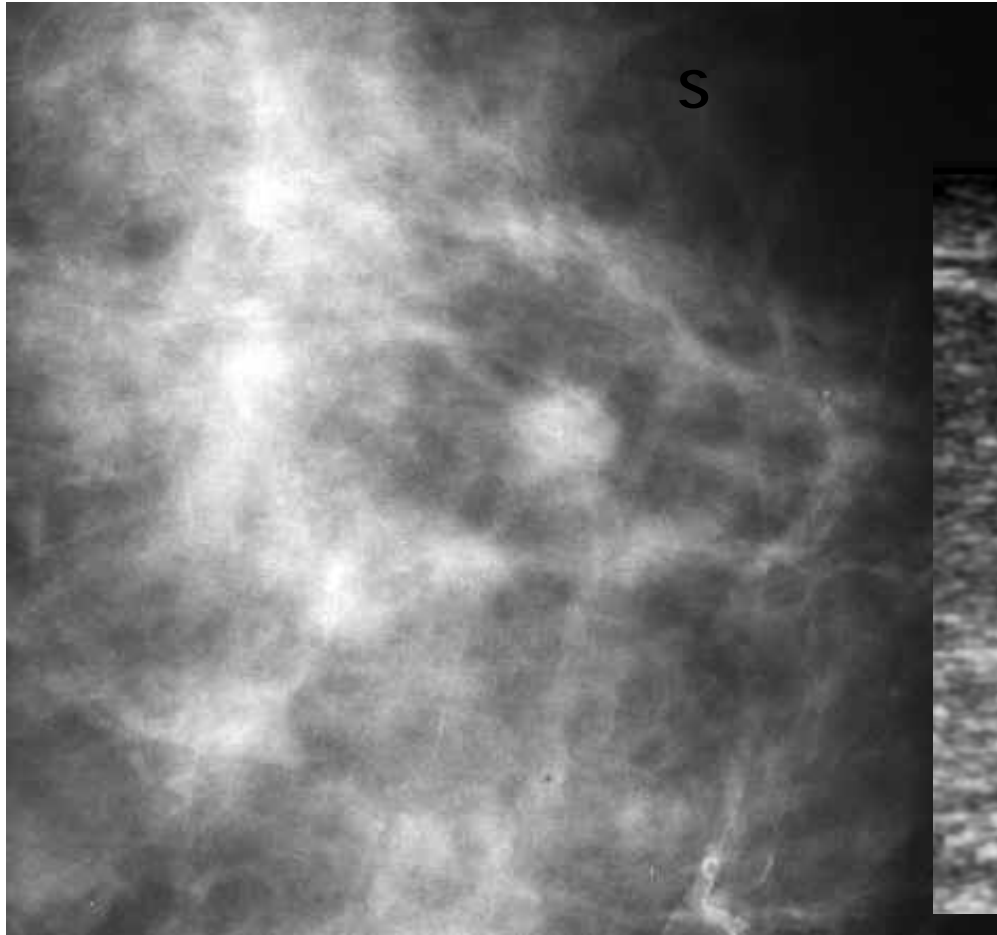
70 ANI, OP. ÎN URMĂ CU 8 ANI CU CCI DR.
CHIMIO-,RADIOTERAPIE



DIAGNOSTIC ? RECIDIVĂ, COD 3/5



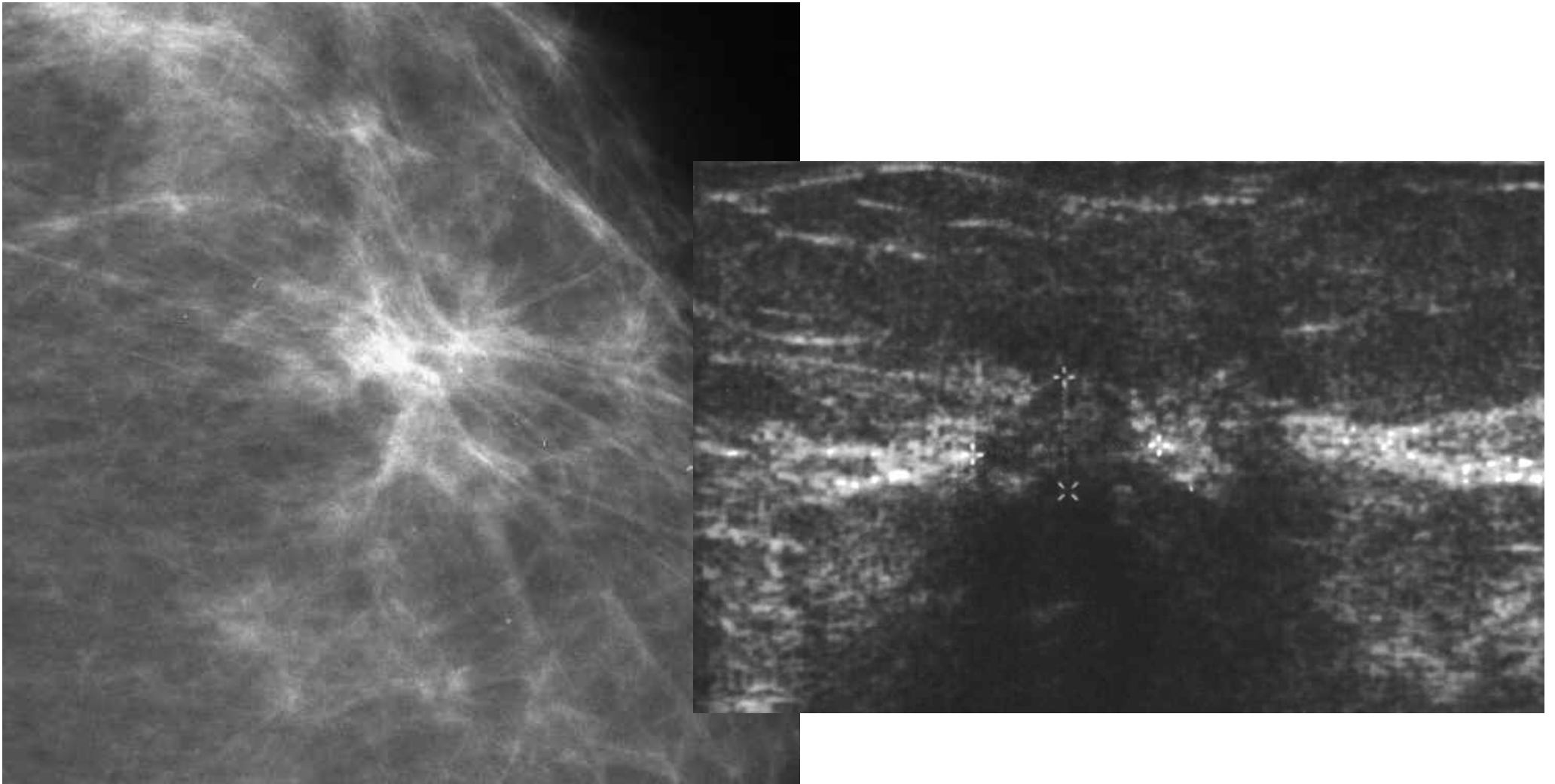
70 ANI, OP. ÎN URMĂ CU 8 ANI CU CCI DR.
CHIMIO-,RADIOTERAPIE



DIAGNOSTIC ? CCI, COD 3/5 - CANCER MULTIFOCAL



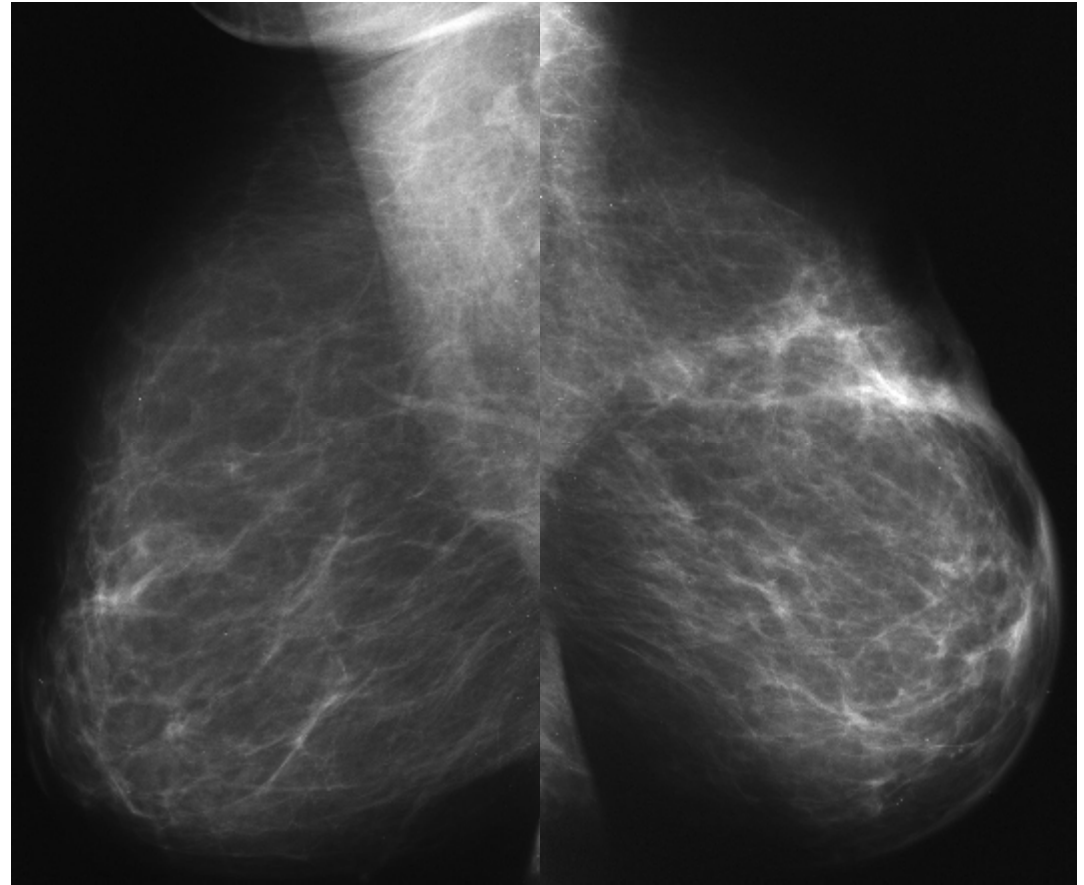
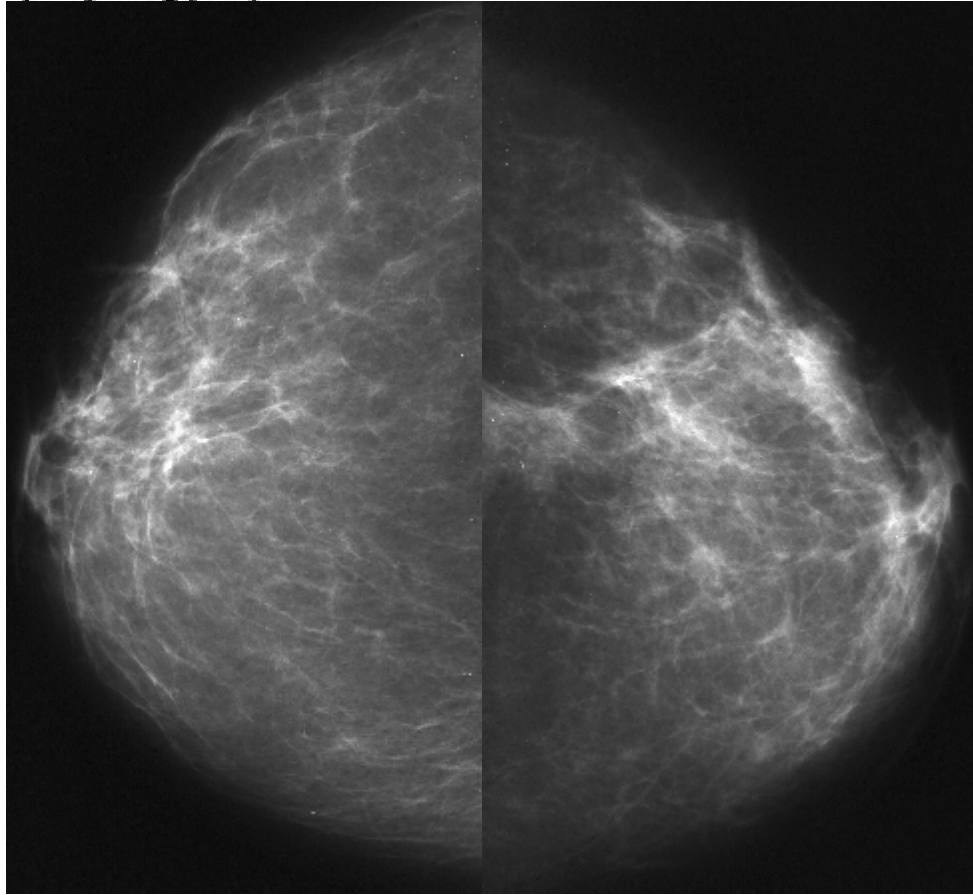
72 ANI, MASTECTOMIE DR. ÎN URMĂ CU 10 ANI



DIAGNOSTIC ? CARCINOM TUBULAR, COD 1/5 - CANCER MULTIFOCAL

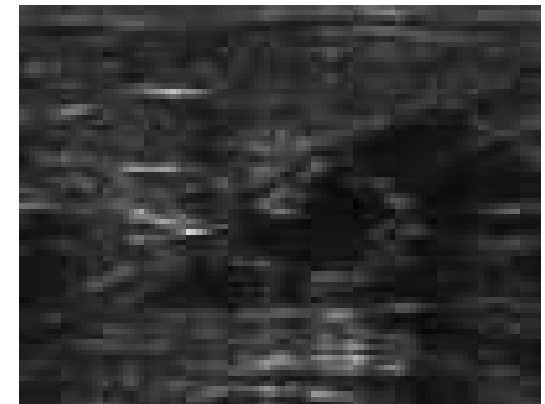


62 ANI, MASTECTOMIE SECTORIALĂ STG. ÎN URMĂ CU 6 ANI



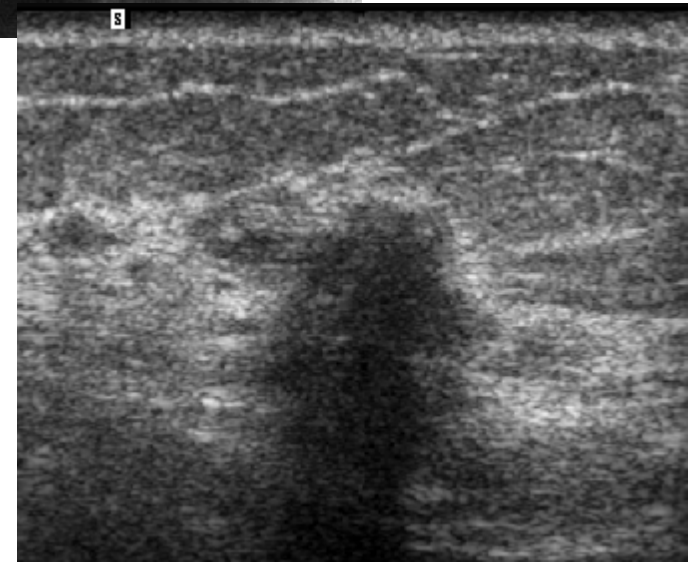

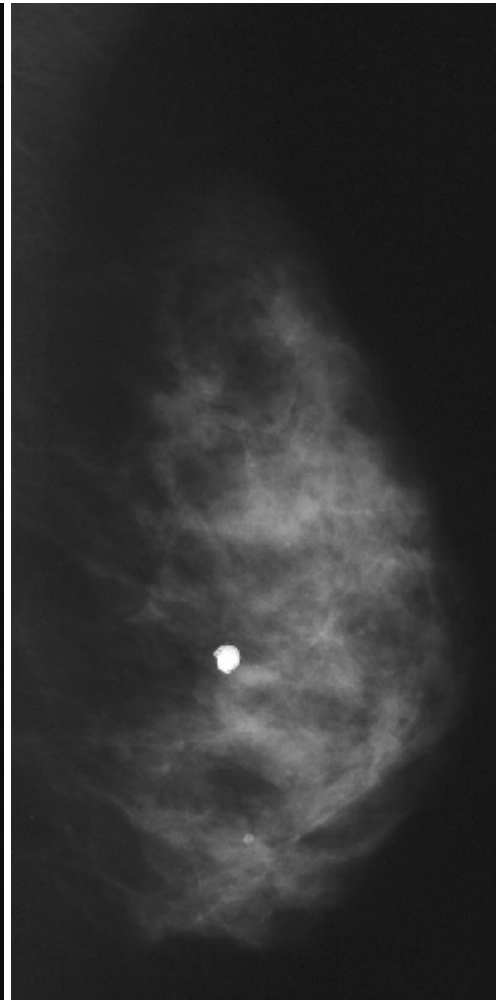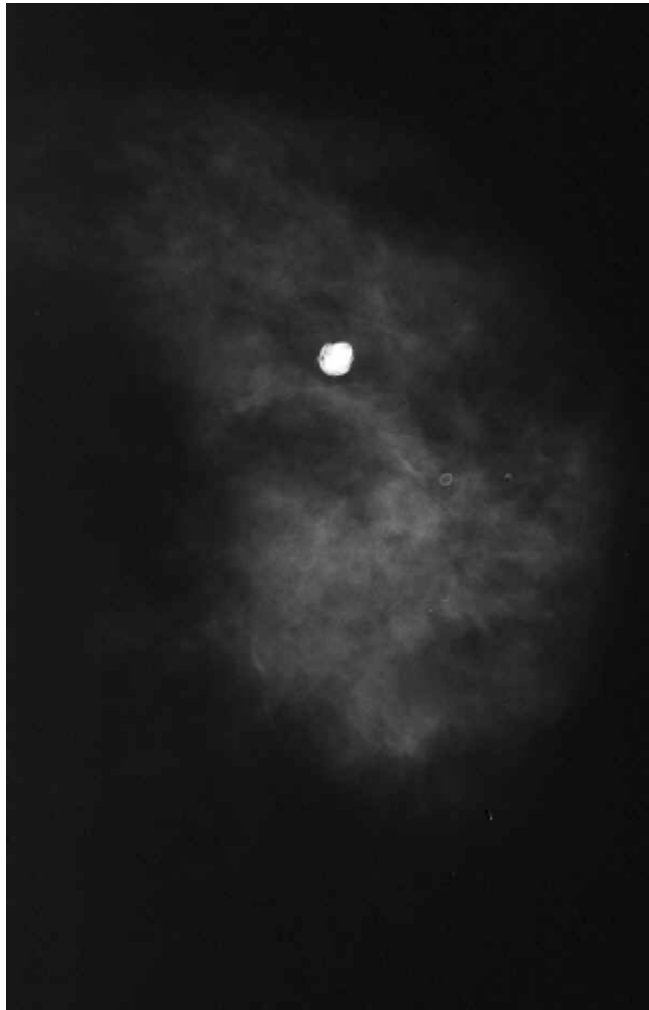
DIAGNOSTIC ?

CITOSTEATONECROZĂ, COD 2/2





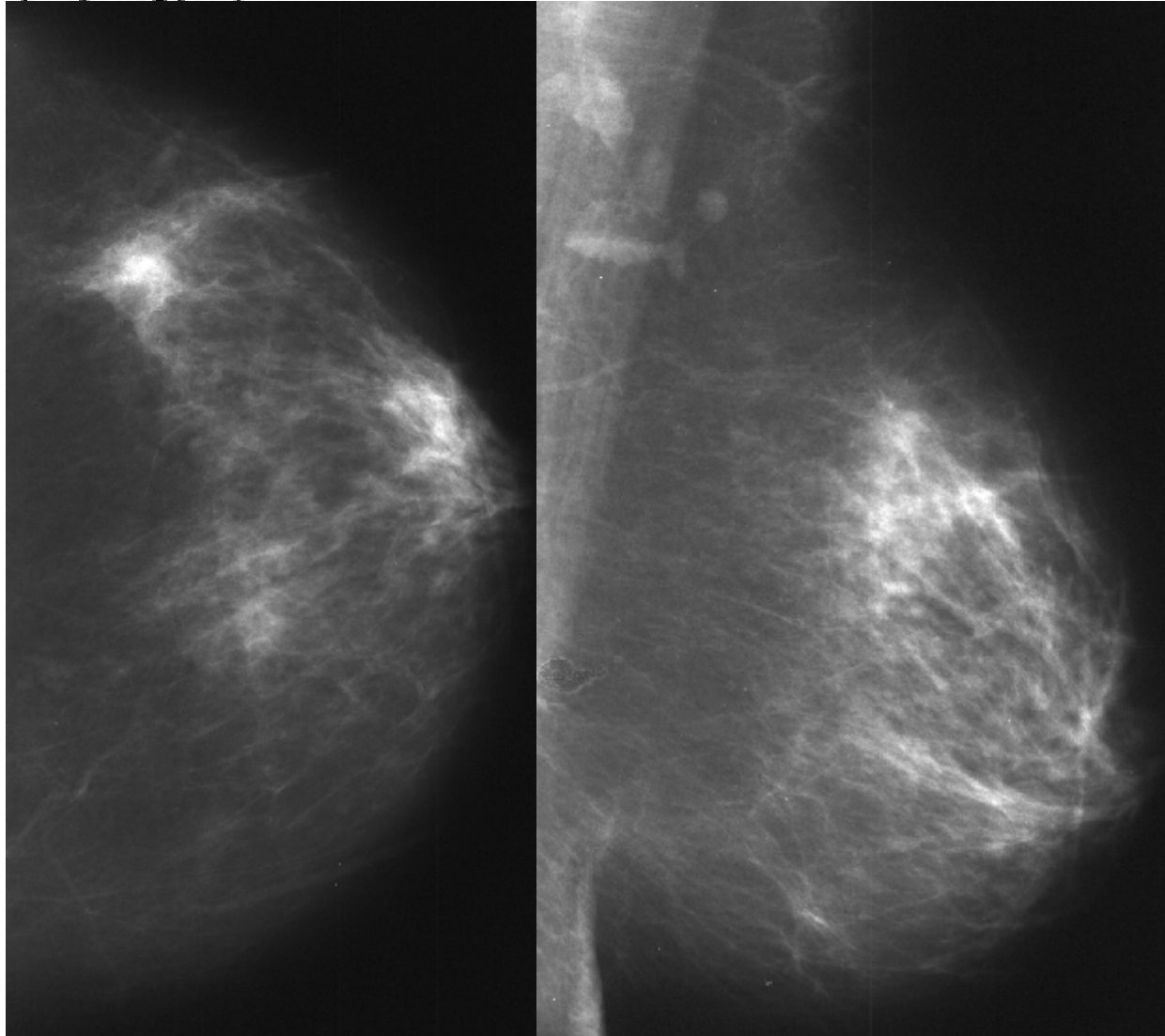
52 ANI, ASIMPTOMATICĂ, SORĂ CU CCI



DIAGNOSTIC ? CCI, COD 3/5

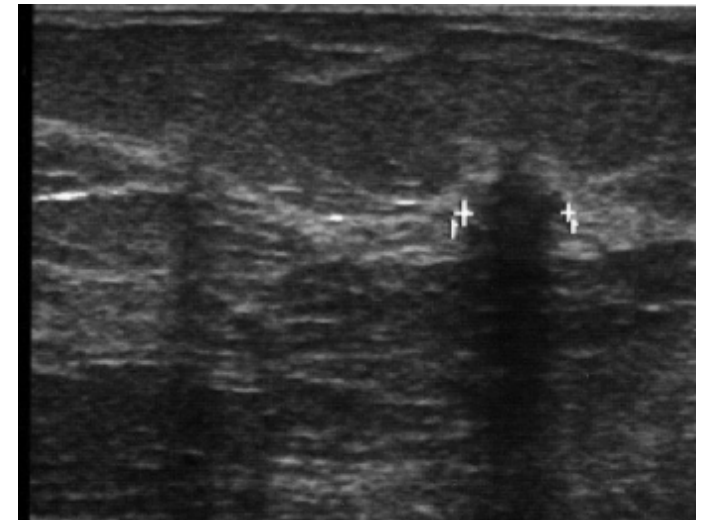
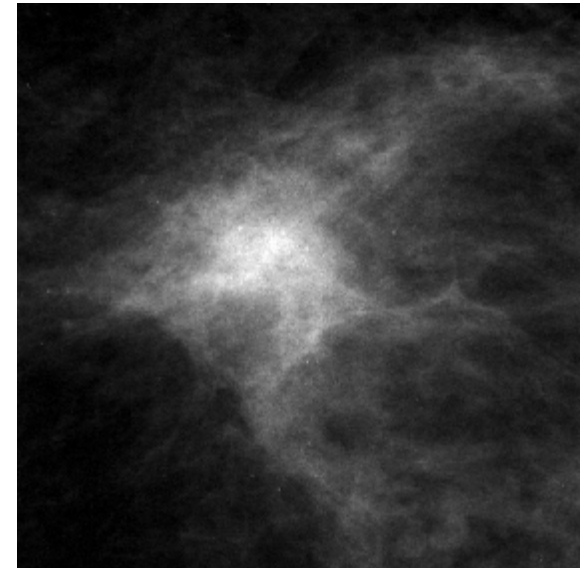


66 ANI, ASIMPTOMATICĂ



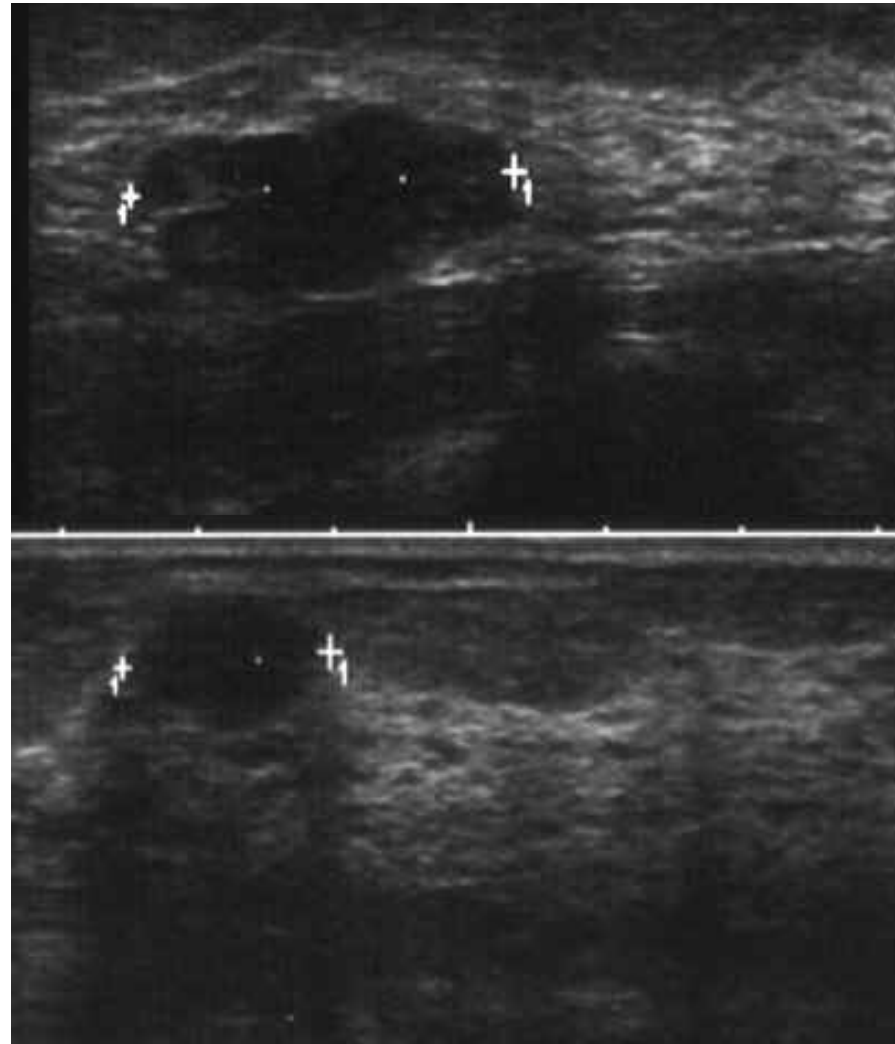
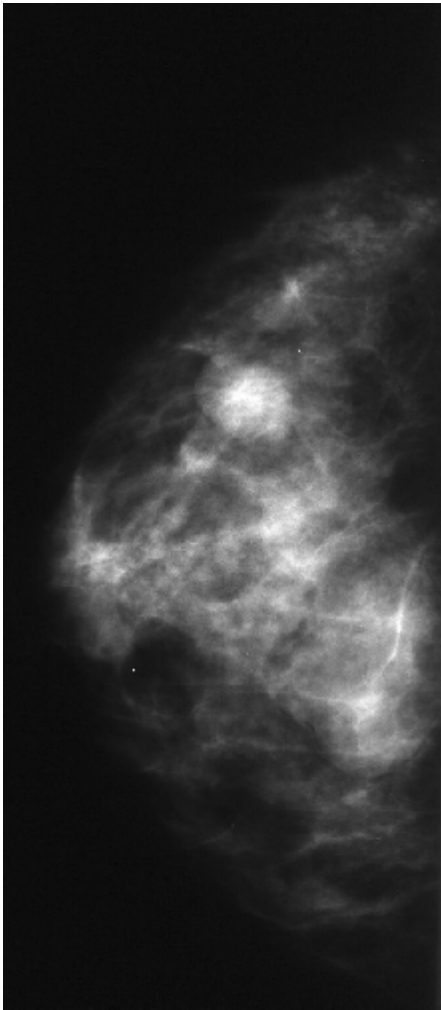
DIAGNOSTIC ?

CCI, COD 2/5





33 ANI, ANTICONCEPȚIONALE, MAMA CU CCI,

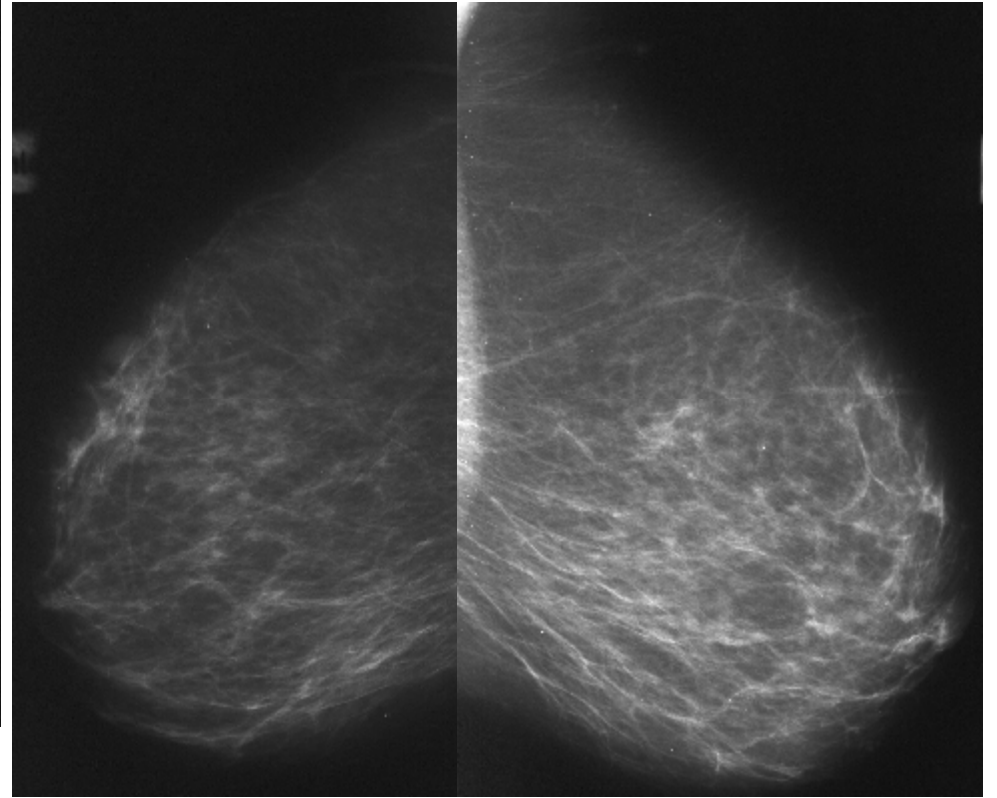
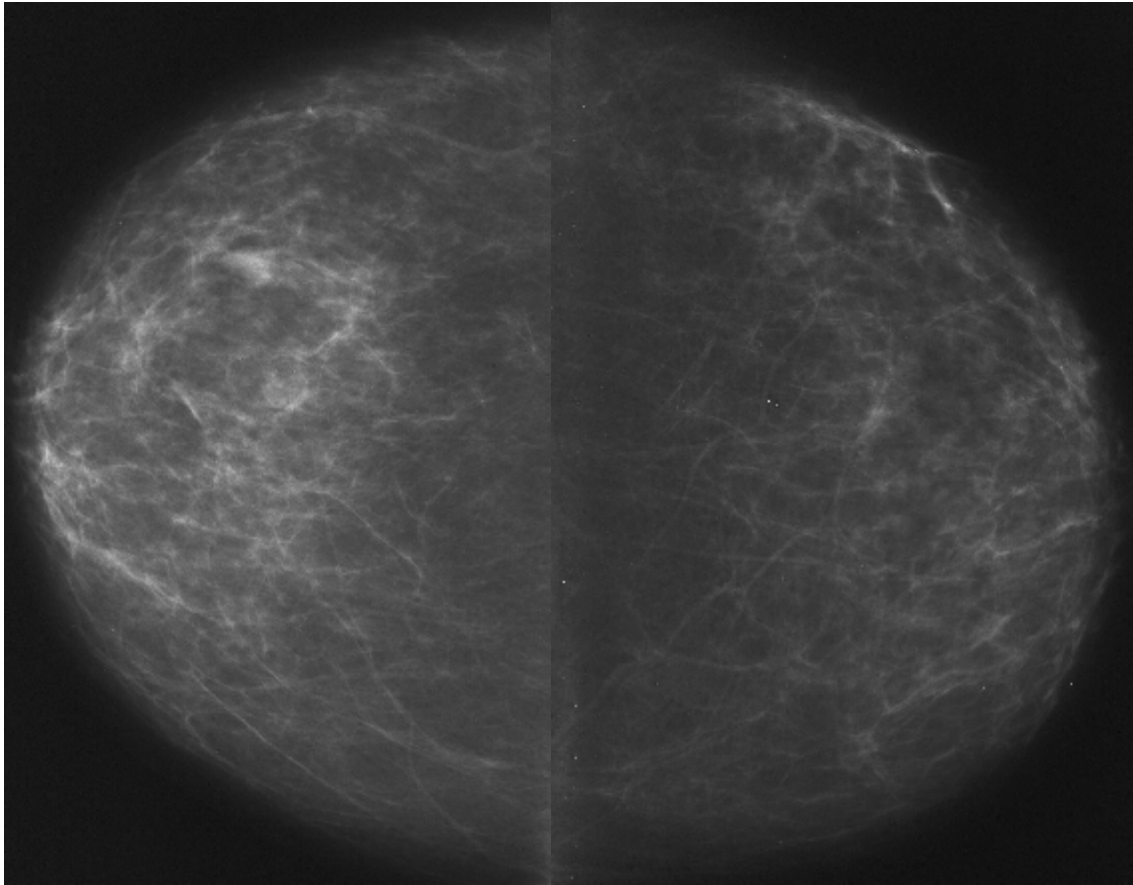


DIAGNOSTIC ?

FIBROADENOAME, COD 3/2

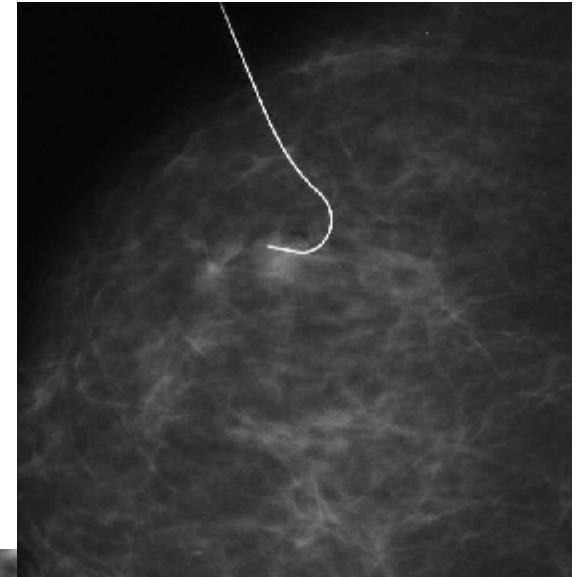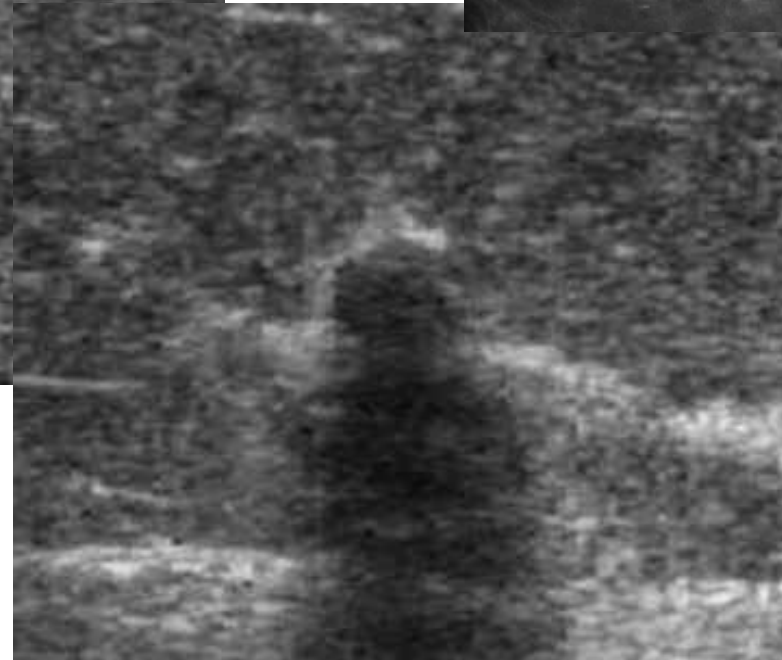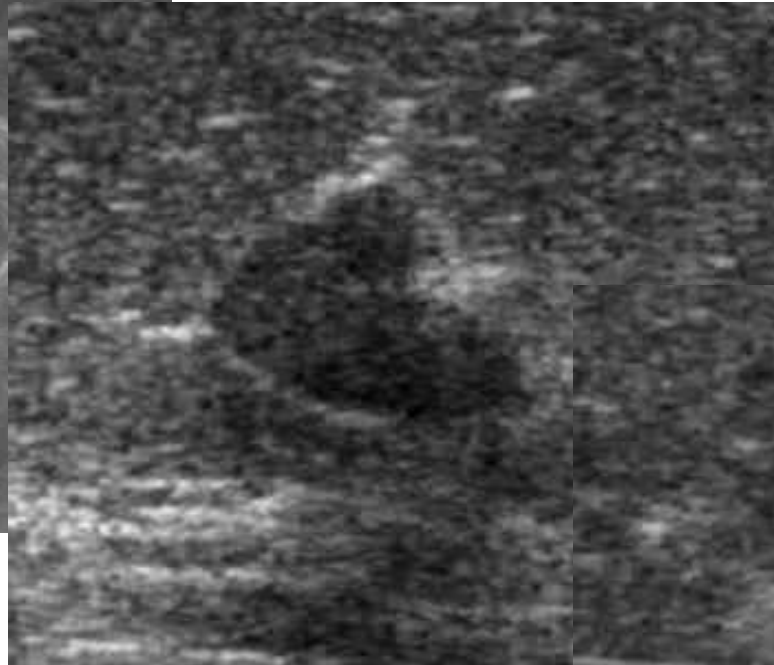
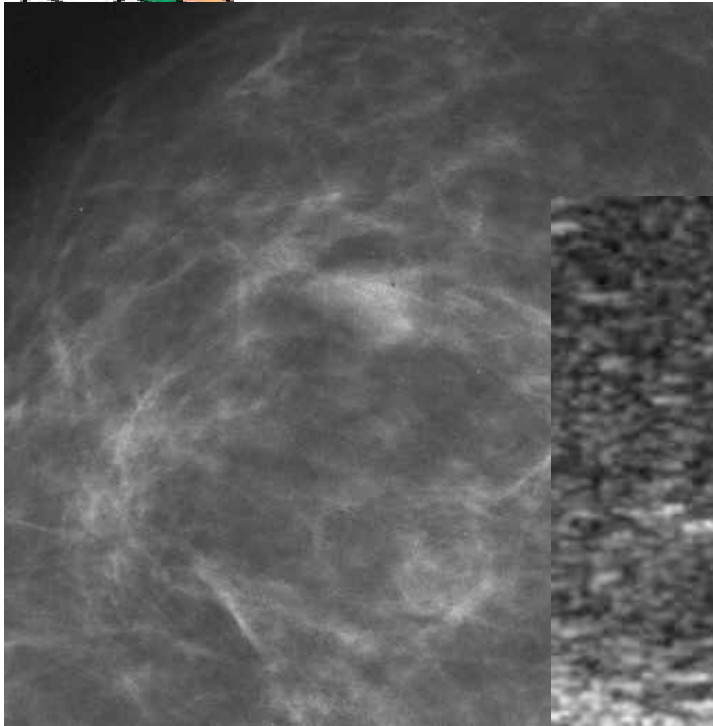


74 ANI, ASIMPTOMATICĂ



DIAGNOSTIC ?

74 ANI, ASIMPTOMATICĂ

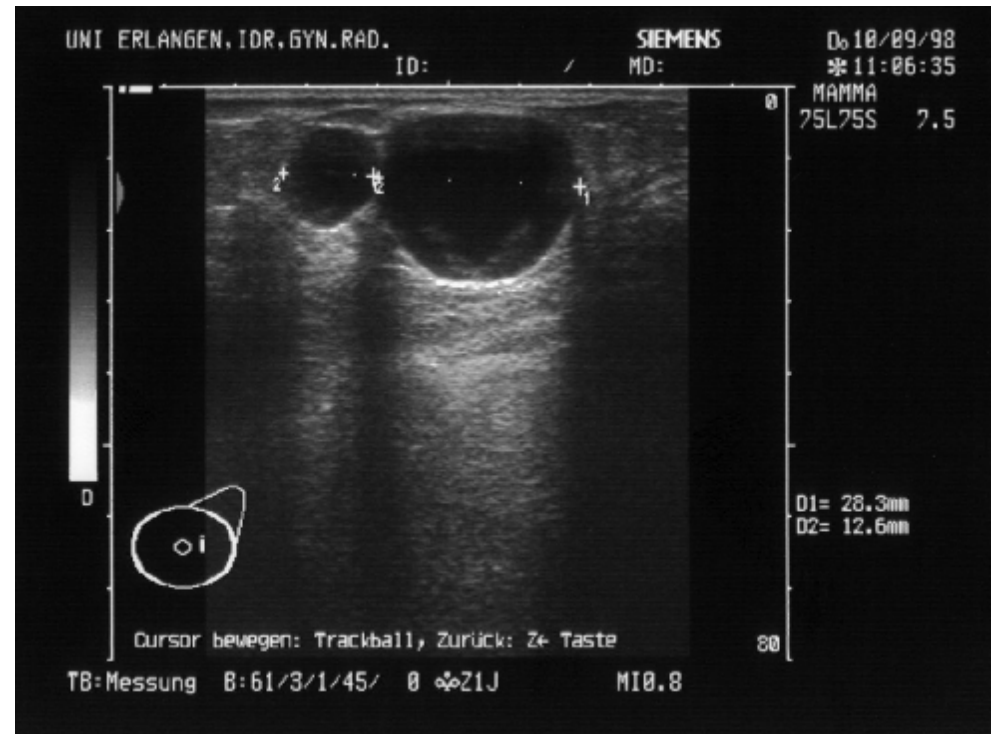
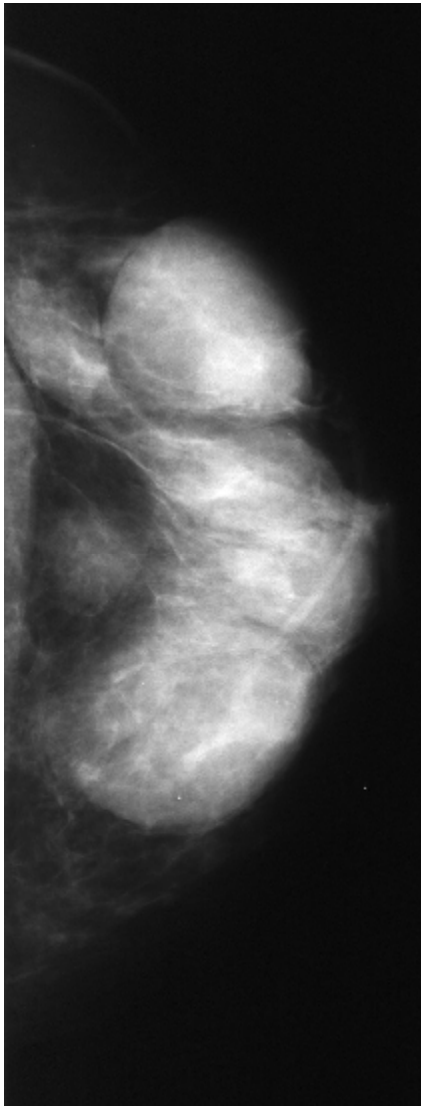


DIAGNOSTIC ?

COD 1/5, HISTOPATOLOGIC - FIBROADENOM: COD 1/2



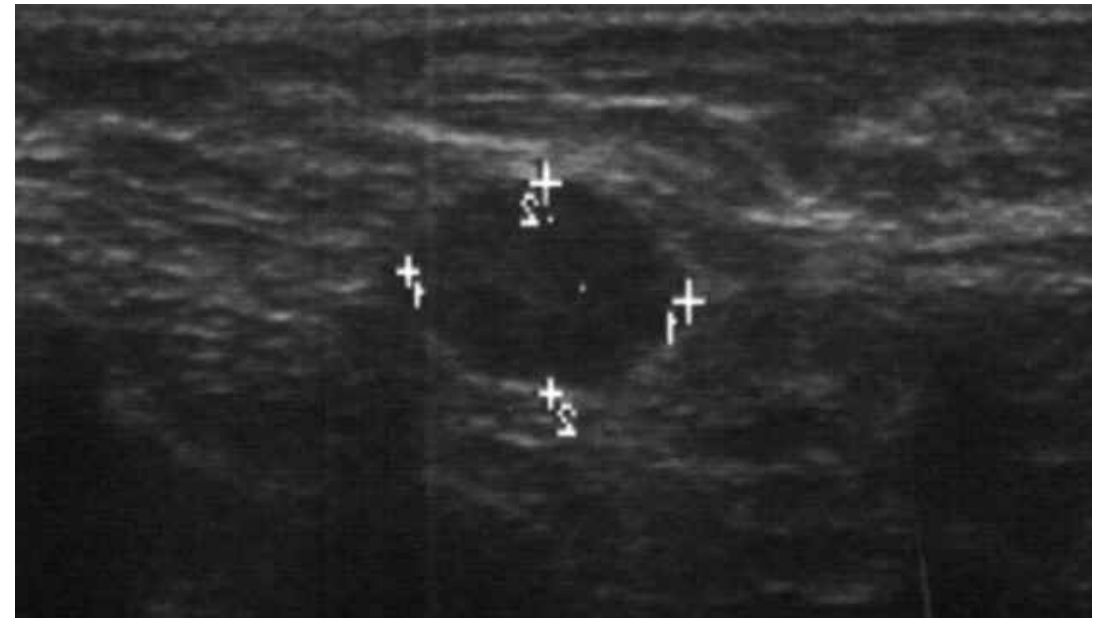
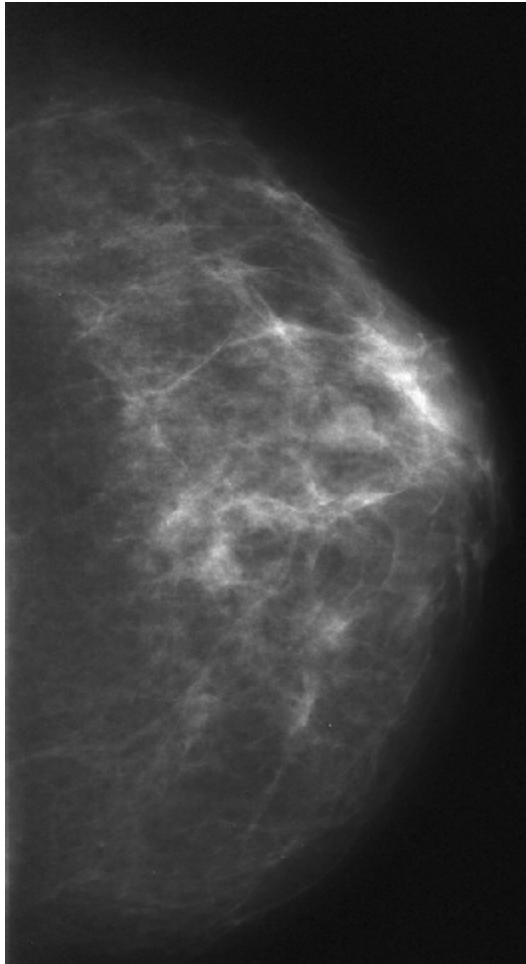
44 ANI, TUMORI PALPABILE, DUREROASE



DIAGNOSTIC ? CHISTE, COD 4/2



48 ANI, TUMORI PALPABILE AXILAR

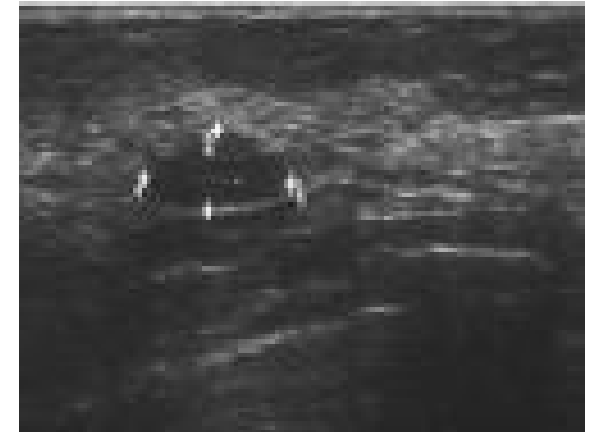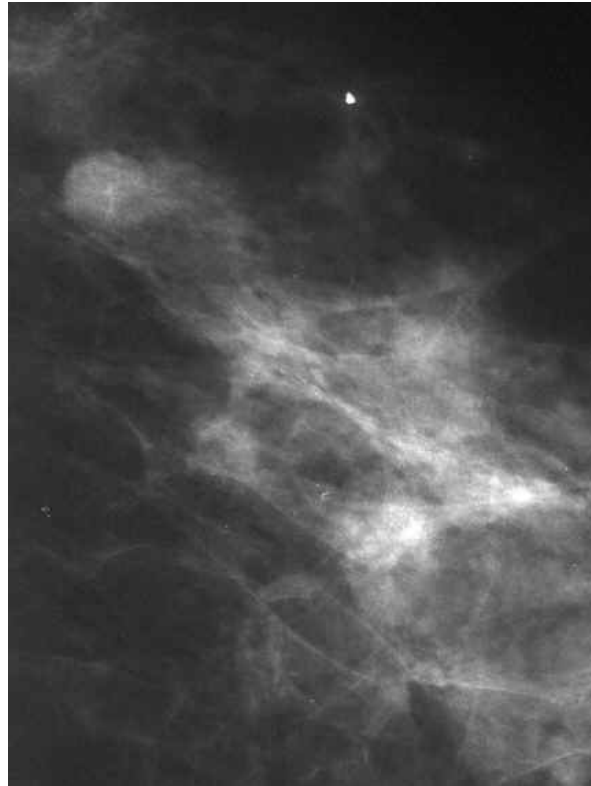
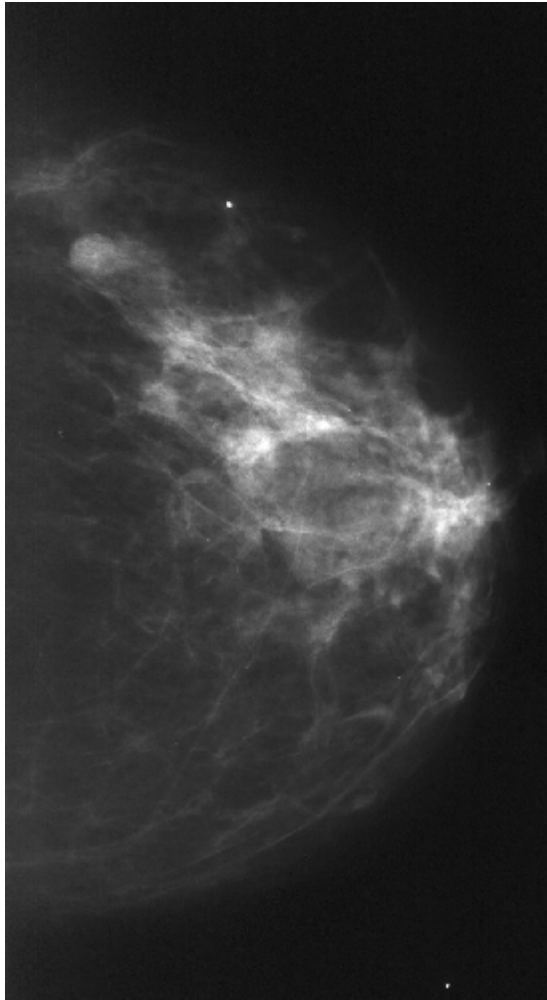


DIAGNOSTIC ?

CHISTE, COD 2/2; EXAMEN HISTOPATOLOGIC GGL - META DE LA CARCINOM TUBULAR ENDOMETRIAL



78 ANI , CARCINOM OVARIAN OP. ÎN URMĂ CU 12 ANI

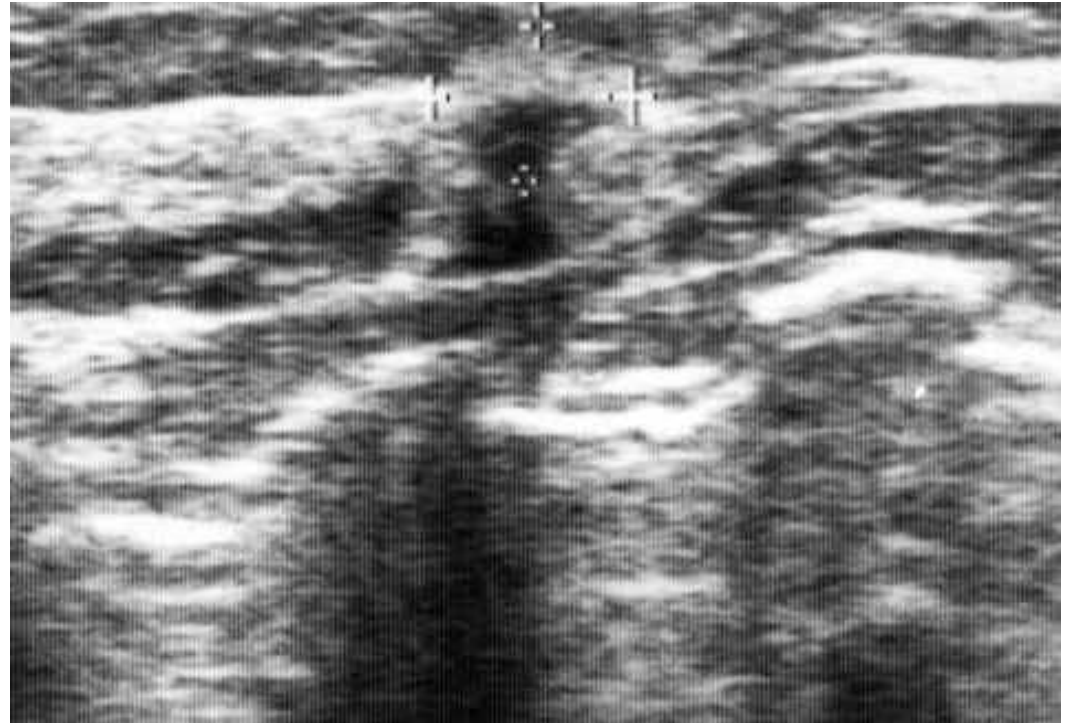
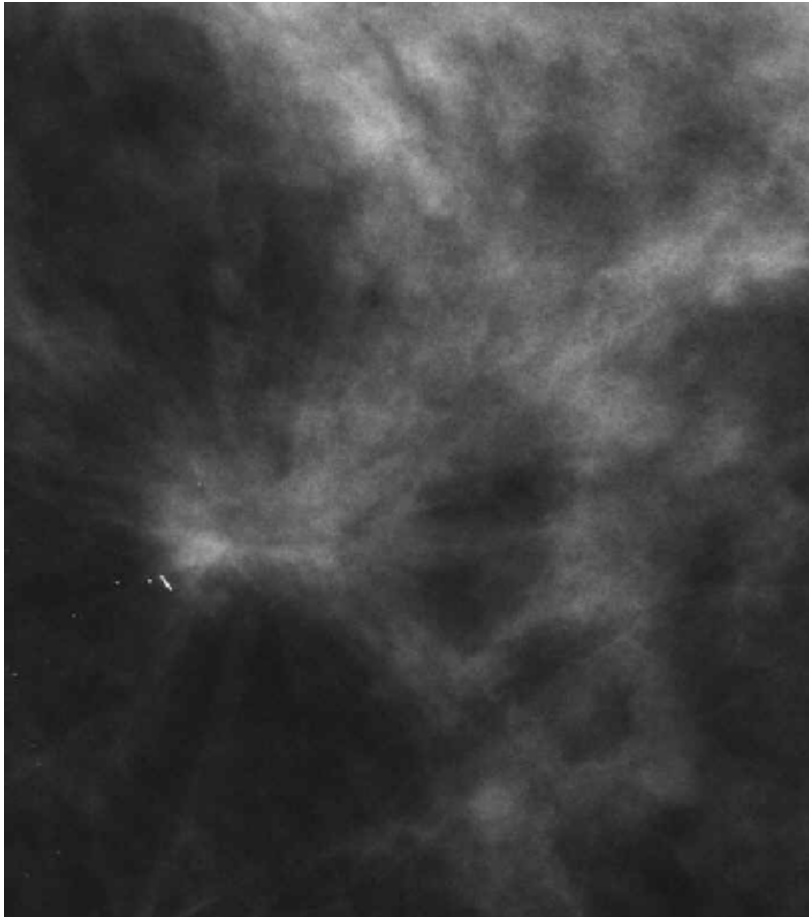


DIAGNOSTIC ?

CHIST, COD 2/2



71 ANI, CARCINOM OP. ÎN URMĂ CU 8 ANI

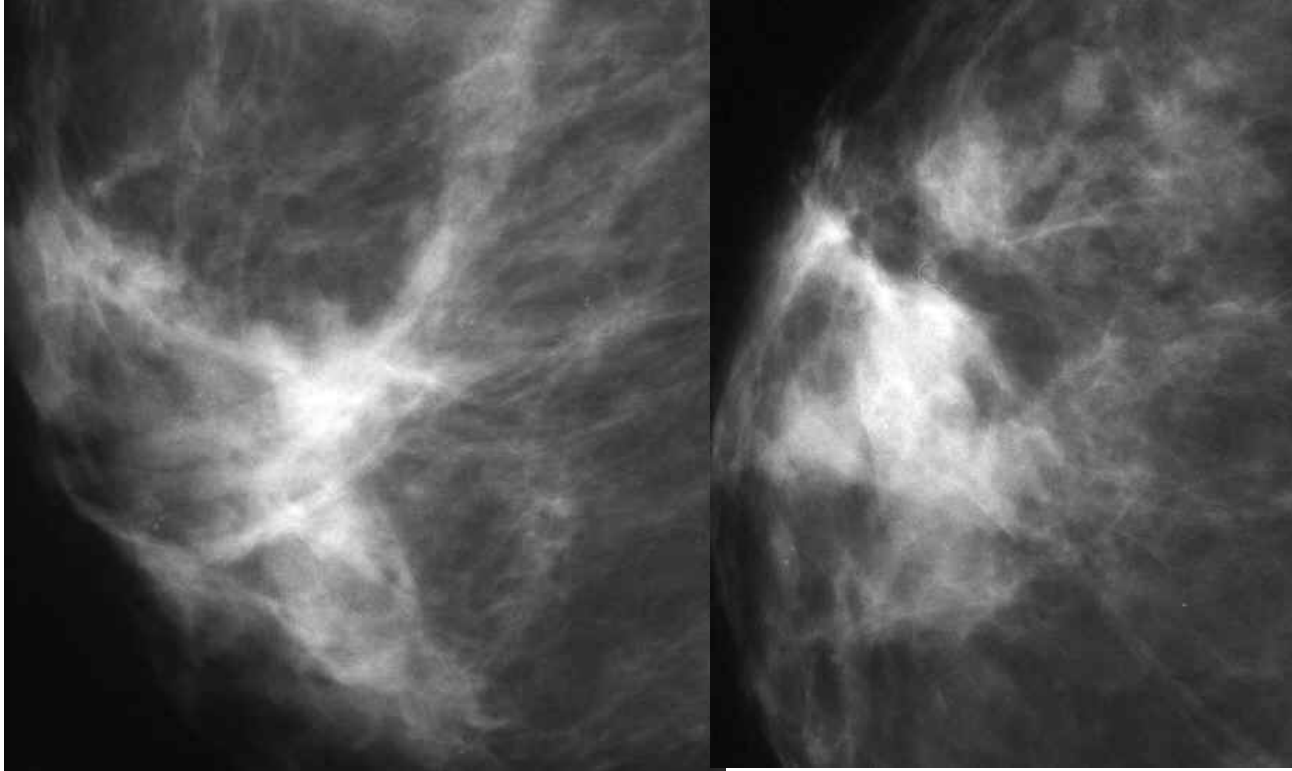


DIAGNOSTIC ?

CICATRICE, COD 2/2



63 ANI, CARCINOM OP. ÎN URMĂ CU 2 ANI

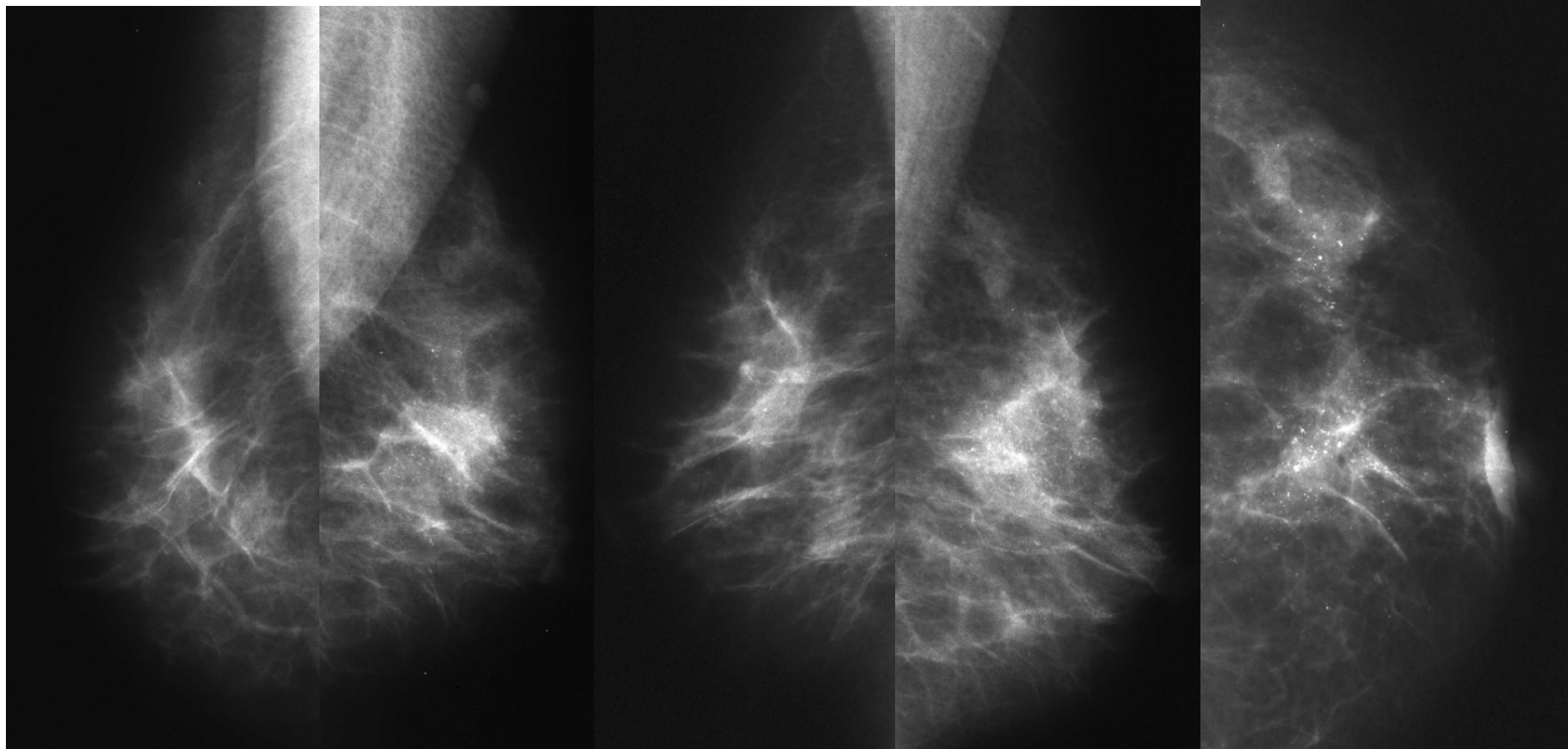


DIAGNOSTIC ?

CICATRICE, COD 2/2



65 ANI , MASTODINIE



DIAGNOSTIC ?

MASTOZĂ FIBROCHISTICĂ, COD 2/2